S. James Zinreich, MD • David W. Kennedy, MD • Arthur E. Rosenbaum, MD • Bob W. Gayler, MD • Ashok J. Kumar, MD • Heinz Stammberger, MD

Paranasal Sinuses: CT Imaging Requirements for Endoscopic Surgery[1]

Recent advances in the understanding of mucociliary activity and the pathophysiology of the nasal cavity and paranasal sinuses have revolutionized the surgical management of chronic and/or recurrent sinusitis. Meticulous radiographic delineation of the small structures in this region, coupled with endoscopic evaluation, provides detailed preoperative information regarding morphology and pathology. This information has led to more focused endoscopic surgical procedures, which have dramatically reduced patient morbidity. As a consequence, there is now worldwide interest among otolaryngologists in the radiologic definition of paranasal regional anatomy. For effective interactions between radiologist and otolaryngologist, the former must be prepared to render interpretations that address these "microanatomic" locales. This communication is directed at familiarizing the radiologist with these observations and concepts, considering both normal and disturbed anatomy with their attendant pathophysiologic and therapeutic implications.

Index terms: Endoscopy • Paranasal sinuses, CT, 238.1211 • Paranasal sinuses, diseases, 238.25 • Paranasal sinuses, surgery, 238.1299. • Sinusitis, 238.25

Radiology 1987; 163:769-775

THE clinical diagnosis of sinusitis is usually based on symptoms indicating maxillary or frontal sinus involvement. Clinically, maxillary and frontal sinusitis is seen more frequently than ethmoid sinusitis. Standard paranasal sinus radiographs can readily demonstrate such maxillary or frontal sinus disease but incompletely delineate ethmoid sinusitis (1-4). It is not surprising, therefore, that clinical as well as radiologic recognition of the interrelationships between ethmoid disease and disease of the adjoining maxillary and frontal sinuses has been largely unexplored.

The importance of the communications between the anterior ethmoid sinus and the frontal and maxillary sinuses (via the infundibulum, middle meatus, and frontal recess) in the pathogenesis and treatment of sinusitis was recognized earlier by otolaryngologists (5-12). Proctor in 1966 reported that "the ethmoid sinuses are usually the key to any problem involving infectious sinusitis. Infection begins there and persistent infection there is usually the reason for failure of therapy directed at any of the other paranasal sinuses" (8, 9). Subsequently, Messerklinger (10, 12) and Drettner (7) demonstrated that obstruction of the ostia is the usual precursor to sinusitis. They showed that apposition of abutting mucociliary surfaces within the paranasal sinuses forms an anatomic substrate for disrupting sinonasal drainage. The resulting retention of secretions leads to inflammation and infection. Messerklinger also showed that the infundibulum and the middle meatus are the channels most frequently affected by anatomic variations, which narrow them and juxtapose their mucosal surfaces, facilitating infection.

The development of new endoscopic instruments and associated techniques has fueled a new surgical approach for treating chronic sinusitis (10-15). This surgery is aimed at restoring normal physiology by reestablishing normal mucociliary drainage and ventilation of the sinuses. The surgery is primarily directed to removal of localized disease obstructing the ethmoid pathways. Furthermore, there is evidence that resolution of mucosal disease in the frontal and maxillary sinuses follows the restoration of normal mucociliary clearance and ventilation (10, 12, 14, 15).

Unfortunately, the convoluted anatomic framework of the ethmoid cells precludes the direct, noninvasive endoscopic evaluation of deeper

Table 1
Technique for CT of Paranasal Sinuses

Imaging Parameter	Imaging Plane	
	Coronal	Axial
Patient position	Prone	Supine
Gantry angulation	Perpendicular to IOML	IOML
Extent of study	From anterior frontal sinus to posterior sphenoid sinus	From hard palate through frontal sinus
Section thickness (mm)	4	4
Table incrementation (mm)	3	3
kVp	125	125
mAs	450	450
Scan time (sec)	5	5

Note.—Imaging was performed with use of the Siemens Somatom DR3 unit with version E software. IOML = infraorbital meatal line.

[1] From the Neuroradiology Division of the Russell H. Morgan Department of Radiology and Radiological Sciences (S.J.Z., A.E.R., B.W.G., A.J.K.) and the Department of Otolaryngology/Head and Neck Surgery (D.W.K.), Johns Hopkins Hospital, 600 N. Wolfe St., Baltimore, MD 21205; and the University ENT Clinic, Graz, Austria (H.S.). Received May 27, 1986; revision requested July 15; final revision received January 29, 1987; accepted February 6. **Address reprint requests to** S.J.Z.

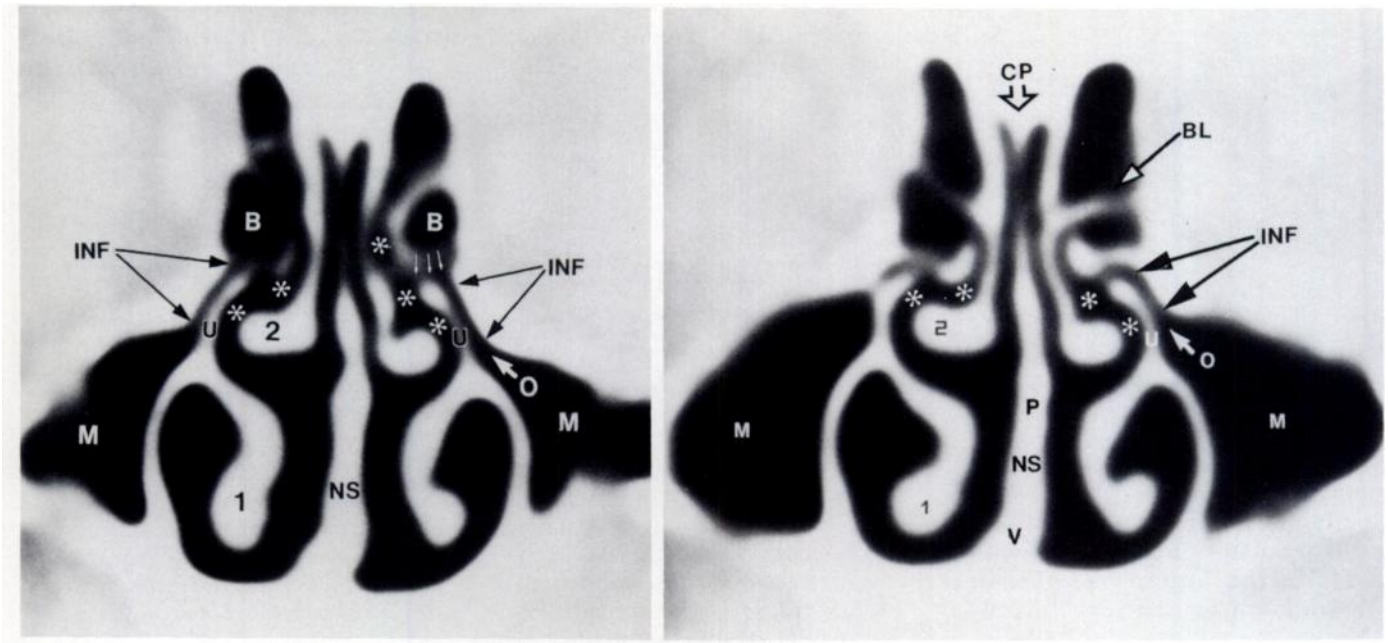

a. b.

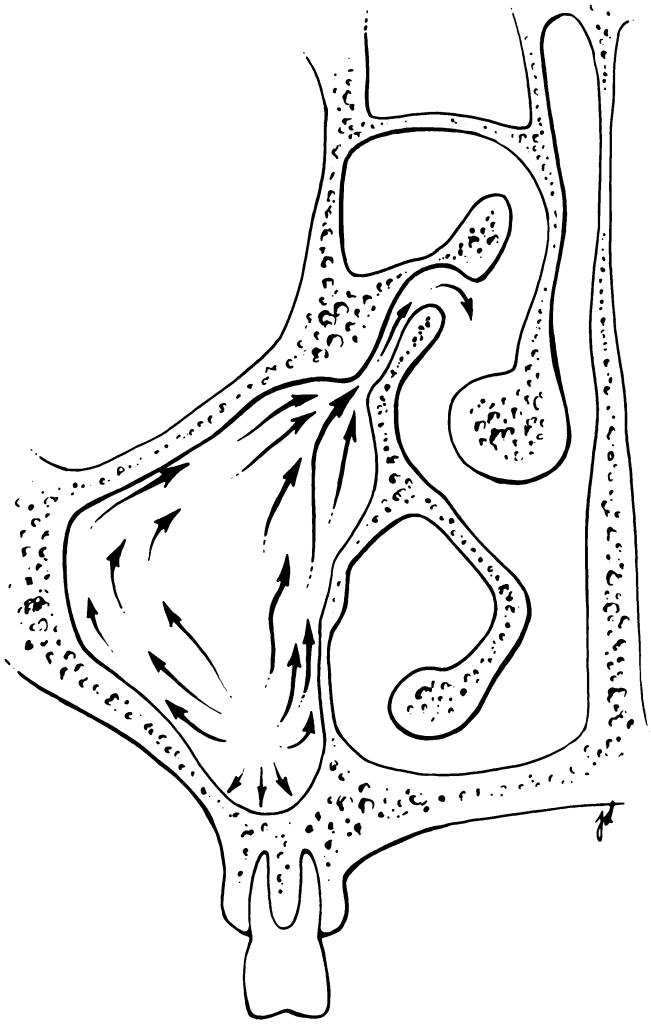

c.

Figure 1. Normal anatomy of ostiomeatal unit as seen on CT. **(a)** The infundibulum *(INF)* is delimited inferiorly by the maxillary sinus ostium *(O)*, medially by the uncinate process *(U)*, superiorly by the ethmoidal bulla *(B)*, and laterally by the inferomedial orbit. The air space surrounding the ethmoidal bulla inferoposteriorly is the hiatus semilunaris (small arrows). **(b)** The middle turbinate *(2)* has dual attachments: a high vertical one to the cribriform plate *(CP)* and a horizontal one to the lamina papyracea, the basal lamella *(BL)*. The air-containing space between the uncinate process *(U)* and the middle turbinate is the middle meatus (*). *NS* = nasal septum, *P* = perpendicular plate, *V* = vomer, *M* = maxillary sinus, *1* = inferior turbinate. **(c)** Mucociliary clearance from the maxillary sinus. The mucus film is propagated from the antral floor up along the walls of the sinus toward the main maxillary sinus ostium, through the infundibulum into the middle meatus (ostiomeatal unit).

ostiomeatal, posterior ethmoid, and sphenoid sinus disease. In such circumstances computed tomography (CT) proves indispensable for identifying the magnitude of disease. Moreover, in cases in which endoscopic surgery is likely to be helpful, CT should be used to guide the endoscopist to the site of disease to avoid complications.

In recurrent sinusitis when acute exacerbations supervene, CT should be delayed until medical treatment has controlled these acute manifestations (13). The diagnostic evaluation for surgery aimed at restoring normal sinus function thus becomes a combination of systematic nasal endoscopy and CT (13). The collaborative role between radiologist and otolaryngologist is reviewed in this communication.

TECHNIQUE

CT examination of the maxillofacial region was performed in patients with both chronic and recurrent acute sinusitis. All examinations were performed with a Siemens (Iselin, N.J.) Somatom DR-3 scanner equipped with version E software.

The coronal plane is the plane closest to the view of the endoscopist; it is also the imaging plane that best displays the ostiomeatal unit. Thus, it was the preferred plane for direct scanning. Each patient was positioned prone with the head hyperextended on the scanner bed. The

scanning parameters are outlined in Table 1. For optimal visualization of the ostiomeatal channels, imaging should be centered on the paranasal sinuses (on the Siemens Somatom DR 3 scanner we used a zoom of 4 or 5). Scanner computation algorithms were selected to favor the demonstration of soft tissue. Window widths were usually at 2,000, and the window was centered to −200. Scanner "raw" data were transiently saved so that high-resolution bone-enhancing reconstructions could be applied when bone erosion was either visualized or suspected.

When patients were unable to assume the prone position, axial scans from the palate through the frontal sinus were obtained and indirect coronal reconstructions generated from them. For special attention to the anterior ethmoid region, coronal indirect reconstructions were performed to complement the initial scanning plane. Even in patients with extensive metallic dental fillings, the direct coronal plane proved superior to the indirect reconstructions, and therefore the coronal plane remains the plane of choice even in this instance.

ANATOMY

Ethmoidal Labyrinth

As seen on the coronal view (Fig. 1a, 1b), air cells collectively form the ethmoidal labyrinth. They appear as a near-vertically oriented, thinly septated bony honeycomb lined by mucosa. These vertically situated air cells are narrower anteriorly and wider posteriorly. The boundaries of this labyrinthine structure are the lamina papyracea laterally, the orbital plate of the frontal bone superiorly, the perpendicular plate medially, and the middle turbinate inferiorly (16–18).

Ostiomeatal Unit

Maxillary sinus ostium and infundibulum.—The maxillary sinus ostium and the infundibulum serve as the predominant channel linking the maxillary sinus with the nasal cavity (Fig. 1). They are best visualized in the coronal plane. The infundibulum is bounded laterally by the inferomedial orbit, superiorly by the hiatus semilunaris and ethmoidal bulla, medially by the uncinate process, and inferiorly by the maxillary sinus as the sinus funnels into it (9, 12). Less frequently, an accessory orifice of the maxillary sinuses is encountered. The accessory orifice most frequently opens into the anterior fontanel of the nasal cavity and is best seen on modified axial views, assuming a midposition between "true" axial and coronal planes. The infundibulum represents the superomedial extension of the ostium. The posterior extent of the uncinate process and the relative position of the ostium determine whether the ostium may be visualized on endoscopy.

Hiatus semilunaris.—This complex space gains its name from its arched appearance in the sagittal plane (Figs. 1a, 2a). The hiatus semilunaris is bounded superiorly by the ethmoidal bulla, laterally by the medial bony orbit, inferiorly by the uncinate process, and medially by the middle meatus. The hiatus semilunaris is the final segment for drainage from the maxillary sinus, being preceded by the maxillary ostium and infundibulum. The hiatus semilunaris is best identified on parasagittal sections and runs obliquely in a posteroinferior direction between the uncinate process and the ethmoidal bulla (Fig. 2a). A posterosuperior extension of the hiatus semilunaris (hiatus semilunaris superioris) passes between the ethmoidal bulla and basal lamella and communicates with the sinus lateralis, affording drainage for this space (Fig. 2a).

Middle turbinate.—The middle turbinate lies inferomedial to the anterior ethmoid air cells (Figs. 1a, 1b, 2a). Its most consistent bony attachments are vertically to the cribriform plate superiorly, and to the lamina papyracea laterally via a bony strut termed the basal (ground) lamella (Figs. 1b, 2b). The basal lamella is oriented from anteromedially to posterolaterally to become situated behind the ethmoidal bulla. The compartment between the posterior wall of the ethmoidal bulla and the basal lamella is the sinus lateralis (Fig. 2a, 2b). Quite often the body of the middle turbinate contains an air-filled cavity, the concha bullosa, which communicates variably with the superior medial meatus, the frontal recess, or the sinus lateralis (Fig. 3b).

Ethmoidal bulla.—The ethmoidal bulla usually consists of an air cell of variable size and shape. It is bordered inferomedially by the infundibulum (Fig. 1a) and hiatus semilunaris (Fig. 3c), laterally by the lamina papyracea, and superoposteriorly by the sinus lateralis (Fig. 1a, 1b). It communicates with the nasal cavity via an ostium, the site of which appears to be variable. According to Zuckerkandl (11) the ostium is most often posterior, but according to Messerklinger (12) a superoanterior opening is more frequent. We have also noted it medially.

Frontal recess.—The frontal recess (Figs. 1a, 2a, 2b) affords mucociliary drainage of the frontal sinus. Drainage may occur directly into the middle meatus medial to the uncinate process, into the ethmoidal infundibulum more laterally, or more posteriorly above the ethmoidal bulla. This communication between the frontal sinus and the nasal cavity is not strictly a duct but an internal aperture of hourglass configuration positioned between the sinus and the anterior middle meatus.

Nasolacrimal Duct

The nasolacrimal duct is a straight-coursing tube that extends upward from the lacrimal fossa to a site adjacent to the attachment of the inferior turbinate. In the coronal view (not illustrated) the duct is nearly superoinferiorly oriented, with its inferior portion lying about 3°–5° medial to its superior portion. In the sagittal view its posterior incline may be larger, varying from 5° to 30°.

Sphenoidal sinus, sphenoid ostium, and sphenoethmoidal recess.—This continuum is best evaluated on either axial or sagittal (Fig. 2c) scans. The ostium is located at the anterosuperior portion of the sphenoid sinus (Fig. 2c). The sphenoidal ostium and the posterior ethmoidal air cells drain into the sphenoethmoidal recess (Fig. 2c, 2d).

PATHOPHYSIOLOGY

Much of our present understanding of the mucociliary clearance of the paranasal sinuses is a result of the work performed by Hilding, Messerklinger, and Proctor (5–12, 19, 20). The physiologic roles of the nasal passages are humidification, warming, and removal of particulate matter from inspired air. By far the largest part of inhaled large particulate matter is deposited onto the mucociliary blanket, transferred from the nasal passage through the nasopharynx, and swallowed (16). The mucus blanket is transported by ciliary action along formal pathways. Within the sinuses the mucus layer is advanced by cilia along defined patterns toward the primary ostium (Fig. 1c, 2d).

In the frontal sinus (5), mucociliary clearance proceeds along the septal wall to the roof of the sinus, then laterally along the roof and medially along the floor to reach the ostium. Messerklinger (10, 20) also identified some backflow into the sinus as a re-

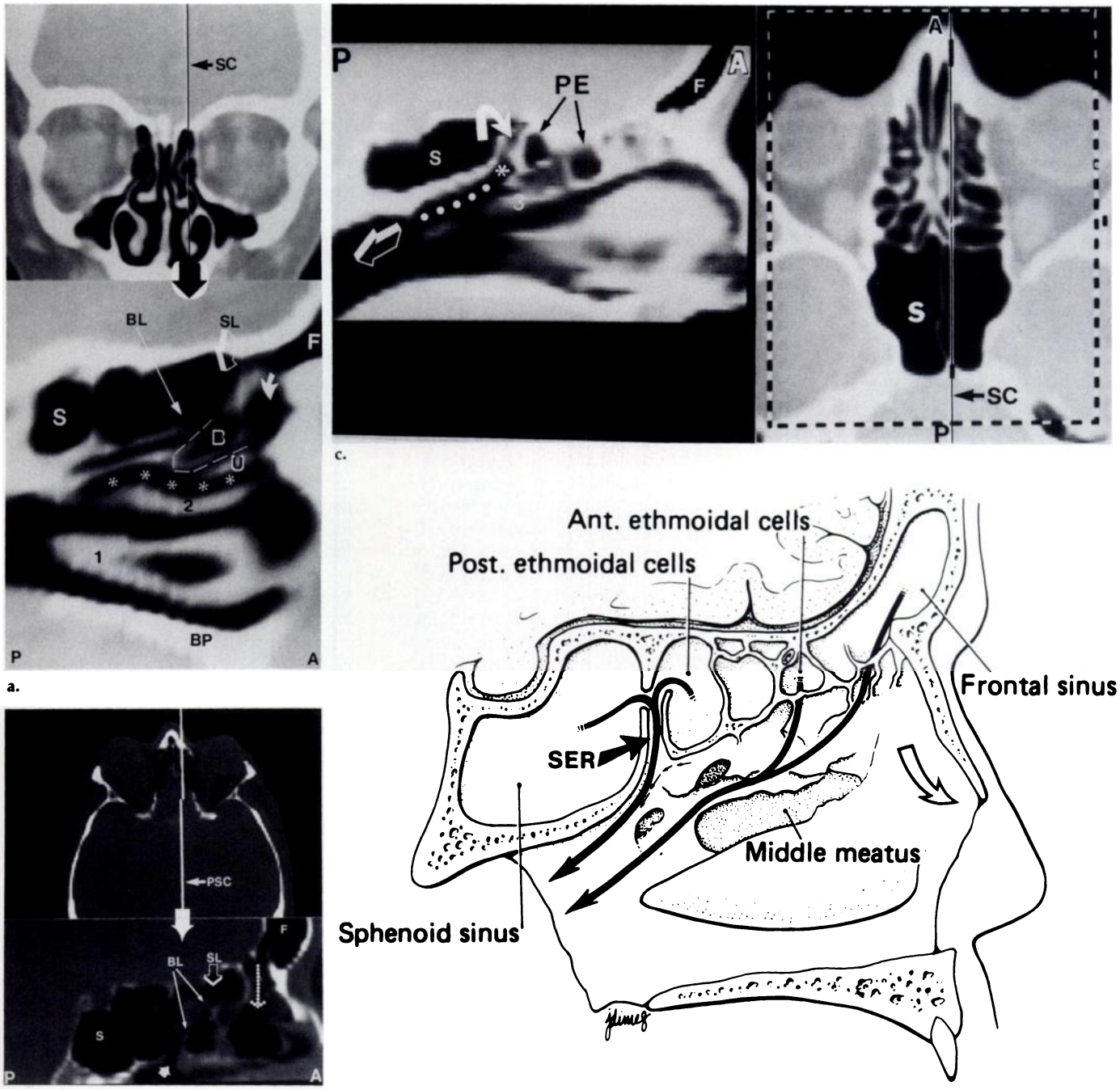

Figure 2. Normal CT anatomy of nasal cavity and paranasal sinuses in the sagittal plane. *A* = anterior, *P* = posterior. **(a)** Sagittal reconstructed image through the middle of the ethmoidal bulla reveals the arcuate passageway of the hiatus semilunaris (dashed line). The hiatus semilunaris courses around the outer anteroinferoposterior border of the ethmoidal bulla *(B)*. Posterosuperiorly, the sinus lateralis *(SL)* drains into the hiatus semilunaris; the sinus lateralis is delimited posteriorly by the basal lamella *(BL)*. * = middle meatus, *F* = frontal sinus, *S* = sphenoid sinus, *U* = uncinate process, *1* = inferior turbinate, *BP* = bony palate, *2* = middle turbinate, *SC* = sagittal cursor. **(b)** Another patient. A slightly oblique parasagittal reconstruction (computer artifact disrupts cursor line, *PSC*) samples the middle of the ethmoid sinus to reveal the basal lamella *(BL)* and the air-filled space just anterior to it, the sinus lateralis (*SL*, open arrow). Solid arrows indicate posterior middle meatus; dotted arrow indicates frontal recess. *F* = frontal sinus, *S* = sphenoid sinus. **(c)** Paramidline sagittal reconstruction (*SC* on reference image) through sphenoid sinus ostium (curved arrow) shows the communication between the sphenoethmoidal recess (*) and the superior meatus (dotted line) and their drainage into the nasopharynx (curved arrow). *PE* = posterior ethmoid cells, *F* = frontal sinus, *3* = superior turbinate, *S* = sphenoid sinus. **(d)** Diagram of lateral nasal wall demonstrating mucociliary flow in the nasal cavity toward the nasopharynx. Mucociliary clearance from the frontal sinus, anterior ethmoid sinus, and maxillary sinus occurs through the middle meatus and is then easily directed toward the nasopharynx. Mucociliary clearance from the sphenoid sinus and posterior ethmoid sinus takes place through the sphenoethmoid recess *(SER)*, to the superior meatus (fine arrows), to the nasopharynx. Mucosal flow anterior to the middle meatus is forward (open arrow).

sult of recirculation in the frontal recess, which suggests a potential mechanism for the introduction of infection. In the maxillary sinus, mucociliary movement originates from the floor of the sinus and radiates along the walls of the sinus superiorly to reach the ostium. When nasoantral windows have been created the

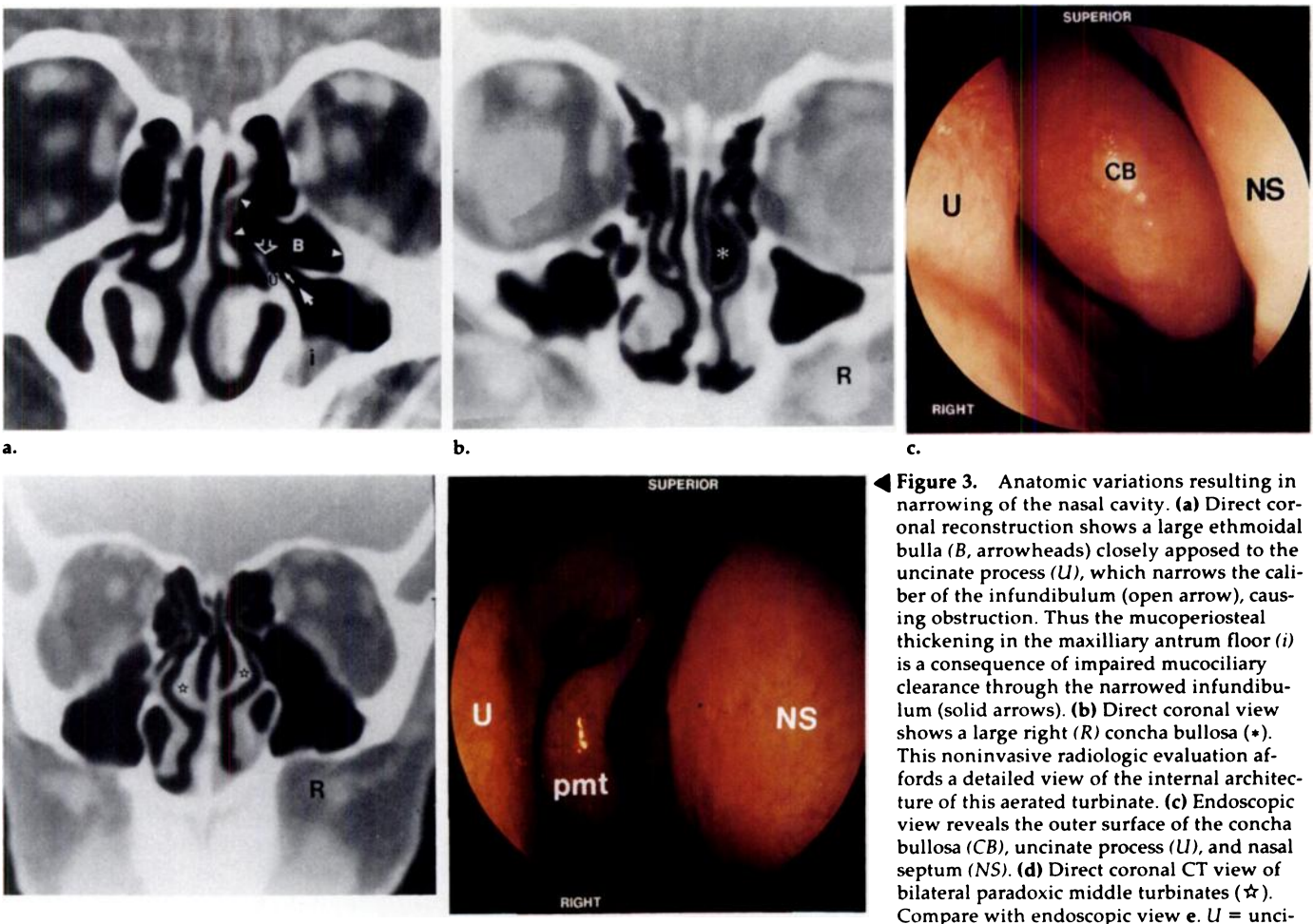

a. b. c. d. e.

Figure 3. Anatomic variations resulting in narrowing of the nasal cavity. **(a)** Direct coronal reconstruction shows a large ethmoidal bulla *(B,* arrowheads) closely apposed to the uncinate process *(U),* which narrows the caliber of the infundibulum (open arrow), causing obstruction. Thus the mucoperiosteal thickening in the maxilliary antrum floor *(i)* is a consequence of impaired mucociliary clearance through the narrowed infundibulum (solid arrows). **(b)** Direct coronal view shows a large right *(R)* concha bullosa (*). This noninvasive radiologic evaluation affords a detailed view of the internal architecture of this aerated turbinate. **(c)** Endoscopic view reveals the outer surface of the concha bullosa *(CB),* uncinate process *(U),* and nasal septum *(NS).* **(d)** Direct coronal CT view of bilateral paradoxic middle turbinates (☆). Compare with endoscopic view **e**. *U* = uncinate process, *NS* = nasal septum, *pmt* = paradoxic middle turbinate.

mucociliary movement maintains its upward movement toward the sinus ostium despite the more inferior nasoantral opening (12, 17) (Fig. 4a, 4b).

Mucociliary clearance and ventilation are dependent on unobstructed flow through the intricate and narrow passages of the ostiomeatal complex. However, in the presence of minor swelling, two mucosal layers may become apposed, leading to stenosis and obstruction, which in turn reduce aeration and predispose to the accumulation of secretions in the secondarily affected major sinus (maxillary, frontal), making the particular sinus prone to infection (5–15, 19, 20). Ostiomeatal passages already narrowed by anatomic variations, trauma, or tumor are prone to inflammation resulting in obstruction.

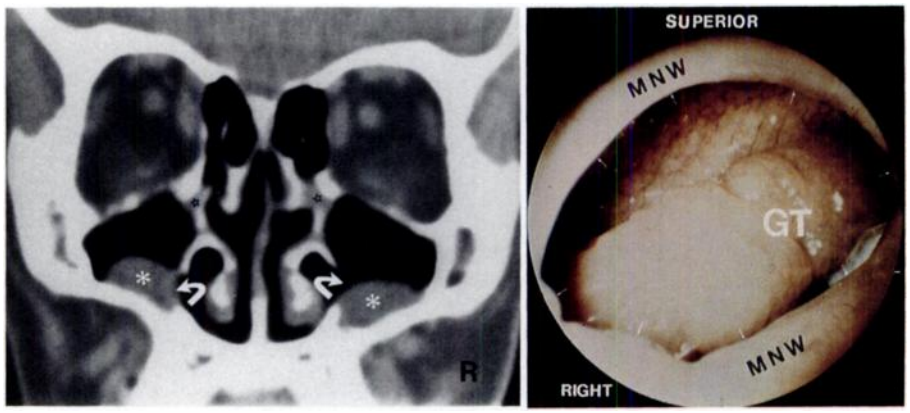

a. b.

Figure 4. Maxillary inflammatory changes persisting despite bilateral nasal antrostomies (nasoantral windows). **(a)** Coronal CT scan discloses that antrostomies (arrows) are patent bilaterally; however, mucoperiosteal inflammation remains along the floor of the maxillary sinuses (*). This is not an incidental finding, since inflammatory mucosa occludes each infundibulum (☆). *R* = right. **(b)** Endoscopist's view from the nasal cavity through the patent nasal antrostomy (arrows) in the medial nasal wall *(MNW)* shows granulation tissue *(GT)* as the specific inflammatory reaction along the antral floor.

EVALUATION OF ABNORMALITY

Nasal Endoscopy

Routine anterior rhinoscopy performed with use of a headlight and nasal speculum allows only limited inspection of the anterior nasal cavity, whereas nasal endoscopy enables detailed visualization, including visualization of the crucial region of the middle meatus. Nasal endoscopy can be performed in the office setting at the time of initial consultation. Areas of inflammation or pathologic drainage are readily identified. In patients with a nasoantral window (inferior meatotomy), the telescope may also be introduced into the maxillary sinus and the entire sinus inspected without discomfort (Fig. 4b).

Within the middle meatus, anatomic abnormalities such as paradoxical curvature of the middle turbinate (Fig. 3e), expansion of the middle turbinate by a large concha bullosa

(Fig. 3c), or a medially rotated uncinate process are easily recognized. The presence of local middle meatal inflammation, granulation, polypoid formation, or sinus discharge can also be identified (Fig. 5b). Limitations of nasal endoscopy include inability to discern the extent of disease within the ethmoidal sinus, difficulty in identifying disease in a constricted middle meatus, and the presence of hidden air spaces such as the ethmoidal bulla, posterior ethmoid sinus, and sphenoid sinus.

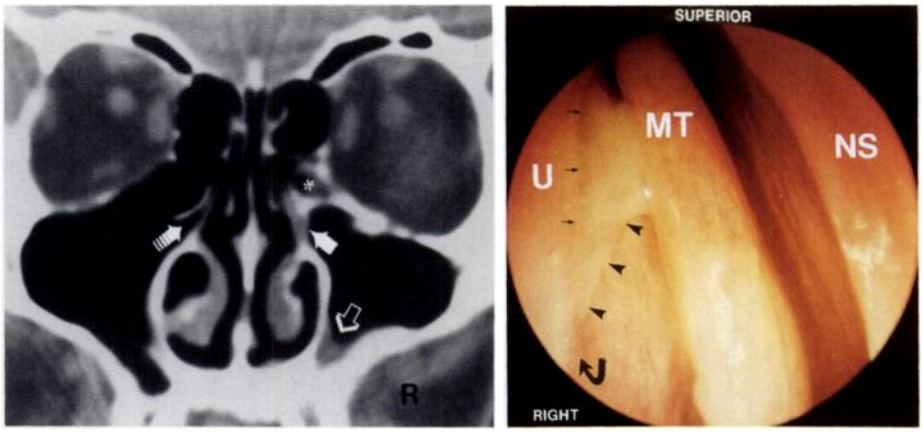

a. b.

Figure 5. Inflammatory disease within the ostiomeatal channels with secondary effects in the maxillary sinus. **(a)** Coronal view reveals a soft-tissue mass occluding the right *(R)* infundibulum (solid arrow). Mucoperiosteal reaction (soft-tissue density) is present along the right antral floor (open arrow) and the right ethmoid bulla (*). The contralateral infundibulum is free of disease (dashed arrow). **(b)** Endoscopy performed after the patient was treated with decongestants revealed a scarred and closed inferior infundibulum (curved arrow) with mucus (arrowheads) bridging the occluded hiatus semilunaris (fine arrows) and the middle turbinate *(MT)*. *U* = uncinate process, *NS* = nasal septum.

CT Evaluation

The CT examination of patients with chronic or recurrent acute sinusitis is performed to help identify underlying causes after a full course of antibiotic therapy has been administered and the acute exacerbation controlled.

Coronal CT sections are obtained of the maxillofacial area, and the following structures are identified and evaluated systematically: frontal sinus, frontal recess, uncinate process, infundibulum, maxillary sinus and ostium, ethmoid bulla, sinus lateralis, middle meatus, posterior ethmoid sinus cells, sphenoethmoid recess, and the sphenoid sinus. Particular attention is focused on the middle meatus and the sphenoethmoid recess. The middle meatus is a narrow passage that receives mucus clearance from the frontal sinus, anterior ethmoid sinus (including all cells anterior to the basal lamella), and the maxillary sinus (Figs. 1a, 1b, 2a, 2d). The sphenoethmoid recess and superior meatus receive and clear mucus from the posterior ethmoid sinus and the sphenoid sinus (Fig. 2c, 2d). Thus, each sinus is evaluated for the extent of mucoperiosteal thickening (inflammation), and then patency of its communication with either the middle meatus or the superior meatus (Figs. 4a, 5a).

Anatomic variations, trauma, and tumor represent structural variations that predispose to narrowing of the ostiomeatal complex and the sinus drainage channels. The anatomic variations encountered in the anterior ethmoid sinus include a large ethmoidal bulla (Fig. 3a), a large concha bullosa (Figs. 3b, 3c), a paradoxic middle turbinate (Figs. 3d, 3e) (the convexity is lateral instead of medial), an uncinate process bulla, and nasal septal deviation. The major consequence of these anatomic variations is narrowing of the middle meatus. Two other anatomic variations—Halle cells (ethmoid cells extending along the roof of the maxillary sinus) and lateral deviation of the uncinate process—can severely narrow the infundibulum.

Furthermore, reconstructed sagittal CT scans may be used to plan the approach to endoscopy and therapeutic instrumentation. CT can show the exact distance and angle from the piriform aperture to the frontal recess, the basal lamella, or the anterior rim of the sphenoid sinus (Fig. 6).

OBSERVATIONS

In the first 100 CT examinations of patients with chronic sinusitis (patients who had and had not undergone previous surgery), the region most commonly involved with inflammatory disease was the middle meatus (72%). Associated maxillary sinus mucoperiosteal disease was found in 65% (Fig. 5). Frontal sinus mucoperiosteal disease was found in 39 patients (39%), in all of whom the frontal recess was also occluded by an inflammatory mass extending from the middle meatus. Seven patients had ostiomeatal disease without maxillary sinus disease. This might be explained on the basis of incomplete occlusion of the infundibulum. The sphenoid sinus was affected in 29% and the posterior ethmoid sinus in 40%. In 7% no inflammatory pathosis was found (Table 2).

Our initial experience confirms the beliefs of Messerklinger and Proctor that ethmoid sinus disease influences the development of disease in other sinuses. Anterior ethmoid sinus infection was found in each patient with the major complaint of frontal or maxillary sinusitis. Moreover, middle meatal disease was found to extend to and occlude the frontal recess in each patient with frontal sinusitis and to extend to and occlude the infundibulum in all cases of maxillary mucoperiosteal disease (Fig. 4).

DISCUSSION

Although recognized earlier by otolaryngologists (5–12), the role of ethmoid sinus disease in the development of disease in other sinuses is often forgotten, perhaps because of poor visualization of the ethmoid sinus on standard radiographs. In 1966 Proctor stated that the ethmoid sinuses are the key to infectious sinusitis (8). When sinus ostia are obstructed, mucociliary clearance becomes ineffective and sinusitis ensues (5–15). Clinically the need to evaluate the ostiomeatal complex in patients with chronic and recurrent sinusitis further highlights the need for a systematic radiologic evaluation of this area with a technique other than plain radiography.

The standard radiographic views (Caldwell, Waters, base, and lateral) allow quick, noninvasive evaluation of the nasal cavity and paranasal sinuses. With these views it is possible to evaluate the maxillary, frontal, sphenoid, and posterior ethmoid sinuses, as well as the lower third of the nasal cavity. However, the standard views are insufficient for adequate evaluation of the anterior ethmoidal air cells, upper two-thirds of the nasal cavity, and the frontal recess (2, 3). Because of problems with ideal positioning and overlapping structures, many studies are suboptimal

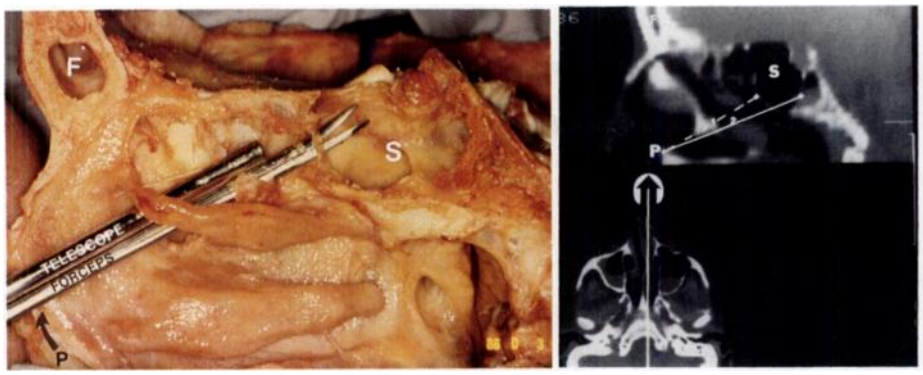

a. b.

Figure 6. Autopsy and CT sagittal correlations for guiding the endoscopist during function-restoring endoscopic surgery. **(a)** Endoscopic viewing (telescope) and operative (forceps) instruments placed along the access route to the sphenoid sinus. **(b)** Because of normal septation of the sphenoid sinus, the disease encountered clinically lies in the posterior part of the sinus *(2)* rather than along the usual endoscopic path (*1*, dashed line). Reconstructed sagittal CT scans contribute to a safer and more accurate therapeutic procedure by providing the endoscopist with information concerning the angulation and safe distance of penetration of the instruments, with the piriform aperture *(P)* used as a point of reference. *S* = sphenoid sinus, *F* = frontal sinus.

Table 2
Distribution of Paranasal Sinus Disease in 100 Patients with Chronic Sinusitis

Involved Sinus	% of Patients
Anterior ethmoid	72
Maxillary	65
Frontal	34
Posterior ethmoid	40
Sphenoid	29
None	7

and preclude accurate evaluation of the extent of soft-tissue masses and bone destruction (2, 3).

Thin-section pluridirectional tomography was found to be more accurate than plain radiography in demonstrating the extent of soft-tissue pathosis and bone erosion (3). Even though the structures of the upper two-thirds of the nasal cavity are better visualized with tomography than with plain radiography, small structures are obscured by phantom artifacts. Phantom artifacts also tend to mask underlying small soft-tissue disease involving the ostiomeatal unit, thus precluding their recognition.

CT, with its excellent capability for displaying bone and soft tissues, is the current diagnostic modality of choice for evaluating the ostiomeatal complex (4). The technique described, which uses 20–25 CT scans, accurately depicts the presence and extent of paranasal sinus disease. Furthermore, CT is effective in demonstrating predisposing causes of chronic sinusitis (anatomic variations, trauma, tumor) and provides precise guidance for therapeutic endoscopic instrumentation.

In addition to the evaluation of ostiomeatal disease in the patient that has not yet been operated on, CT is of particular value in the assessment of patients with persistent complaints after sinus surgery. Proctor has pointed out that the most common cause of failure in therapy directed at the major sinuses has been persistent ethmoid disease (8, 9), and disease in this area frequently persists after traditional therapeutic approaches to sinus disease have been carried out. In these patients CT is mandatory because inflammatory changes in the middle meatus are poorly seen on plain radiographs. In this setting CT can establish the extent of surgery, help the clinician determine if full patency of the narrow passages has been reestablished, and reveal the secondary consequences of ostiomeatal inflammation.

The development of functional endoscopic sinus surgery and its ability to alleviate disease in the ostiomeatal unit allows treatment to be undertaken with minimal injury to adjacent normal structures (10–15). When the cause of recurrent or chronic inflammation can be readily identified on endoscopy, CT provides additional information regarding regional anatomic detail, drainage impairment, and the magnitude of disease. CT and endoscopy are therefore complementary in the diagnosis and treatment of nasal cavity and paranasal sinus disease. Accurate knowledge of the extent of disease and the normal drainage pathways has proved crucial for the successful cure of chronic sinusitis (13, 14). Recognition of the importance of the ostiomeatal complex and the reversibility of secondary mucosal disease has led to the concept of functional endoscopic sinus surgery (13) in which the primary operation is performed within the ethmoid sinus–middle meatal complex. ■

Acknowledgments: We thank Cynthia Quinn, R.T., Linda Widerman, R.T., and Steven Frankenfeld, R.T., for technical assistance, Judith O. Beard for editorial assistance, and Betty Brandt for preparing the manuscript.

References

1. Weiss AR, Lapayowker MS. Inflammatory disease of the paranasal sinuses. Contemp Diagn Radiol 1978; 17:1–5.
2. Carter LB, Bankoff MS, Fisk JD. Computed tomographic detection of sinusitus responsible for intracranial and extracranial infections. Radiology 1983; 147:739–742.
3. Som PM. The paranasal sinuses head and neck imaging. In: Bergeron RT, Osborn AG, Som PM, eds. Head and neck imaging excluding the brain. St. Louis: Mosby, 1984; 5–143.
4. Beck TL, Rosenbaum AE, Miller NR. Orbital computed tomography: technical aspects. Int Ophthalmol Clin 1981; 22:7–43.
5. Hilding AC. The physiology of drainage of nasal mucus. Ann Otolaryngol 1944; 53:35.
6. Hilding AC. Physiologic basis of nasal operations. Calif Med 1950; 72:103–107.
7. Drettner B. The obstructed maxillary ostium. Rhinology 1967; 51:100–104.
8. Proctor DF. The nose, paranasal sinuses and pharynx. In: Walters W, ed. Lewis-Walters practice of surgery. Vol. 4. Hagerstown, Md.: Prior, 1966; 1–37.
9. Proctor D. Airborne disease and the upper respiratory tract. Bacteriol Rev 1966; 30:498–513.
10. Messerklinger W. On the drainage of the normal frontal sinus of man. Acta Otolaryngol 1967; 673:176–181.
11. Zuckerkandel E. Normale und pathologische Anatomie der Nasenhöhle und ihrer pneumatischen Anhänge. Vol. 1. Vienna: Müller, 1893.
12. Messerklinger W. Endoscopy of the nose. Baltimore: Urban & Schwartzenberg, 1978.
13. Kennedy DW, Zinreich SJ, Rosenbaum AE, Johns ME. Functional endoscopic sinus surgery: theory and diagnostic evaluation. Arch Otolaryngol 1985; 111:576–582.
14. Stammberger H. Endoscopic endonasal surgery—concepts in treatment of recurring rhinosinusitis. I. Anatomic and pathophysiologic considerations. Otolaryngol Head Neck Surg 1986; 94(2):143–146.
15. Stammberger H. Endoscopic endonasal surgery—concepts in treatment of recurring rhinosinusitis. II. Anatomic and pathophysiologic considerations. Otolaryngol Head Neck Surg 1986; 94(2):147–156.
16. Potter GD. Sectional anatomy and tomography of the head. New York: Grune & Stratton, 1971.
17. Boileau-Grant JC. Atlas of anatomy. 5th ed. Baltimore: Williams & Wilkins, 1962.
18. Terrier F, Weber W, Ruffenacht D, Porcellini B. Anatomy of the ethmoid: CT, endoscopic, and macroscopic. AJNR 1985; 5:77–84.
19. Proctor DF. The mucociliary system. In: Proctor DF, Andersen IHP, eds. The nose: upper airway physiology and the atmospheric environment. New York: Elsevier, 1982.
20. Messerklinger W. Über die Drainage der Menschlichen Nasennebenhohlen unter normalen und pathologischen Bedingungen. In: Messerklinger W, ed. Ohrenhelkunde und Laryngo-rhinologie. Vienna: Urban & Schwarzenberg, 1966; 56–66.