OPEN ACCESS

Review Article

Danger points, complications and medico-legal aspects in endoscopic sinus surgery

Abstract

Endoscopic endonasal sinus surgery represents the overall accepted type of surgical treatment for chronic rhinosinusitis. Notwithstanding raised and still evolving quality standards, surgeons performing routine endoscopic interventions are faced with minor complications in 5% and major complications in 0.5–1%.
A comprehensive review on all minor and major complications of endoscopic surgery of the paranasal sinuses and also on the anterior skull base is presented listing the actual scientific literature. The pathogenesis, signs and symptoms of each complication are reviewed and therapeutic regimens are discussed in detail relating to actual publication references. Potential medico-legal aspects are explicated and recent algorithms of avoidance are mentioned taking into account options in surgical training and education.

Keywords: endoscopic sinus surgery, FESS, skull base surgery, complications, review, medico-legal aspects

W. Hosemann[1]
C. Draf[1]

1 Department of Otorhinolaryngology, Head and Neck Surgery University Greifswald, Greifswald, Germany

1 Preface

Endoscopic endonasal sinus surgery makes up a large part of routine operations of an otolaryngologist, being widely used as treatment for chronic rhinosinusitis.
Concrete numbers are rare, however; the following can be used as reference points: it is justifiable to use a value of 5% [1], [2], [3], [4] as the prevalence of chronic sinusitis, bearing in mind quite variable information of different literature sources (1–19%). Although the international count of consultations in this regard is currently declining a little [5], the number of surgeries is increasing. Regarding in-patient treatments in the Federal Republic of Germany in 2010, the diagnosis "chronic sinusitis" was encoded approximately 58,600 times (Federal Health Monitoring http://gbe-bund.de). Another source mentions 45,000 in-patient cases per year (0.05% of all in-patient cases) with 38 000 patients treated via surgery [6]. In Thuringia, 46/100,000 men and 72/100,000 women underwent sinus surgery [7] in 2005. Similar numbers exist for the Netherlands [8]. A rough estimate reveals 0.02% of the population of Great Britain undergoing paranasal sinus surgery during a 10 year timespan; this rate remained constant for years [9]. Very diverse numbers are reported regarding the USA varying between 250,000 to 600,000 endoscopic interventions per year [10], [11], [12], [13], [14], [15], with severe regional differences [16]. There is no doubt that the number of surgeries is increasing; there were reportedly 138,000 interventions in the year 1996 [17], [18]. A majority (257,000 surgeries) are performed today on an out-patient basis [19], [20]; the coding also displays an increasing degree of complexity of surgeries [13].

The present paper deals primarily with danger points, complications and medico-legal aspects in routine endoscopic endonasal sinus surgery. To a lesser extent, it also discusses extended surgeries on the anterior skull base and rhino-neurosurgery with its special technical- and personnel-related requirements. The following explanations supplement, improve and update earlier reports regarding endoscopic surgery of the paranasal sinuses and the anterior skull base [21], [22], [23], [24]. The main emphasis is to review the present literature of endonasal sinus and skull base surgery over the past 15 years. The focal point lies in the causal analysis, the special proximate therapy and the medico-legal estimate of risks and complications. Basal surgery techniques and their results cannot be addressed in detail, even though the current surgery models and their concepts focus on avoiding risks. This applies for general recommendations regarding prevention or adjustment of side effects or malunions. Here numerous current monographic publications should be taken into account [25], [26], [27], [28], [29], [30], [31].
During the past two decades there has been steady continued technical development in routine endonasal surgery for chronic rhinosinusitis (e.g. through the optimization of micro-instruments or the progress in imaging; through the use of navigation systems, shavers or miniaturized or angled drilling systems; through improved screen and video-standard). Additionally there has been continued development in conceptual differentiation (among others improved understanding of pathophysiology; integration of surgical and conservative therapy strategies) [2], [32], [33], [34], [35], [36], [37]. It has, however, not been proven that the most recent development has led to a reduced rate of complications [38],

[39]. Furthermore, endonasal surgery has undergone an enormous expansion of its reach and its indications [40], [41] in specialized centers with continued development of 'simultaneous neuro-rhinosurgery' [21] and 'endoscopic rhino-neurosurgery'. These interventions may result in extracranial complications in up to a third of the cases, which may lead to intensive otorhinolaryngological treatment [42]. For that reason, the aforementioned interventions are herewith included in the widely used term 'rhino-neurosurgery'. The focus of the following explanations, notwithstanding of the former, discusses routine ENT surgery.
The present report cannot and is not intended to develop a normative impression in regard to medical legal issues.

2 Special aspects in endoscopic surgery of the paranasal sinuses

Regarding contemporary endonasal sinus surgery for chronic rhinosinusitis rigorous technical or conceptual standards cannot be defined. This circumstance is based among others on knowledge gaps in the pathology, as well as missing differentiated nosological classification for chronic rhinosinusitis [2]. Due to the individual anatomy of the patient and the often missing correlation of subjective and objective findings surgical treatment cannot be standardized [43]. This results in a broad range of acceptable treatment strategies and surgical concepts. From the patients perspective endonasal surgery for chronic rhinosinusitis can be considered effective [44]. As compared to its "effectiveness" its application regarding formal evidence of standards is far from being beyond critical discussion: with regard to diffuse nasal polyposis surgery is often referred as generally "non-curative" [45]. The particular advantage of an extensive removal in terms of effectiveness and safety is frequently called into question as compared to conservative methods such as a polypectomy or intensive medical therapy [46], [47], [48], [49], [50], [51], [52]. Meticulous removal of hidden polyps in the maxillary sinus in the course of pansinus surgeries often does not achieve better results than mere conventional antrostomy [53]. This lack of "evidence" is also applicable to balloon dilatation [54]. Apart from formal criteria, there is reliable evidence in literature stating that a "thorough" surgery in chronic rhinosinusitis performed by experienced surgeons attains the desired results with a low complication rate and a positive contrast to pharmacotherapy or to reduced surgical interventions [55], [56], [57]. It is known that surgeries in this specific patient population are only acceptable when conservative treatment with a sufficient duration and intensity remains ineffective [58]. Corticosteroids are currently preferred, their specific side effects in systemic administration (including hyperglycemia, gastritis, adrenal suppression, but also e.g. temporary mild neuropsychological changes in about 25% of the cases, elevated intraocular pressure) in view of medico-legal aspects are comparatively seldom considered [59], [60].

A commonly quoted statement by Mosher in 1929 is: "It has been said that the ethmoidal operation is the easiest in surgery ... In practice, however, it has proved to be one of the easiest operations with which to kill a patient" (e.g. [27]). According to literature endonasal endoscopic sinus surgery does neither lead to more nor to less complications than similar procedures using the microscope or procedures without optical aids [61], [62]. The endoscope as optical aid has been established worldwide, although in some institutions surgeries of lesser extent are performed using e.g. a head light [45], [63].
In general, sinus surgery has a relevant risk potential [61], [64]. When surgical errors occur in a rare case, the risk resulting in relevant physical damage is above average [65]. Doubtlessly, many patients with chronic rhinosinusitis are already burdened heavily simply due to their illness [66]. In other cases an unfavorable ratio results, with respect to the listed mistakes: on the one hand there is a possibly moderate subjective stress on the patient through his disease, low risk regarding the natural course of the disease and conservative treatment alternatives. On the other hand the extent of potential damage and personal consequences from a complication prone surgery should be considered. This fact imposes a special medical attention, but generally applies: in case of medico-legal disputes the driving force is the extent and type of damage to the patient, not the complication as such or whether an error has occurred [67].

3 Classification of complications in endonasal sinus surgery

A systemic classification of complications supports the comparative assessment of therapy results and emergency management. According to the European Rhinologic Society (ERS) complications may be classified into two levels of severity [62] (Table 1).
Alternative classifications are more sensitive and allow further subdivisions primarily focusing on the perspective of affected patients. This scale distinguishes between four degrees of severity varying from adverse events (grade A) to death (grade C) [68]:

1. "Adverse events": may resolve spontaneously, easy to handle.
2. Grade A complication ("minor complication"): leads to an additional surgery, without permanent harm.
3. Grade B complication ("major complication"): irreversible damage.
4. Grade C complication ("disastrous complication"): death.

Another source introduces a classification with three categories [39], [69]:
a) "Minor complication": intraoperative controllable without consequences.
b) "Major complication": controllable during surgery or in revision surgery, without permanent harm.
c) "Serious complication": high risk of permanent harm.

Table 1: Complications of endonasal sinus surgery (based on: [62]).

Localization/overall type of injury	"minor complication"	"major complication"
Orbital complicaton	• Orbital emphysema • Ecchymosis of the eylid	• Orbital hematoma • Reduced visual acuity / blindness • Enophthalmos • Injury of the nasolacrimal duct
Intracranial complication	• Uncomplicated CSF fistula	• CSF leak • (Tension-) pneumocephalus • Encephalocele • Brain abscess • Meningitis • Intracranial (subarachnoid) hemorrhage • Direct injury of brain tissue
Bleeding	• minor bleeding (stopped with nasal packing, no need for blood transfusion)	• Injury of the ant. ethmoidal artery • Injury of the sphenopalatine artery • Injury of internal carotid artery • Bleeding in need of transfusion
other	• Synechiae • Slight exacerbation of pre-existing bronchial asthma • Hyposmia • Local infection (osteitis) • Postoperative MRSA-infection • Atrophic rhinitis • Paraffinoma • Myospherulosis • Temporal irritation of the infraorbital nerve • Hypoesthesia of the lip or teeth	• "Toxic shock syndrome" • Anosmia • Severe exacerbation of a pre-existing bronchial asthma or bronchospasm • Death

There is no classification with a differentiated listing of neurological-, neuro-ophthalmological and vascular damages for the special issues of rhino-neurosurgery. For a comparative evaluation of results, there is currently only an alternative classification of interventions with degrees of increasing complexity [70].

Statistics of complications reflect these various uncertainties (among others publication bias, heterogenic patient population, heterogenic surgical strategy, heterogenic surgeon population). As a result, the reported frequencies of complications also display a wide spread in recent articles in literature [39], [63], [71], [72], [73], [74], [75], [76]. The necessary rough estimate can be considered correct if one counts on minor complications in approximately 5% of the cases and on larger ones in 0.5 to 1% [14], [48], [62], [63], [68], [69], [72], [77], [78], [79], [80] – knowing well that individual reports from the beginning period of international distribution of this surgery [81] display higher ratios, such as 8% of severe- and 21% of harmless complications. In some statistics, "minor complications" are not even recorded systematically anymore [82].

As mentioned before, the reported complication rate in literature has technically not changed with the introduction of optical aids [61], [62], [68], [69], [83]. There is no evidence for a reduced complication rate with the use of camera- and video systems [74]. In turn, some reports state an increase of dramatic complications if no optical aids are used at all [84]. If data from the "beginning international phase" ("surgical innovation adoption curve" [85]) of endoscopic surgery (such as 1988 to 1998) is excluded, endoscopic surgery displays a comparable safe procedure according to the subsequent comparison of literature [80]. The complication rate has globally decreased slightly during the past few years [14].

The risk of a complication increases under the following circumstances [38], [39], [61], [62], [63], [68], [74], [76], [86], [87], [88], [89], [90], [91], [92]:

- Advanced sinus disease with the need of a more extensive approach.
- Revision surgery.
- Patients with severe comorbidities.
- Patients with anatomical abnormalities respectively missing anatomical landmarks.
- Increased risk of intraoperative bleeding.
- Lack of conception/manual experience of the surgeon.
- Surgical approaches from the right side (by a right handed surgeon).

Reduced exposure in interventions under local anesthesia has not always been observed [91]. This could be explained [62], [93] by the reduced scope of interventions, "warning signals" being received from the patient under local anesthesia or by reduced intraoperative bleeding [62], [93].

Almost every one of the risk indicators mentioned in literature is subject to controverse discussions: The elevated complication rate during larger interventions is partially disputed [39], [94]. The increased risk during revision surgery is being questioned [72], [91], [94], in part initial surgeries are supposed to result in a higher rate of complications [86]. The side preference is also being partially disclaimed [91]. It is possible that putative side preferences are not generally all the same, they may depend on the exact type of complication [95], [96]: for example, general hemorrhages occur more frequently on the right side [39], whereas carotid artery injuries have been observed without any lateral preference [95] or with a left preference [97]. The global relative ratio of complications on the right side is reported with a percentage of 55% to 86% [98], [83]. The disputed question of surgical expertise is discussed below.

It should be noted that there is a larger risk in patients with cardiac stress with forced deficits during anesthesia [39]. Patients with mucoviscidosis, connective tissue diseases, cartagena syndrome, vasculitis, sarcoidosis, Samter's triad or "allergic fungal rhinosinusitis" (AFRS) are also reported to be subject to higher complication risks [76].

In order to minimize the risks, special pre-treatment of the patient is often prescribed: A patient with polyposis, for example, can get a subjective impression of a simplified intervention by preoperative administration of cortisone [99]; it is also possible that the extent of the intervention is reduced. The preoperative therapy with steroids is often supplemented with antibiotic medication [100].

The risk potential is higher in transnasal endoscopic rhino-neurosurgery; altogether this accounts for approximately 10% (–25%) of complications. The reported numbers have to be discussed; these apply to heterogenic interventions and patients.

It can be assumed in each case that the values are below those of traditional craniofacial surgery [101], [102]. The otorhinolaryngologist as partner in a rhino-neurosurgical team is confronted with a significantly wider spectrum of possible errors and risks during surgery. Examples are: intra- or suprasellar hematomas, damages to the chiasma or injuries of the parasellar carotid artery, postoperative endocrine disorders, secondary bleeding of branches of the sphenopalatine artery, postoperative sphenoid sinusitis [101], [103].

4 "Minor" complications

4.1 Damage of the lamina papyracea – orbital emphysema, preseptal bleeding

The most common minor complication of endonasal sinus surgery derives from defined damages of the lamina papyracea [68], [69], [91]. This may occur for instance while performing uncinectomy or maxillary antrostomy [69], [104], preferably on the right side [96]. These injuries are more frequently observed in less experienced surgeons [105].

Maxillary sinus hypoplasia with a prevalence of 4% accounts as predisposition for injuries of the lamina papyracea. In addition patients with a hypoplasia of the ethmoid (10%) are endangered; in the coronal plane the ostium of the maxillary sinus is positioned laterally to the convexity of the medial orbital wall [106]. Congenital or acquired (after trauma or surgery) defects of the medial orbital wall are a potential risk, reported with a frequency of 0.5% [106], [107]. In rare, individual cases natural dehiscence of the lamina papyracea with prolapse of orbital content are being described. The site of dehiscence is always close to the ethmoid bulla and anterior to the basal lamella of the middle turbinate [107].

The incidence of a periorbital injury lies around 2% [72], [108]. It generally results in orbital fat prolapse into the surgical field and leads to small venous bleeding of the orbit ("preseptal bleeding" beneath the skin of the eyelid, (Figure 6a) [109]. If there is neither a functional nor an aesthetic consequence for the patient the injury does not count as statistic complication [75].

An early diagnosis of the injury incurred prevents secondary damages. In case of an uncertainty whether the lamina papyracea is injured intraoperative the pressure test described by Draf and Stankiewicz [110], [111], [112] is a useful aid: repeated careful application of pressure to the outside of the patients eyeball produces corresponding movements of the bulging fat.

A method to prove whether the atypical tissue in the surgical field is prolapsed orbital fat, is to place it into water and see if it swims (fat swims in water, ulterior tissue does not) [76].

This test does not qualify as foresighted diagnostic tool, hence healthy, unidentifiable tissue should not be removed for merely test purpose. In fact the surgeon is supposed to orientate himself by dissecting in a cautious and considerate manner and by using the pressure test or with the help of a colleague if required.

In most cases defined periorbital injuries do not need a specific treatment [68]. Further damages through suction should be prohibited, the use of a shaver is not advisable. The damaged site can be covered with a silicon layer otherwise the surgery can be continued. This layer can be temporarily left in place [113].

Postoperatively the condition of the eye needs to be observed [68]. The patient is not to blow his nose or undergo physical activities [114]. Overall there is no need for an-

tibiotic prophylaxis [115]. In general it is recommended not to cover the patient's eyes during sinus surgery, so that alterations of the pupil or movements of the eye ball in case of an injury of the lamina papyracea or orbital structures are noticed at an early stage [116].
In return, it ought to be considered that in 60% of all patients under general anesthesia the eye lids remain partly open, additionally the quality and quantity of the tear production is reduced. Due to this fact eyes need protection either by ointment or gels [117]. Corneal injuries have an incidence of 44% in patients with unprotected eyes [118]. Statistically, severe damages occur especially in surgeries above 90 minutes [117]. Therefore recommendations to keep the patient's eye open for maximum one hour intraoperatively have to be assessed critically [119]. From another side a sterile Hydrogel (Geliperm®) as eye protection is examined [120].

Orbital emphysema

Postoperative emphysema of the eyelid may occur following nose blowing, sneezing or rather after anesthesia with mask ventilation. In many cases there is either a history of a fracture or a surgical defect in the lamina papyracea. Mostly the emphysema develops in the upper eyelid. Orbital emphysema usually resorbs within a week, therapy measures are conservative [104], [121]. The patient is advised to avoid nose blowing and sneezing. Regarding patients with a history of allergies, antihistamines may be prescribed if necessary [122], antibiotics may be given in order to prevent an orbital or periorbital infection [28]. An ophthalmic exam is recommended, but is not mandatory in every case [104].
A case of progressive emphysema of the entire face and throat due to an atypical injury of the dorsal nasal cavity (during nasal packing) was reported. Healing though was without any complications [123]. In traumatological literature, case studies discuss that a certain valve mechanism with increasing accumulation of air in the soft tissue of the eye lid may lead to increasing deterioration of vision ("tension pneumo-orbit") [124], [125]. A less severe case emerged after heavy sneezing without trauma or surgical procedure, which was treated successfully via needle decompression [126]. Loss of vision or diplopia is rarely associated with orbital emphysema [68], [76]. A fatal course after routine endonasal sinus surgery was reported: the patient suffered of premature visual loss due to periorbital injury with a progressive emphysema. In such cases emergency measures include imaging followed by lateral canthotomy with superior and inferior cantholysis and/or needle decompression. Surgical treatment is complemented by application of cortisone, mannitol and acetazolamide in analogy to intraorbital hematoma [127].

4.2 Uncomplicated bleeding of the mucosa

Bleeding in the surgical area hinders visibility, hence may cause delays, an improper performance of the operation or even surgical complications. In principle, different vascular systems, subject to different hemodynamic systems, are the origin of the bleeding. The mean arterial pressure is essential for arterial bleeding, whilst for venous bleeding it is the pressure in the venous vascular territory. For capillaries the blood flow in the respective vascular bed of the capillary is the determining factor. Generally, the capillary is the substrate of an uncomplicated mucosal bleeding during paranasal sinus surgery. Relevant exogenous influencing factors arise, among others, due to the different anesthesiological procedures and pharmaceuticals, intraoperative stress stimuli as well as subclinical individual or drug-induced differences of the platelet function or rather the local blood coagulation [128], [129], [130], [131].
Particular attention has to be paid preoperatively when taking the patient's history in regard to medications. Not merely patients taking Vitamin K antagonists or platelet aggregation inhibitors (non-steroidal inflammatory drugs) should be taken into account. Certain herbal or alternative medical substances, as for example ginkgo, garlic or ginseng, may also contribute to increase bleeding according to pharmacological literature [132], [133], [134], [135]. 10–20% of patients are known to take such preparations; with the use remaining undisclosed in the majority of cases [136]. However, other sources contradict the clinical relevance of this kind of medication [137].
In principle, endonasal sinus surgery under the influence of ASS is associated with a higher risk of bleeding, even if no reliable data is available for this specific type of surgery [138]. For patients who follow a medical treatment with platelet function inhibitors, due to a cardiac disease – possibly with inserted "drug eluting stents" – there is no specific recommendation. In general, the risk of secondary bleeding in ENT surgery is estimated to be "low" or "moderate" [139]. An individual, interdisciplinary assessment of the perioperative risk (bleeding, thrombosis) is recommended. In general, elective surgical procedures should be postponed [140], [141], [142].
Wormald and Boezaart compiled a scale for the systematic and quantitative analysis of the subjective disturbance value 'intraoperative hemorrhage' [143], [144]. Objectively, the average blood loss varies substantially, in each individual case as being between 50–100 ml [8], [145]. Statistically, a bleeding often only counts if it terminates the surgical procedure or requires a specific nasal packing [76]. About 5% of routine procedures are persistently disturbed by a hemorrhage and in about 1.4% the procedure is cancelled [73], [108]. Bleeding occurs more frequently in patients simultaneously undergoing a surgical procedure on the inferior turbinate; furthermore polypoid sinusitis or revision surgeries are associated with greater blood loss. Diverse experience has been gained with fungous sinusitis and procedures in which a shaver was used [8], [7], [91], [146], [147]. The rate of peri- or postoperative bleeding is supposed to be around 2% altogether; transfusions were required in about 0.2% of cases [72], [91]. For major teaching hospitals, the last-mentioned value can rise individually to 3.7% [96].

A preoperative systemic (e.g. 30 mg/day prednisone for 5 days) and possibly also topical cortisone treatment can lead to a clear and unobstructed operating field with less bleeding which consequently reduces the duration of surgery. Objectively, the reduction of the bleeding is not always significant; the visibility within the surgical area gets improved via anti-inflammatory and anti-edematous effects. A preoperative antibiosis can support this effect [113], [148], [149].
In routine cases, usual measures applied in the OR to reduce blood loss consist in lifting head and the upper part of the patient's body for about 10 to 20 degrees, preventing the body from cooling down and applying local, drug-induced vasoconstriction [128], [130], [131], [134], [146], [149].
Operative manuals provide the according instructions on how to treat defined intranasal vessel injuries (especially anterior and posterior ethmoidal a., sphenopalatine a. with its branches, pharyngeal a., posterior nasal a., nasal septal a.) [12], [76], [150] by mono- or bipolar electrocoagulation. Diffuse mucosal bleeding is counteracted by repeated layers of soaked cotton wool (vasoconstrictors) or by nasal packing [133].

Topical vasoconstriction

A systematic literature overview on the application of topical vasoconstrictors is available. In the international context, cocaine or phenylephrine is therefore still commonly used today [151]. In the Federal Republic of Germany, layers of surgical cottonoids, moistened by epinephrine (usually 1:1,000) are generally applied [30].
The last-named method can lead to complications: e.g., care should be taken with an exposed optic nerve – in casuistic case reports, optic nerve damages leading to blindness after the application of pads moistened by adrenaline have been reported [152].
An accidental injection of the standard solution into the mucous membrane leading to a ten-minute rise of blood pressure (200/130 mmHg) and a moderately increased concentration of troponine in the peripheral blood have become known. Two further accidents have been reported for a combined application of topical and injected epinephrine: a hypertensive crisis and a cardiac shock developed after the insertion of epinephrine (1:1,000) – saturated packing combined with an injection of 1% lidocaine + epinephrine (1:100,000 and 1:200,000, respectively). In another case of proper application, ST segment elevations in the ECG occurred with a moderate rise of troponine. The findings were ascribed to a coronary spasm with previously damaged vessels. The calculated risk of side effects was estimated to be 0.05% and it was concluded that the topical application of epinephrine 1:1,000 can only be deemed to be safe in adults without previous cardiac damage. For children, 0.05% oxymetazoline is used, with a subsequent use of 0.1% oxymetazoline, in justified cases epinephrine 1:2,000 is used [151], [153], [154].

Adrenaline - injection

Targets of an injection into the mucous membrane are the area of the uncinate process, the attachment of the middle turbinate and the supposed sphenopalatine foramen [155], [156].
Subjectively, after such an injection (epinephrine 1:100,000/1:200,000) visibility is reported to be improved. However, this advantage could not be proven clearly, compared to a sodium-chlorine injection or to the application of additional topical decongestion [157], [158], [159]. Nevertheless, a positive effect is said to exist objectively for shorter surgical procedures [159].
The injection of adrenaline into the nasal mucous membranes quickly leads to a noticeable increase in plasma concentration of adrenaline, an effect lasting for a few minutes. This increase is not proportional to the injected amount and the patient's blood pressure and pulse in general should not change much. In other cases, a temporary drop in blood pressure as well as transient arrhythmias have been observed. In several cases following bilateral injection, a distinct cardiovascular response was noticed (1:200,000 epinephrine, 2–3 ml), accompanied by an increase of the average arterial blood pressure. Relevant side effects, however, are extremely rare [153], [158], [159], [160], [161]. For the use of injections, the risk of confusing the diluted solution of adrenaline (for example, 1:200,000) with the highly concentrated solution (1:1,000) has to be generally excluded – according to anecdotal reports (beyond sinus surgery), severe complications have been reported to result in death [162].

Anesthesia – controlled hypotension

Regarding the discussion of optimizing anesthesia protocols, often a controlled hypotension is recommended. The aim is a mean arterial blood pressure of 50–60 mmHg or 80 mmHg for elderly people, and, in general, a reduction of the systolic blood pressure to less than 100 mmHg [98], [149], [163]. At the same time, the mean arterial blood pressure should not be lowered to less than (66% or) 85% of the initial value – as otherwise, there is cause for concern of cognitive deficiencies developing postoperatively. Severe complications including organ ischemia have been observed in 0.02–0.06% of cases. However, there should be no risk for healthy patients (ASA I) in general, if the mentioned rules are respected [155], [163], [164].
The mean arterial blood pressure does not correlate with blood loss. This can be attributed to – amongst other things – the pharmaceuticals used to induce hypotension, as they may eventually exert unfavorable effects on various circulatory parameters of the patient: for example, the administration of sodium-nitroprusside may lead to a deconstriction of peripheral vessels and a reactive tachycardia. A relationship between heart frequency and blood loss has been confirmed. As a consequence, the recommendation is to inhibit each reflex tachycardia and to aim for a pulse rate of 60 per minute. The administra-

tion of beta inhibitors (metoprolol), only led to a short positive effect regarding bleeding. It has to be kept in mind that the applied pharmaceuticals can principally, and eventually in a time-sensitive manner, disturb the platelet function. In accordance with this information, visibility in the surgical area tends to drop as the operation time gets extended [128], [130], [131], [147], [149], [164], [165].

The analysis of influencing factors of anesthesia techniques upon intraoperative bleeding led to contradicting results: a total intravenous anesthesia (TIVA) provides the surgeon with a comparatively better surgical area [147], [166], [167]. According to other sources, this is mostly a subjective effect [168]. Propofol reduces cardiac output and might contribute to a better objective local anemia (eventually via an alpha-adrenergic mediated vasoconstriction). However, if the operation lasts longer than 45 minutes, adverse effects on the platelet function become apparent. If circulatory parameters are kept mostly constant in otherwise healthy patients, then there is no longer any significant difference between propofol (TIVA) and sevoflurane in the intraoperative anemia. There is no unanimous view whether a beta sympatholytic drug (esmolol) is an advantage [144], [169], [170]. The change in anesthesia regarding the balance between hypnosis and analgesia resulted in no substantial benefit [171]. A modification of CO_2 levels in the blood ("CO_2 management" with hypocapnia or hypercapnia) had no effect regarding intraoperative bleeding [172].

Other points

In order to suppress capillary bleeding, the insertion of 3% H_2O_2 by means of saturated cotton wool strips is recommended [156]. In various regimes, tranexamic acid is applied: on the one hand, perioperative administration (3x1 g daily for 5 days, starting 2 hours before the operation) is recommended [173]. On the other hand, tranexamic acid (10 mg/kg) was administered intravenously at the beginning of the sinus surgery, leading to a significant improve of the anemia in the surgical area. Thromboembolic complications could not be observed in the comparatively small cohort study [174]. Irrigating the surgical field with tranexamic acid also had positive effects. In contrast, the application of epsilon aminocaproic acid had no effect [175]. Rinsing the surgical field using 40 degree hot water is also described as helpful [176].

Sinus surgery generally ends with the insertion of nasal packing. Many surgeons think that nasal packing is not mandatory in isolated sinus surgery and after a careful intraoperative hemostasis [177], [178]. When necessary, different kinds of nasal packing is used. Ointment strips are no longer indicated in sinus surgery. The effectiveness of absorbable material for postoperative bleeding prophylaxis remains debatable [179], [180]. The administration of antibiotics in patients with nasal packing depends on duration and underlying disease [133].

In **rhino-neurosurgery**, the otorhinolaryngologist is confronted with less frequent forms of bleeding and with specific therapeutic algorithms. As a prophylaxis, e.g. the intent of the transcribriform approach is to close the anterior and if necessary the posterior ethmoidal arteries at an early stage [102]. In case another arterial bleeding occurs, at first one will try to identify the source of the bleeding tissue substrate by means of optimizing the position of the suction. Afterwards, selected coagulation is performed. In case these measures fail, nasal packing is applied, protecting the surrounding structures [181].

In general, localized injuries of the cavernous sinus can be reliably controlled e.g. by means of insertion of gelatin and thrombin (Floseal®), compressing the substance for two minutes [182]. Alternatively, other hemostyptica (e.g. microfibrillar collagen, polyacetyl-glucosamine fibers) are available.

4.3 Uncomplicated liquorrhea

Anatomy

Bone density increases at the ethmoid roof from anterior to posterior and is also distinctly higher in the area of the posterior wall of the frontal sinus compared to the anterior part of the roof of the ethmoid. Women have a lower bone density than men [183]. As a consequence, the force needed to injure the dorsal or the anterior-lateral ethmoid roof is significantly greater than the force needed to perforate the anterior-medial rhinobasis or rather to remove ethmoidal cells [184]. The weakest part of the anterior skullbase is located in the area of the lateral lamella of the olfactory fossa [185]. Here, the bone is often only 0.05 mm thin [186]. In 50% of cases, there are lateral differences with flattening or tilt to one side [187].

Certain anatomic variants of the rhinobasis favor injuries:

a. Position of the ethmoid roof beneath the roof of the orbit.

b. Asymmetry of the ethmoid roof.

c. Asymmetry regarding the height of the ethmoid roof (in 2/3 the right side is lower than the left).

d. Deep position of the cribriform plate, i.e. high lateral lamella of the olfactory fossa.

e. Larger angle between the skull base and the horizontal line through the sagittal plane.

The incidence of variants a. to c. is approximately 10% [[106], [187], [188], [189], [190]. Preoperative analysis of the CT scan of each patient is part of the surgeon's responsibilities (Table 2).

Localization

In routine surgery cerebrospinal fluid fistulas (CSF fistulas) are mostly the result of misjudging the anatomy, lack of surgical experience or even distorted anatomy e.g. through bleeding [191]. The most common site of erosion is where the middle turbinate passes into the skull base near the ant. ethmoidal artery [76] (Figure 1). In addition the roof of the ethmoid, in case of a relatively high located maxillary sinus, is a predisposed site [192]. According to other authors especially injuries in the central or anterior

Table 2: Checklist for evaluating a CT-scan before performing routine sinus surgery (based on: [106], [135], [189], [197], [363], [450], [592], [594], [704], [705]).

Absolute and relative measures • Width of the anterior und posterior ethmoid • Height of the ethmoid, ratio of the height of the ethmoid to the maxillary sinus and to the orbit ("low skull base")
Uncinate process • Anterior-superior attachment zone (orbit, lateral or medial skull base)
Orbit /Lamina papyracea • Relative position of the orbit and natural ostium of the maxillary sinus • Focal media protrusion of the medial orbital wall (congenital, post-traumatic) • Lateral excavation of the medial wall of the maxillary sinus cavity (partially merging with the medial orbital floor)
Rhinobasis/cribriform plate • Integrity of the ethmoid roof • Supraorbital ethmoidal cells • In the coronal plane: (low-) position of the cribriform plate, height and oblique position of the lateral wall of the olfactory fossa, oblique position of the lateral rhinobasis • In the sagittal plane: angle between the skull base and the horizontal line • Asymmetry (regarding both sides)
Anterior ethmoidal artery • Position to the skull base • Position and size of the medial orbital "protrusion" of the proximal canal of the anterior ethmoidal artery (between the medial rectal m. and the superior oblique m. in the coronal plane of the CT scan)
Anatomy of the approach to the frontal sinus • Agger nasi • Fronto-ethmoidal cells • Frontal bulla • Intersinus septal cell • a.-p. dimension of the caudal frontal sinus, characteristic of the superior nasal spine
Infraorbital ethmoidal cells ("Haller-cells")
Spheno-ethmoidal cells ("Onodi-cells")
Optic canal • position, exposition/prominence ("free course")
Internal carotid artery • thinning/dehiscence of the covering bone • possibly medial protrusion into the sphenoid sinus • possibly projection of the intersphenoidal septum, incomplete septa
Osseous dehiscences/postoperative defects • Lamina papyracea • Lateral wall of the olfactory fossa • Sphenoid sinus • Maxillary sinus (infraorbital n.)

area of the ethmoidal roof, 0.5 to 1 cm behind the surgical opening of the frontal recess, cause CSF leaks. The cribriform plate is rarely damaged primarily [68], [193]. In principle the right side (75–90%) is clearly seen as preferred site by many (but not all) authors [15], [96], [192], [194].

Figure 1: MRI of a patient with a past medical history of "uneventful sinus surgery" 7 years ago. Patient suffers from intercurrent meningitis. Image shows residual findings of a skull base laceration (loco typico) with residual signs of trauma of the neighbouring brain tissue.

Epidemiology

Small and isolated CSF fistulas, which are treated at once successfully, count statistically as "minor complication" [68]. These particular incidents are not rare – in a survey 25% of American otorhinolaryngologists had experienced at least one unexpected CSF fistula intraoperative during the last 5 years [195].

The rate of unexpected dura exposure is reported with a percentage of 0.2% [72]. The number of minimal, temporary and occult leakage of cerebrospinal fluid ceasing spontaneously without clinical relevance, is significantly higher [196]. According to literature the rate of manifest, clinical relevant CSF fistulas, is around 0.2–0.8% [72], [82], [91], [108], [195].

Diagnosis

In most cases cerebrospinal fluid fistulas are clinically apparent – clear liquid flows into the operating field, microanatomical structures are "cleared" unnaturally [76], [197]. In other cases the fistula remained unnoticed at first [68], [198], [199]; some studies state a percentage of 50% [193]. There are even reports of CSF leaks which were diagnosed postoperatively after the patient had developed meningitis [200].

When suspecting a fistula postoperatively a standard rhinological examination is indicated. Every patient that complains of severe headaches needs to be examined thoroughly [76]. Primarily nasal endoscopy is performed. Obvious nasal secretion is tested for beta 2 transferrin or beta-trace protein (prostaglandin H2 Delta isomerase) which is used as marker to diagnose liquorrhea [113], [197]. High resolution computed tomography using thin sections in axial (sphenoid sinus, posterior wall of the frontal sinus) and coronal plane (rhinobasis) may detect bony defects and possibly air bubbles trapped intracranially or even accumulated fluid [113], [201], [202]. Intrathecal fluorescein may be used both to confirm the presence and to attempt to localize CSF leaks and consequently enables surgical management [203], [204].

Further procedures such as radionuclide cisternograms, CT cisternograms and MRI as MR cisternography may be used in exceptional cases [192], [202], [205], [206], [207], [208]. If a meningocele or a meningoencephalocele is suspected an MRI is indicated [113], [205], [206]. Regarding CT scans the quality of the image is crucial, reconstructed coronal planes frequently lead to misinterpretations [199], [209]. Under ideal conditions over 90% of fistulas are detected via high resolution (0.625 mm – 1.25 mm) CT scans in axial plane and multiplanar reconstruction; in 75–80% the estimate of the size is correct [206], [210]. Recently beta trace protein has been preferably used as marker – techniques for isolating this marker are less demanding, hence take less time and are less expensive. Moreover the detection of beta trace protein is more sensitive and specific, a serum control is not needed [201], [211], [212], [213], [214], [215]. It is essential to define valid reference values [216].

In patients with reduced glomerular filtration (false-positive) or patients with meningitis (false-negative) this method cannot be reliably used. PVA – sponge nasal packing is not appropriate for beta2 transferrin testing, due to the protein absorbing material of the nasal packing [217].

In individual cases subclinical fistulas were detected with fluorescein, neither with beta trace nor with beta 2 transferrin [217]. Nevertheless even fluorescein has a limited sensitivity (74%–96%).

False-negative samples may occur, among others, due to a temporary blockage of the fistula through blood clot, edematous mucosa, brain prolapsed or functional insufficient scars of mucosa. The specifity of this test is reported to be 100% [192], [194], [208], [218], [219]. In case of suspecting a false-negative result after injection, nasal packing is to remain for a certain amount of time, which later is checked for fluorescein [194].

Intrathecal fluorescein is not approved (i.e., off label-use); therefore a separate consent form is needed. Several authors advise a fundus examination performed by an ophthalmologist, if necessary a neurological consultation before the injection [219].

There are various regimes to administer fluorescein. The current recommended dilution is 0.1–1 ml of 10% intravenous fluorescein in 10 ml of the patient's own cerebrospinal fluid, which is infused very slowly [113], [192], [204], [220], [221]. Alternatively an increased

amount or concentration of fluorescein [205], [222], [223], weight adapted dose [194], [219], [224] or additional intravenous fluorescein injection to dye recent produced cerebrospinal fluid was introduced.
In general, fluorescein is neurotoxic [205]. Hence a couple of authors suggest injecting 50 mg diphenhydramine and 10 mg dexamethasone intravenously as preliminary [204], [220], [223].
The density of fluorescein is generally higher as in CSF, which is why patients are instructed to lie with the head tilted low for 2 hours after injection. Bed rest is prescribed for 12 hours, the patient is supervised for 24 hours. The yellowish color of the fluorescein is mostly visible with an endoscope, even without light adaptations or filter [205]. In some cases blue light (465–495 nm) and blue-filter (515–555 nm) were installed [204]. Up to 20 hours after injection the dye remains visible in the CSF [224].
Side effects of injecting fluorescein depend on the administered amount, and also occur when more than one substance is injected simultaneously [224]. In under 1% of patients seizures were observed. In general the administration of fluorescein is prohibited in patients with intolerance towards fluorescein as well as in patients with contraindications for lumbar puncture: papilledema, massive intracranial tumor, purulent meningo-encephalitis as well as patients with severe craniocerebral trauma. Seizure disorders which are effectively treated and are without EEG abnormalities do not count as contraindication [194].
In literature an alternative method of topical application of fluorescein without lumbar puncture is introduced. Here 5% of fluorescein solution are administered to suspicious areas in the operative field, expecting to turn yellow or green when binding with cerebrospinal fluid [225].

Surgical management

Iatrogenic cerebrospinal fluid fistulas are usually below 3mm in size, in some cases 2–20 mm [192], [226], [227]. Once a small cerebrospinal fluid leak is confirmed, references recommend conservative treatment to begin with [191], [195], [222], [228]. In a few cases lumbar drainage was solely carried out [215]. However, in case of a persisting leak encountered during routine sinus surgeries or e.g. after rhino-neurosurgical procedures, surgical treatment should be pursued even with small defects. This recommendation is based on observations in traumatology [229] and on experience that only in 1/3 of cases with conservative treatment the scar is rigid enough [228].
Closure of cerebrospinal fluid leaks via endoscopic endonasal approach belongs to the standard repertoire of sinus surgery. There are various approved techniques for repairing defects [205], [226], [230]. The choice of approach does not necessarily influence whether the rhinorrhea ceases when applying the usual diligence [191]. In general, free and pedicle flaps as well as autogenous, allogenous or xenogenous grafts may be used. Autogenous transplants include mucosa, bone, cartilage, fat, fascia or mucoperichondrium. For matter of stabilization gelatin, cellulose or fibrin glue may be prepared in different ways [231].
The initial exposition of the defect is important. The area of the skull base defect needs to be “cleaned” from mucosa remnants and is prepared for the closure. If the leak is not easily identified, it may help to tilt the patient’s head low and to ask the anesthesiologist to perform a valsalva maneuver (PEEP ventilation) [113].
For small defects free autogenous mucus grafts are preferred, the majority of surgeons place the graft in an onlay /overlay technique [191], [195], [222]. When forming a graft one can expect approximately 1/5 shrinkage, the borders of the defect need to overlap at least 4mm even in case of small leaks [222], [232]. The correct orientation and position of the free mucosa graft has to be carefully taken into account – otherwise an intracranial mucocele may develop [233].
Generally, larger defects above 5 mm in diameter are closed in several layers, partly with cartilage or bone [12], [135], [201], [205], [222], [231]. Fibrin glue does not have to be applied in every case [191], [234]. Regarding certain allogenous material (acellular dermis) a prolonged healing and crusting phase has to be expected [235].
Usually routine sinus surgery may be continued after an isolated CSF fistula has occurred [113].
The further anesthetic management needs to consider the circumstance, hence avoid an increase in CSF pressure or pressure of the upper airways (no positive pressure ventilation, deep extubation technique, avoiding coughing and straining). Most surgeons use nasal packing for 3–7 days [113], [191]. In individual cases nasal packing was removed and the patient was discharged on the first day after surgery [195], [203], [222]. As a rule patients are restricted to 1–5 days bed rest [76], [203], [222], and they are released after 3–7 days [195], [203], [222].
Postoperatively the patient has to be closely monitored. Especially the state of consciousness needs to be mediated closely – in case of loss of consciousness a neurosurgical consult has to take place immediately. The patient is supposed to elevate the upper part of his bed (40 to 70 degree); is advised not to lift heavy objects and not to blow his nose for some time. The same applies to coughing, pressing as well as sneezing; possibly antiallergics, laxatives and antacids are prescribed. When sneezing cannot be prevented, the patient is advised to sneeze with open mouth [133], [135], [203], [236], [237], [238].
After the complication-prone procedure, a postoperative CT scan [76], [135] is appropriate. If an instrumental penetration into the intracranial space as part of the genesis of the CSF fistula could not be clearly excluded, a CT scan is performed emergently and mandatory. An MRI 6 months postoperative is not generally recommended [203]. Other authors suggest a fluorescein test 6 weeks after successful defect closure [239].

Complementary treatment – antibiotics

The question whether antibiotic "coverage" in uncomplicated cerebrospinal fluid fistulas is reasonable is source of significant controversy [240]. This also applies for antibiotic prophylaxis regarding active CSF fistulas in traumatology – in case of intracranial air or concurrent intracranial hematoma, antibiotics are strongly recommended [241], [242], [243].
Even if the data in literature is not consistent, administration of an antibiotic as a prophylaxis of an ascending infection is approved by the majority [12], [113], [135], [191], [195], [226].Usually, a cephalosporin is preferred, at least initially in parenteral administration [12], [135]. The duration depends on how long nasal packing remains, generally approx. one week [113], [115], [231], [237], [238], [244].

Complementary treatment – lumbar drains

US surveys regarding unexpected intraoperative cerebrospinal fluid fistulas revealed that in 57% of the surgeons do not order a lumbar drainage, 29% of the surgeons insert a drainage at times and 14% place a lumbar drain in every case [195]. Irrespective of several positive recommendations [231], [236] literature generally points out that a lumbar drainage is not indicated for relevant fistulas [12], [76], [133], [190]. The rate of relapses after the treatment of iatrogenic fistulas with and without drainage does not differ [245]. In particular, drainage is useful in case of increased intracerebral pressure, in the broadest sense also following the closure of large defects or following revisions. Regarding literature the same holds true in the event of clearly increased body weight (BMI) [133], [135], [191], [203], [222], [231].

Prognosis

A meta-analysis showed no significant difference regarding success rate, stating that revision surgery is generally performed in about 90% of all cases for small defects to up to 97% [72], [191], [203], [212], [221], [226], [227], [244]. Recurrence of fistulas is frequently observed in patients with an increased CSF pressure [231]. Certain guidelines should be followed (see above), even flights etc. should be temporarily avoided [76].
Active CSF fistulas may result in meningitis. The cumulated risk for 10 years is indicated with 85%; in different case series it is rated at approx. 20% with an accumulation in the first couple of months [242], [246]. This risk is reliably reduced to 0–1% long-term [221], [247]. In a few cases (0.3 to 0.9%) perioperative complications are reported, such as headaches, seizures, secondary sinusitis, intracranial/subdural haemorrhages or abscesses, vision problems or cavernous sinus thrombosis [191], [221]. Postoperative olfactory dysfunctions, however, were reported with a considerably higher frequency in individual case series (17%) [239]. If an iatrogenic fistula is treated immediately and adequately without any of the above mentioned complications, medico-legal consequences occur merely as an exception [76].
In rhino-neurosurgery, the often extensively reconstructed dura represents a weak spot in the therapeutic concept. Originally, in up to 40% of the cases, postoperative fistulas were observed. This fact led, amongst others, to the introduction of the vascular pedicle intranasal mucoperiosteal flaps and to a consistently multilayered defect closure. The result was a reduction to less than 5% cerebrospinal fluid fistulas (in individual cases to no less than 20%) [70], [102], [182], [223], [248], [249], [250].
A number of special factors determine the particular risk associated with a large dura deficiency: flow rate of cerebrospinal fluid, size of the defect and tissue texture, local dead space, kind and stability of the defect closure as well as patient-related factors, such as recent radiotherapy, diabetes, renal insufficiency and corpulence. In the majority of cases, especially for postoperative persisting heavy flow of cerebrospinal fluid, revision surgery is advisable [182]. Whilst "low-flow" cerebrospinal fluid fistulas can be operated with a delay after extended surgical procedures, i.e. within 7 days, "high-flow" liquor fistulas need to be operated immediately [251].
Regarding inevitably larger defects after extended skull base surgery, local vascular pedicled flaps (nasoseptal flaps [252], flaps from the middle or inferior turbinate [253], [254]) or, in special cases, also local flaps (pericranial flap [255], temporoparietal flap [256], palatal flap [257]) are available [258]. These flaps are superior to free grafts. The dorsal pedicled nasoseptal mucosal flap is most frequently used – postoperatively, however, due to the loss of large area of septal mucosa, un-negligible, long-term modification of the nasal physiology has to be taken into consideration [249].
Mucoceles rarely develop in the sphenoid sinus after reconstruction with the nasoseptal flaps, even if the original mucous membrane has not been cleared out extensively before [259], [260].
The following factors are associated with an increased rate of unsuccessful reconstructions: insufficient localization of the defect, previous surgeries, history of craniotomy or radiotherapy, existing intracranial infection, increase in cranial pressure [191], [208]. The lowest rate of postoperative cerebrospinal fluid fistulas was observed in individual case series with a transcribriform approach, whilst the highest rate was observed in a transplanum-transtuberculum approach. This is caused by a relatively high flow rate of cerebrospinal fluid due to open suprasellar or chiasmatic cisterns. Additionally the dense anatomy prevents the inserted grafts from adapting naturally [102]. Other authors report a less favorable prognosis for large-area defects of the anterior base of the skull [237].
Opinions differ as to whether, even after rhino-neurosurgical operations, there is any indication to provide a lumbar drain after reconstruction of the skull base. In most cases this is decided individually, supporting a drainage in cases of large defects, heavy cerebrospinal fluid flow or increased cerebrospinal fluid pressure, history of radiotherapy or already preoperatively existing liquor-

rhea [182], [248]. An early drainage can help to relieve pressure variations within the area of transplantation during extubation [233]. In about 13% of the cases however, the drainage causes more or less relevant side effects or complications in time, e.g., infection, catheter defects, headaches, excessive drainage with irritation of the graft, pneumocephalus, subdural hematoma and neurological disorders [102], [261].

In a **medico-legal respect**, when cerebrospinal fluid fistulas are found in close proximity to radiologically normative ethmoidal cells, discussions often arise on whether an extended surgery is necessary, i.e., whether a skullbase surgery is justified or not. As a matter of principle, in each individual case, the extent of the surgery has to be justified from a medical perspective and carefully documented and discussed with the patient. In case the whole range of manipulations is used up within the boundaries of what had been discussed with the patient before, it is recommended to include an explanatory statement in the operative report. The findings in preoperative imaging and preoperative endoscopic examination can be different [262], [263]. Hence, preoperative imaging does not determine the scope of the surgical procedure restrictively. The surgeon should in fact remove diseased tissue according to intraoperative findings. In general, localized cerebrospinal fluid fistulas cannot always be avoided, even when the procedure is carried out very carefully [264].

4.4 Synechiae, "missed ostium sequence", unstable middle turbinate with lateralisation

Functional endoscopic sinus surgery is always tailored to the anatomy of the individual and is not strictly standardized. This issue makes it difficult to analyze surgical results as well as define deficiencies in surgical technique – e.g. in a case series dealing with revision surgeries following ethmoidectomy, remnants of the uncinate process were shown in 50% of patients [265]. Postoperatively the individualized anatomy is distorted in the process of healing – intranasal wounds generally undergo secondary healing. The respective prospects of healing are less favorable for certain patient groups e.g. asthmatics or patients suffering from "aspirin triad" [266].

After complete ethmoidectomy, the ethmoid shaft scars and shrinks, which is proven radiologically. In experiments with young animals, midfacial growth had changed postoperatively (see 5.5) [267], [268]. The surgical restructured ostium of the frontal sinus is especially prone to unwanted scarring [77], regardless of a high global success rate of 75–93% in frontal sinus surgery [269]. A scar-induced narrowing of the neo-ostium by at least 30% is normal after type III frontal sinus drainage [270]. For the purpose of prevention, placing mucosal grafts onto the exposed bone in order to avoid a reactive ostitis with secondary thickening of the bone, is recommended [113], [185], [271], [272].

The rate of stenosis or occlusions following fenestration of the maxillary sinus via the middle meatus is distinctly lower than 10%. In principle, the size of an enlarged primary maxillary ostium is not decisive for the condition of the maxillary sinus mucosa; at a diameter of more than 2 mm these ostia are generally function normative [273]. Synechiae represent a more complex problem. Occurring in about 10% of cases, they are frequent, however, in most cases (60–90%) functionally unapparent [72], [73], [94]. Hence, they are often not mentioned in statistics regarding complications [63], [76]. In other cases, symptomatic synechiae with an incidence of 1–3% are documented [80], [98], [91], [274]. After tumor surgery, the rate of scar-induced consequential effects is higher (5%), likewise after transsphenoidal skull base surgery (about 9%) [42], [275].

The benefit of special postoperative follow- up in order to optimize healing is partially questioned [276], [277], [278]. On the contrary, the benefit of this treatment for prophylaxis of adhesions and synechiae is stressed by other sources [98], [279], [280], [281], [282]. Especially in differentiated and extended surgeries, e.g. at the ostium of the frontal sinus, the subjective and objective benefit should be beyond dispute. The general acknowledged postoperative "basic care" consists of rinsing with saline, mechanical cleaning and topical corticoids [283]. A routine administration of antibiotics does not improve the result [284]. Non absorbable nasal packing can help to avoid synechiae or adhesions [282]. Absorbable nasal packing (MeroGel®, Nasopore®) is supposed to have the same effect [180], [285]. Specific placeholders have been developed with the same intention [286].

The so-called **"missed ostium sequence"** develops in case of suboptimal fenestration of the maxillary sinus via middle meatus with a untouched, separate and insufficient natural maxillary ostium (covered by remains of the uncinate process, i.e. possibly overlooked intraoperative) [25], [185]. Despite of a well-intended fenestration in the middle (or, in rare cases, also the inferior) nasal meatus, persistent symptoms arise in the corresponding maxillary sinus [287], [288] (Figure 2). Treatment comprises the microsurgical unification of the two ostia with excision of the uncinate process. If there are two functioning maxillary sinus ostia on the same side postoperative (primary ostium, natural secondary ostium, surgically created neo-ostium in the middle and/ or inferior nasal meatus), then, in special cases, a circular recirculation of mucosa from the maxillary sinus and back to this sinus can establish (also in form of a partial circulation). The symptoms can be similar to those of "missed ostium sequence" [273], [287]. The treatment again, consists in a surgical unification of the ostia (see above).

After an ethmoidectomy, in 10–40% of cases, there is a more or less apparent, **scar-induced lateralization of a detached vertical lamella of the middle turbinate**. In up to 7% of cases, a lateral synechia can arise in the area of the medial orbital wall [265], [289] (Figure 3). The use of a shaver prevents this development [274].

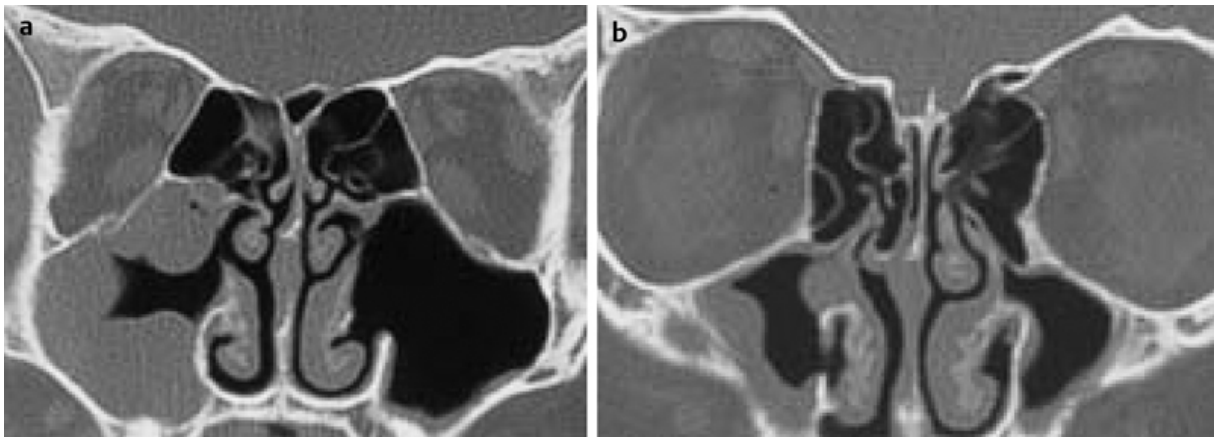

Figure 2: CT-scan (coronal plane) of a patient having been subjected to middle meatal antrostomy. "Missed ostium sequence" on the right side leading to persistence of maxillary sinusitis.
a. Neo-ostium of the maxillary sinus in the middle meatus.
b. Preserved, intact uncinate process and persistent obstruction of the natural maxillary sinus ostium due to mucosal edema of the neighbouring mucosa.

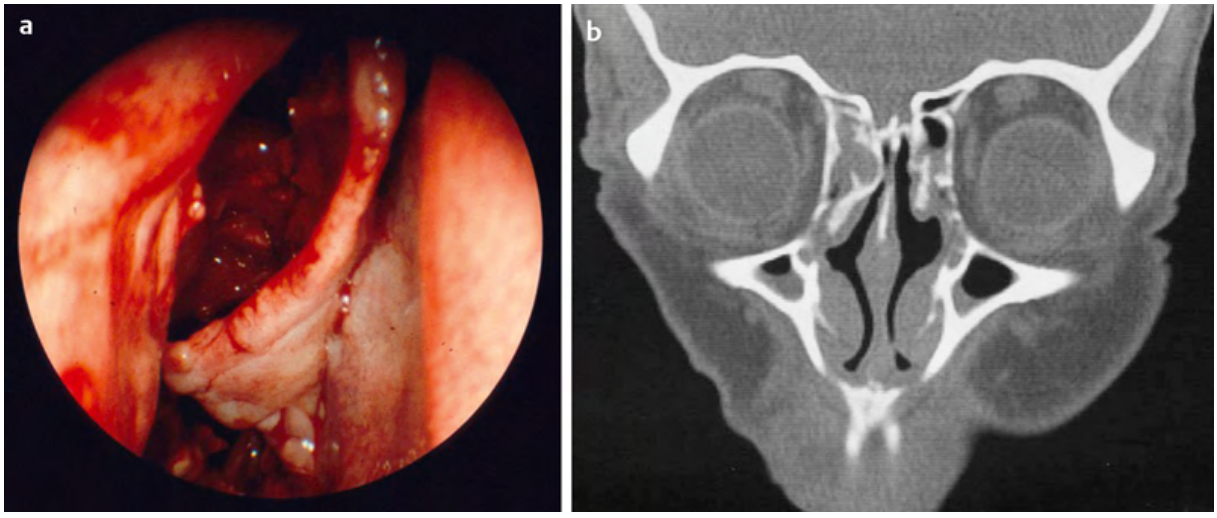

Figure 3: a. Intraoperative picture of a "floppy turbinate" (right side).
b. CT-scan of a patient having been subjected to anterior ethmoidectomy. Lateralization of the right sided vertical lamella of the middle turbinate causing inflammatory retentions in the ethmoidal cavity.

The lateralization of the vertical lamella of the turbinate with its possible adverse effects, e.g. with regard to frontal or maxillary sinus drainage, has caused a long lasting discussion focusing on partial resection of the anterior middle turbinate as prevention [2], [100], [290], [291]. This may be performed especially in case of an evidently fractured or destabilized vertical lamella during surgery. Nevertheless, many authors approve of conserving the turbinate [185], [288], [292]. In individual cases, an "empty nose" syndrome has developed after resecting the middle nasal turbinate [293]. In contrast, no negative effects of a routine anterior 1/3 resection have been observed in a case series [294], [295], [296]. The rate of recurrent nasal polyposis was lower [297] and there was a tendency of improved olfactory function [298]. The number of lateral synechiae also decreased, although the synechiae developing during therapy in spite of partial resection were more challenging [299], [300], [301].

In order to prevent scar-induced lateralization of a conserved, but mobile vertical lamella of the middle nasal turbinate (**"floppy turbinate"**), a number of recommendations can be found in literature:

- Special supporting septum foils (splints) for about 14 days [100], [302].
- Establishing a small, "controlled synechia" to the nasal septum [303], [304], possibly using fibrin glue [305]. A secondary olfactory impairment was not observed [306].
- Fixation of the lamella via suture to the nasal septum [100], [307]. Suturing is performed against tissue resistance of the turbinate and septum which, in individual cases, can lead to a further destabilization of the turbinate [303]. An olfactory impairment was not observed, either [308].
- Fixation of the lamella with customary clips introduced into an artificial pouch in the mucous membrane of the nasal septum by means of a branch [282], [289].

A similar effect is produced by an absorbable clip placed into the mucous membrane of the septum onto which the lamella of the turbinate is pinned [309]. This clip consists of polylactides.
- Absorbable, cortisone-releasing stents with grid-structure in tubular form which may be inserted into the ethmoid labyrinth are under development [310].

4.5 Hyposmia

In human anatomy the exact dimension of the olfactory region is unknown. It is formed by an area consisting of the anterior 3/4 bony part of the common vertical lamella of the middle and superior nasal turbinate ("conchal plate"), together with the dorsal part of the roof of the nasal cavity and the adjoining parts of the nasal septum [311], [312], [313].
In general, postoperative smell deficits may occur after direct mechanical trauma, after removal of olfactory mucosa accompanied by scarification of the latter, caused by a progressive inflammation of the mucosa or even by a postoperative modification of the nasal air passage. A partial resection of the lower third of the anterior middle nasal turbinate does not affect the ability to smell - in routine resections, there was no evidence of olfactory mucosa in the surgical specimens [314]. On the other hand, a complete postoperative anosmia was reported, following a resection of the superior nasal turbinate that was done by mistake [313]. Olfactory fibers in the turbinate bone can also be damaged without any resection, e.g. by mere fractures occurring in the context of a "mobilization" of the turbinates – however, because of the remaining septal fibers, a hyposmia and no anosmia could be expected [315].
Preoperatively, about 17% of the routine patient population suffering from chronic rhinosinusitis is affected by olfactory disorders. After surgery, many of these patients can expect an improvement or a normalization. 16% of patients suffering from preoperative olfactory disorders were not aware of their impairment. For medico-legal reasons, these circumstances suggest that a preoperative measure of olfactory ability should always be performed. For rough orientation purposes, the rate of a postoperative arising hyposmia is indicated at about 3%, whilst the rate of a postoperative smell deterioration is estimated at about 9% [316], [317].

4.6 Atrophic rhinitis

After extensive nasal surgery, secondary atrophic rhinitis may develop (Figure 4a). Literature focuses on consecutive states of excessive surgical procedures performed on the inferior nasal turbinate [291]. However, such an iatrogenic, secondary atrophic rhinitis can also develop after extensive and usually recurrent sinus surgeries, with removal of larger areas of mucous membrane and resection of the middle or superior nasal turbinate. The latter group of patients represent about 10% of the patient population suffering from secondary atrophic rhinitis [318]. The internet offers patients affected by the "empty nose syndrome" (ENS) a special website: "Empty Nose Syndrome Self-Help Website" (http://www.emptynosesyndrome.org/), – here, the excessive resection of any turbinate tissue within routine sinus surgery is referred to as a "nasal crime".
Patients complain about a paradox nasal obstruction, in the presence of an objective wide inner nose. Further symptoms are dyspnea, a dry feeling in nose and pharynx, hyposmia and depression. If the sphenopalatine ganglion is intensively exposed towards nasal airflow after extensive tissue resection, additional pain may be caused. For unknown reasons, only very few patients develop an ENS after generous resection of turbinate tissue apart from the inferior turbinate - possibly due to the fact that due to the underlying chronic rhinosinusitis, hyperplastic mucous membrane often forms postoperatively. ENS often develops with a latency period of several years postoperative [290], [291], [319], [320], [321], [322].
Even without a fully developed secondary atrophic rhinitis, roughly 13% of patients after pansinus surgery with partial resection of the medial concha and adjacent procedures on the inferior turbinate or the nasal septum are affected by a disturbing formation of crusts in the nose. In 5% of patients, this state leads to a significant impediment of their daily well-being [323]. Regarding treatment of mucociliary circuits (see above), in some cases a "mega antrostomy" is recommended [288]. Similar to "medial maxillectomy", excessive loss of concha tissue may occur, resulting in a dry nose. In oncological surgeries of the maxillary sinus, the only precaution which can be taken consists in a temporary displacement of the inferior turbinate [324], [325]. In routine surgery of chronic rhinosinusitis, the rate of postoperative atrophic rhinitis is roughly between 0.08 and 0.4% [72], [98]. Therapy is mainly conservative, based upon intensive moistening, local care with the administration of ointments or oils [291], [320].
Rhino-neurosurgical procedures often lead to a serious, long-term and substantial restriction of postoperative nasal physiology [182], [326]. As a matter of principle, an irritating crust formation, accompanied by a restricted nasal physiology, occurs in up to one third of all cases [42], [102]. Regarding transsphenoidal approaches, a rate of 10% is mentioned [42]. Attaching laminar, pedicled mucous membrane flaps to the nasal septum adjusts this dysfunction [252]. The extremely irritating crust formation lasts for at least 100 days [326]. Further possible consequences are synechiae, septum perforations, burns or mechanical skin damage at the nasal vestibulum caused by drills and other instruments [42], [182]. Techniques to decrease the size of an extensive wound in the mucous membrane of the nasal septum have been mentioned ("reverse rotation flap") – however, they come at the cost of a larger posterior septum perforation and cannot guarantee a complete recovery of the nasal physiology [327] (Figure 4b).

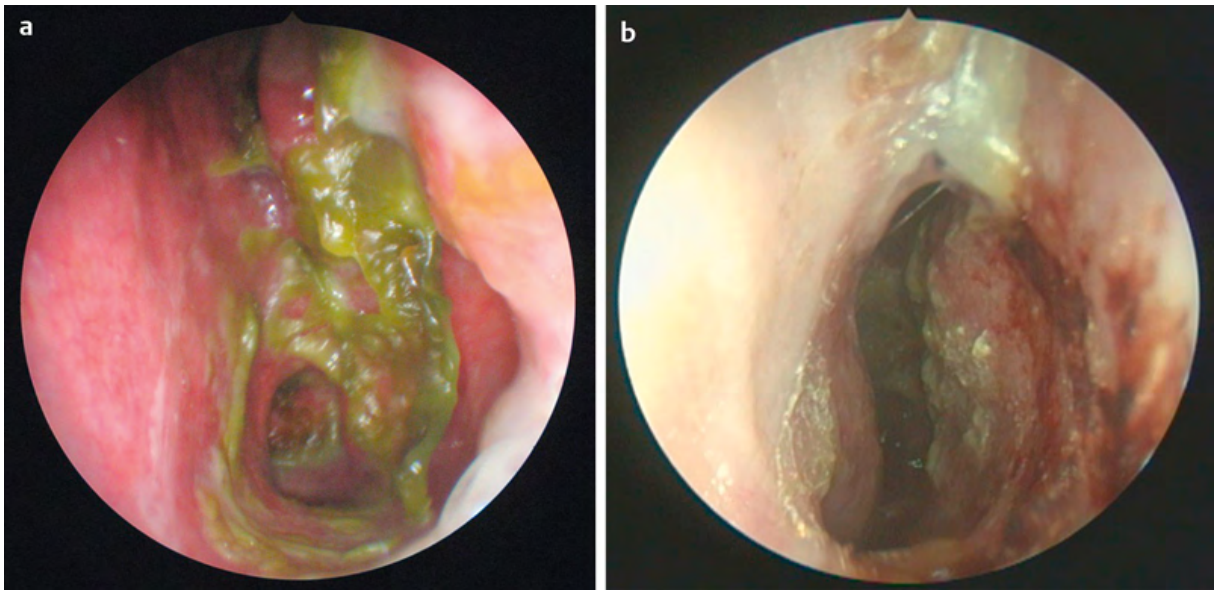

Figure 4: a. Left nasal cavity of a patient having been subjected to extensive ("radical") sinus surgery for chronic rhinosinusitis leading to "empty nose syndrome".
b. Right nasal cavity of a patient having been subjected to a rhino-neurosurgical intervention for craniopharyngeoma with application of a naso-septal flap. Irrespective to use of a "reverse flap" for amelioration of postoperative crusting, significant atrophic rhinitis is seen.

4.7 Nerve injuries – infraorbital n., alveolar n.

In a rather aggressive mode of preparation or when electrosurgical measures are applied in the maxillary sinus, an injury of the infraorbital n. at the roof of the maxillary sinus may result.
Bony dehiscences in the channel of the infraorbital nerve increase the risk of such a complication.

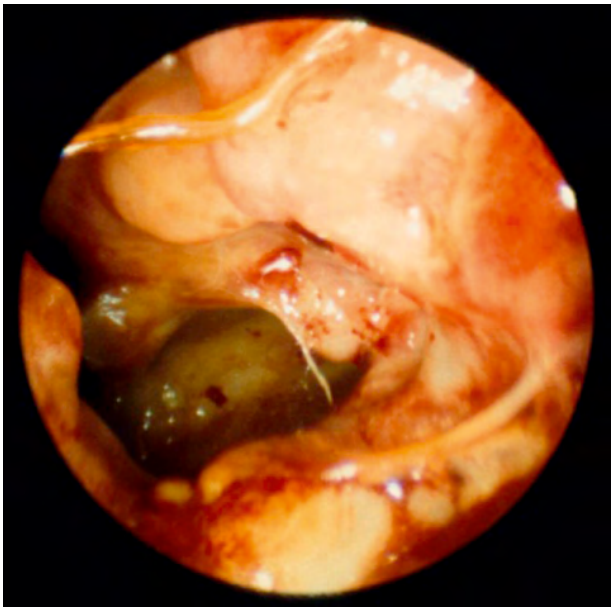

Figure 5: View of the left maxillary sinus after middle meatal anstrostomy (70° angled optical device). The inferior orbital n. revels signs of partial destruction (small nerve ending is hanging down from the orbital roof).

As a consequence, facial sensibility is affected postoperative [76], [288] (Figure 5). The same applies to the alveolar nerves. The rate of postoperative sensibility disorders of teeth or lips and cheeks respectively is about 3% for all cases combined [72].
In justified individual cases of endonasal procedures, a complementary, localized transoral puncture of the maxillary sinus is recommended in order to remove hyperplastic mucosa in hidden anatomical areas, e.g. via insertion of a shaver [25], [328]. Only about 3% of patients benefit from this procedure, its use within the scope of pansinus surgery in case of polyposis is questionable [53], [328]. In an adverse case, a branch of the infraorbital n., above all the superior alveolar n. is damaged [288]. In 3/4 of all cases, complications occur postoperatively, such as cheek swelling, face pain, numbness of the face or teeth or even paresthesia. In about 30% of patients, these complaints remain in part permanently, most likely as a local dysesthesia [328].
A relatively safe location for a complementary puncture is the intersection of two reference lines, i.e. a vertical line through the equilateral pupil and a horizontal line exactly along the nasal base [329]. If these measures are respected, the rate of temporary inconveniences is reduced to 45% and the rate of persisting problems is reduced to 5% [330].
In transpterygoid rhino-neurosurgical approach, amongst others, the maxillary or the vidian n. can be damaged [182]. Consequential effects of the latter lesion correspond to those of a vidian neurectomy which often leads to a temporary reduction of the lacrimal secretion (xerophthalmia, postoperative incidence 12–30%) and reduction of the moistening of nasal mucous membranes [331], [332]. Past references depict single cases of severe orbital complications of vidian neurectomy. Recent literature

only reports occasional cases of e.g., combined injuries of the local trigeminal n. and sympathic n. with neurotrophic keratopathy, miosis and headaches after monopolar coagulation at the vidian n. [333].

5 Severe or threatening complications

5.1 Orbital haematoma

Concerning the orbital haematoma, the slowly developing, venous hematoma is distinguished from the comparatively fast evolving arterial hematoma [334]. The incidence of orbital hematomas is around 0.1% in all procedures [71], [114]. With right handed surgeons, orbital complications are supposed to occur more often on the right side, whilst other authors report a preference of the opposite side [100], [114].

A threatening venous bleeding is mostly observed with a delay, i.e. postoperatively with a progressive exophthalmos. It is safe to assume that an accumulation of 5 ml of blood can already lead to a dangerous intraorbital increase in pressure, causing a loss of vision. Therefore, even in case of seemingly slightly developed orbital hematomas, vision must be controlled repeatedly. A simultaneous control of color vision is recommended – here, restrictions occur in a relatively early stage [76], [113]. As a basic principle, cooling compresses are applied and the top end of the bed is raised [114]. In case of threatening development, an emergency ophthalmic consultation is recommended. Nasal packing is removed and the intraocular pressure is measured. The digital ocular massage is recommended various times in literature; it is, however, contraindicated in patients with illnesses of the bulbus and is debatable even in patients without a special ophthalmological anamnesis (see below). Further conservative treatment and possibly surgery as therapy of threatening venous hematoma is identical to the therapy for arterial bleeding [133], [335].

Retrobulbar hematoma

The retrobulbar hematoma as an arterial bleeding with a swift increase in intraorbital pressure is dreaded (Figure 6b). It appears intraoperatively and often even with delay, e.g. in the recovery room. Literature points out rare cases of a hematoma occurring hours later – for outpatient surgery, this has to be taken into consideration [335].

Consequently a progressive proptosis with chemosis, pain, congestion of the conjunctival vessels and, eventually, ecchymoses or subconjunctival bleeding develops. During palpation, a distinct resistance of the orbital tissue is felt and an increased intraocular pressure is noticed. Ocular motility is disturbed and the pupil reaction is pathological (in side comparison, reduced or absent pupil reaction), resulting in visual field loss and loss of vision. Fundoscopic findings are: pulsation of the central retinal artery, central retinal artery occlusion, retinal edema, venous congestion, macular edema [68], [114], [135], [336], [337], [338]. The orbital hematoma is a clinical diagnosis. It is not necessary to wait for a radiological confirmation [337].

The most frequent cause is an injury of the anterior ethmoidal a. at the medial anterior ethmoid roof with a secondary retraction of the bleeding artery into the orbit [114]. Alternatively, the blood vessel is pulled out of its bed at the base of the skull, together with the onset of the vessel inside the orbit [82]. A similar event rarely occurs in the posterior ethmoidal a. [335].

There is a risk of blindness, though the pathogenesis is not completely clear: A pressure-related occlusion or a spasm of the ophthalmic or the central retinal a., a direct compression of the optic nerve or discontinuation in the immediate vascularization of the optic nerve [114] are suspected as possible triggers. Other mechanisms are a blockage in the blood flow of the posterior ciliary arteries, caused by pressure or tension. The increased intraorbital pressure is most likely to produce an effect upon the venous system [76], [104], [339].

According to literature, in case of imminent loss of vision, a maximum duration of about 90 minutes remains until definite amaurosis. This basically depends on the ischemic tolerance of the retina [68], [114], [135], [336], [338], [339], [340], [341], [342], [343]. A pressure-related interruption of the axonal transport in the optic n. can be endured for 8 hours, a total ischemia can be endured for 2–3 hours [341], [343], [344], [345], [346].

In animal testing, slightly longer durations (100 – about 120 minutes) were determined for the retina [347], [348]. Individual factors (among others, a preexisting subclinical vasculopathy and anatomical factors) can generally strongly modify the tolerance of the organism in regard to an increase in orbital pressure [347]. The dynamics of the increase in pressure may also play a role [76]. As animal testing for orbital hematoma cannot be easily standardized, it is sometimes problematic to transfer the scientific findings to humans [346].

Sinus surgeons should have a clear action-algorithm in the case of an orbital hematoma. For the purpose of early diagnosis the patient's eyes should remain accessible during surgery for intraoperative control [339].

The following initial measures are recommended:

- If the emergency occurs in the OR, the initial procedure is shortened or terminated [114]. In other cases, the top of the bed is raised to 45 degree and cooling compresses (ice) are administered. If necessary, the blood pressure is normalized. The patient should neither cough nor induce abdominal muscular pressure [337], [339], [349], [350].
- Nasal packing is removed as much as possible; stop any bleeding if possible [68], [104], [114], [339], [349].
- An ophthalmologist should be informed or consulted – if time and the organization make this possible. The aim is to make an exploratory examination of visual acuity, visual field, and pupillary response. Fundoscopy

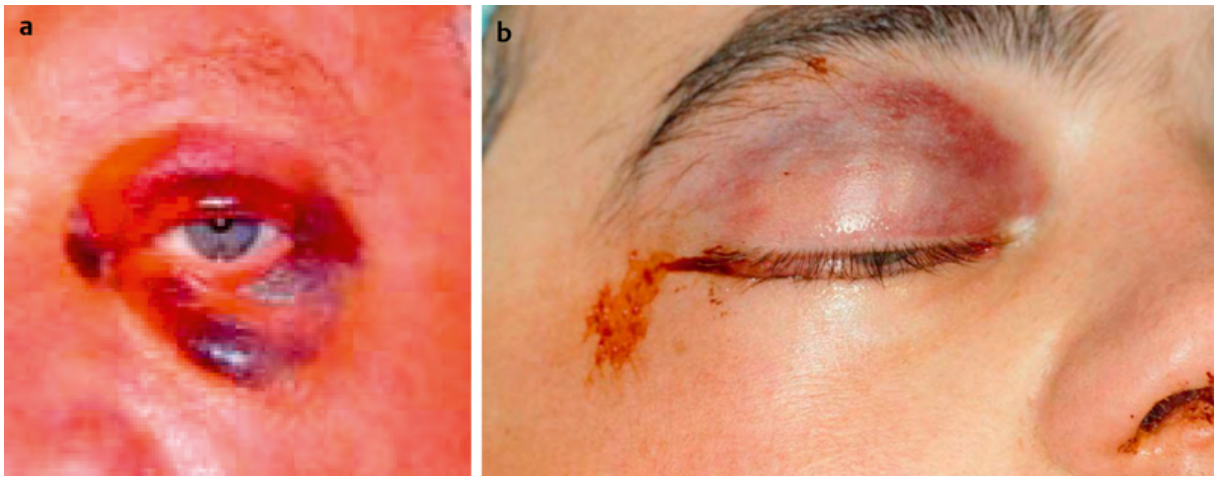

Figure 6: a. Left-sided "preseptal", venous orbital hematoma following sinus surgery for chronic rhinosinusitis. Healing without any residual problem may be expected.
b. Patient revealing major right-sided intraorbital hematoma in the course of ethmoidectomy. Lateral canthotomy and also inferior canthoysis have been performed.

should be performed as soon as possible [113], [114], [133], [135], [350].

- Digital ocular massage of the affected eye or manual pressure is often recommended. The massage will lead to the redistribution of the hematoma. This effect is subject to controversy, although case reports which emphasize this fact exist. In any case, contraindications have to be taken into account regarding all patients with a history of ophthalmic procedures, such as a corneal-, retinal- or glaucoma surgery [68], [76], [100], [109], [114], [133], [135], [340]. Other authors generally disadvise digital ocular massage or manual pressure [113].

Other measures include:

- A medial decompression of the orbit via an endonasal approach. The lamina papyracea is removed and an incision is made in the periorbit extending posterior to anterior [68], [114], [349], [351]. Postoperative enophthalmos may occur [352].
- The lateral canthotomy and cantholysis (see below) [68], [114]. If it fails, additionally, the orbital septum can be detached from the orbital rim via the access created or it can be split by a separate transcutaneous incision of the lower eye lid [337], [351].
- The medial decompression of the orbit via an external or a transcaruncular approach [340], [349]. Here, a direct surgical treatment (electrocoagulation, ligature, and clip) of the bleeding ethmoidal vessels is sought. There are positive reports in literature [76], [109], [114]; anatomical orientation was endoscopically facilitated in individual cases [353]. Other sources, however, think the chances to ligate the vessel directly are rather slim [82], [335]. Additionally, the medial orbital floor could be partially removed via the same approach – however, in cases of extended decompressions, postoperatively a more or less distinct enophthalmos must be expected to occur [340], [352].
- An exploration or decompression of the lateral orbit [68], [340]. For instance, an inferolateral, anterior orbitotomy approach through canthotomy and cantholysis with blunt stretching of the tissue is recommended. The aim is to relieve the retrobulbar haematoma directly to the outside [354].
- An infraction of the orbital floor [68] respectively, resection of the orbital floor, e.g. via a transoral or transconjunctival approach [339], [350].
- In case of extreme emergency, the ophthalmologist may recommend an anterior chamber paracentesis in order to release aqueous fluid e.g. in case of a blockage of the central retinal artery [339], [351], [355]. However, it is considered very critical in view of its possible side effects and effectiveness [337], [340], [350], [356].

The following accompanying medication is indicated:

- Mannitol 20% (1–2 g/kg body weight i.v.; for 30 minutes). Mannitol needs 20 to 30 minutes until the effect is achieved; sometimes the effect is not sufficient [76], [100], [109], [113], [114], [135].
- Cortisone (Dexamethasone 8–10 mg i.v.; every 8 hours, up to 4 x) [91], [114], [135], [350]. As mentioned before, the effectiveness of this medication is not clarified; only a slight reduction in orbital pressure is achieved [76], [113], [337].
- Acetazolamide (i.v., 500 mg) [91], [114], [338], [349], [350]. The administration of acetazolamide results in a reduced production of aqueous fluid – the desired effect takes place slowly [100], [114], [357].
- Timolol eye drops (0.5 %, 1–2 drops 2x daily). Regarding the effect, the same applies as for acetazolamide [114], [135], [357], [358].
- The administration of antibiotics is recommended. Following the emergency care a CT scan should be performed – an MRI is only indicated when suspecting a haematoma of the optic nerve sheath [122], [135]. If a relevant, remaining haematoma can be clearly

localised with the CT, a revision surgery for means of decompression should take place [339].

In principle, there is no solid proof of effectiveness regarding conservative treatment. Analogies from traumatology form the basis for the recommendations, partly any effect is denied [71], [82], [337], [340], [359]. The regimes are variable, e.g. frequently mannitol infusions are administered over a longer period of time or the dosage is lowered [98], [91], [338], [349], [350]. Partly acetazolamide is prescribed in a lower dose or administered for longer periods (125–250 mg i.v., 4x/d) [98], [338]. In individual cases, the therapy with cortisone is based on other substances (e.g. methylprednisolone 1 g i.v.) [338] or different dosages (prednisolone 60 mg) [98].
The indication for a surgical approach is often discussed in literature on the basis of an objective measurement of the intra-ocular pressure (IOP) [113], [349]. However, in daily routine the indication mainly takes place clinically, the pressure conditions can be estimated via comparative bilateral palpation [135], [337], [360]. The orbital pressure (OP) correlates well with the intra-ocular pressure (IOP) – but not the proptosis. With individual differences, the orbital pressure is approx. 11 mm Hg below the IOP; standard values of orbital pressure are around 3–6 mmHg [104], [337], [361]. Generally surgery of the paranasal sinuses has no effect on the intra-ocular pressure [362].
Emergency indication for canthotomy and cantholysis is assumed for an IOP above 40 mmHg [100], [135], [340], [342], [363]. In different references, surgery is necessary if the intra-ocular pressure (IOP) is higher than the mean arterial pressure minus 20 mmHg [104].
Lateral canthotomy results in a reduction of the intra-ocular pressure by approx. 14 mmHg, cantholysis leads to a decompression of approx. 30 mmHg [364]. An orbital decompression may cause an additional pressure reduction of 10 mmHg [114]. With complementary measures (e.g. orbital septolysis) the orbital pressure (OP) can be reduced by approx. 70% [361].

Technique of the lateral canthotomy and cantholysis

Lateral canthotomy with cantholysis is an emergency procedure. It is simple and every sinus surgeon should be able to handle it. The surgery can take place almost everywhere (e.g. also in the recovery room) under local anaesthesia (local infiltrative anaesthesia). At first a straight, small vascular clamp is placed from the lateral canthus towards the border of the bony orbit between the upper and lower eyelid and is compressed. Then, the canthus is incised in a horizontal direction along this "compressed area". To restrict surgery merely to this horizontal incisure is not recommended by the majority [349], [358] – the inferior and, if necessary, the superior cantholysis should complement canthotomy. The lateral inferior palpebral ligament between conjunctiva and external skin of the eyelid is identified during the inferior cantholysis. It shouldn't be a rule for the inferior cantholysis, but it is basically considered as legitimate, that the external skin is also incised in the event of true emergencies. The palpebral ligament is completely dissected in caudal direction – during this process, it is repeatedly identified by palpation. The immediate release of the inferior eyelid is noticed when the forceps is held into place with a certain tension at the lower eyelid [114], [135], [336], [350], [365], [366]. Many authors suggest to perform the canthotomy [114], [361], [365] followed by inferior cantholysis only. Others recommend an additional incisure of the upper palpebral ligament if the canthotomy with inferior lysis is not effective [156], [337], [339], [353].
It is important to consider that the effects of this procedure are limited in time [361]. In the worst case the decrease in orbital pressure due to successful canthotomy/cantholysis is followed by additional intraorbital bleeding [353]. The increase of proptosis of the eyeball after surgical decompression may result in a pointed elongation of the posterior pole of the eyeball ("globe tenting"). If the angle of this protrusion is less than 120 degree, the eye is definitively at risk [367] (Figure 7).

Figure 7: Detail of an axial CT scan outlining the contour of the right sided eye globe in red. The respective patient had been subjected to an ineffective decompression procedure for a retrobulbar orbital hematoma. The posterior pole of the globe reveals significant tenting indicating critical expansion of the hematoma [367].

In principal, the wound of the lateral canthotomy/cantholysis could be left to heal itself. As a rule, however, the wound is sutured with a delay of 2 to 5 days, e.g. with Vicryl 7 x 0 [114], [122], [337], [365], [368]. For secondary reconstruction of the lateral palpebral ligament, the

special anatomy of the anchorage of the lateral canthus must be considered [100], [366], [369].
Regarding prognosis it is known from traumatological literature that the risk of permanent blindness with manifest retrobulbar hematoma with accompanied loss of vision is approx. 50 % [114], [135], [336], [338]. Vision recovery takes place within a time frame of approx. 30 hours. Prognosis for younger patients is better [337].

Paraffinoma

A special case report is presented of an orbital "compartment syndrome" resulting after misplaced dilation of the frontal sinus and insertion of 5 ml bacitracin ointment. As a consequence the intra-ocular pressure was raised up to a pressure level of 54 mmHg (IOP). Canthotomy and inferior cantholysis reduced the pressure to 32 mmHg and there were no relevant permanent damages [370].
In other cases, a paraffinoma may develop especially within the region of the eyelids after a sinus operation. In the event of a (often minimal) injury of the lamina papyracea with a (often mild) orbital haemorrhage and if a paraffinic nasal packing (ointment strip) or ointment is inserted into the nose the paraffin can be absorbed via the mucosal wound in individual cases and transported via blood into the soft tissue of the orbit, respectively eyelids. The material deposits and results with a different time latency (weeks to years) in a noticeable granulomatous foreign body reaction ('paraffinoma') of different degrees of intensity. Externally visible is an even "pseudotumour" with discolouration of the skin like a xanthelasma. In rare cases, the inflammation continues as sclerosing lipogranulamatosis or as orbital pseudotumour, in a rare case this may lead to the development of a sinogen orbital phlegmon. Spontaneous, partial regressions are rare. Classic paraffinomas should not occur any longer due to modern types of nasal packing in use (and due to tendencies to disclaim packing at all). Despite this fact, appropriate casuistic case reports still exist [358], [371], [372], [373], [374], [375]. If the history of the patient does not include a sinus operation, differential diagnoses are, among others: xanthelasma, panniculitis, erythema nodosum, sarcoidosis, traumatic fat necrosis and lid involvement in Melkersson-Rosenthal syndrome [376]. Two special cases of a lipogranulomatous tissue reaction were reported 2 to 14 days following an endonasal sinus operation, where no oily material was inserted. There was a palpable tumour of the eyelid, eye movement disorder and proptosis. The granulomas were externally removed by surgery and oral corticoids and also an antibiotic were administered. Concerning pathogenesis, an intraoperative injury of the orbit with focal fat necrosis and a consecutive tissue reaction on extracellular fat were assumed [377].
The treatment of paraffinomas is surgical excision. Histologically, the resected tissue resembles the pattern of a "Swiss cheese", caused by vacuoles after washing out of the paraffin besides granulomatous reaction without capsular formation. A complete resection is usually impossible because of the diffuse tissue infiltration [378].
Myospherulosis is related to the paraffinoma. It corresponds to a foreign body reaction of the mucosa to ointments containing lipids. Typical aggregates of erythrocyte residuals are histologically found in the vacuoles. Factors that predispose the development of myospherulosis are not yet clarified. Patients tend to present a higher rate of postoperative synechia leading to a high number of revision surgeries [379]. Myospherulosis granulomas also may form within the area of the eyelid following sinus surgeries with intraoperative haemorrhage of the eyelids and perioperative use of nasal packing with ointment [380].

5.2 Relevant bleeding (anterior ethmoidal a., posterior ethmoidal a., sphenopalatine a. and internal carotid a.)

Injury of the sphenopalatine a.

The microanatomy of the pterygopalatine fossa and the sphenopalatine foramen plays an important role in sinus surgery [381]. In 80% the sphenopalatine foramen is located in the superior nasal meatus or in the transition area between the middle nasal meatus and the superior nasal meatus, directly behind or below the ethmoidal crest of the palatine bone. In about 13% of cases, several ostia are found [382], [383], [384]. Correspondingly, in about 97% of cases, the sphenopalatine a. is divided into two or more branches. In 64% of cases, between 3 and 10 branches may enter the lateral nasal wall, above as well as below the ethmoidal crest [383], [385], [386]. Further terminal branches of the maxillary a. are the pharyngeal a. (via palatovaginal canal to the nasopharynx), the naseseptal a. (posterior nasal ramus or posterior septal ramus, via the anterior wall of the sphenoid sinus to the nasal septum) and the descending palatine a. [387].
If the routine opening of the maxillary sinus in the middle nasal meatus is systematically enlarged in dorsal direction, up to the level of the posterior wall of the maxillary sinus, then, in individual cases, it will be necessary, for anatomical reasons, to cut through a branch of the sphenopalatine a. [150]. Bleeding from the root of the sphenopalatine a. occurs during surgery at the posterior process of the middle nasal turbinate or within the scope of an endoscopic neurectomy of the vidian nerve. During extended surgical procedures in the area of the infratemporal fossa severe bleeding from the maxillary a. may occur [176], [332] (Figure 8). Instructions to identify the sphenopalatine a. endoscopically and to handle it by electrosurgical techniques or clipping are part of many ENT surgery manuals (for example [28]) and corresponding rhino-neurosurgical training programs [388].
In rare cases, a pseudoaneurysm may form as a result of an injured sphenopalatine artery. A recent case report

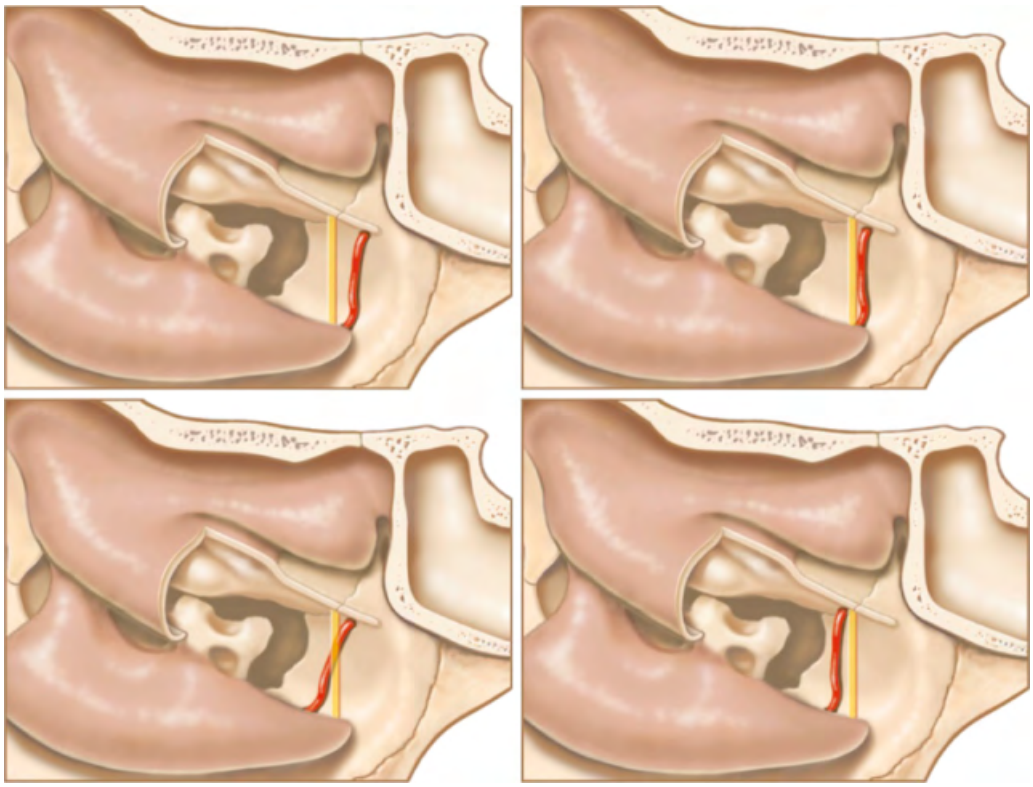

Figure 8: Individual anatomical relation of the posterior wall of the maxillary sinus in the frontal plane (depicted in yellow) and branches of the sphenopalatine a. supplying the interior turbinate (depicted in red) (refer to: [150, 654]). The diagram illustrates that generous fenestration of the maxillary sinus in the middle nasal meatus inevitably will cause relevant bleeding in some cases.

depicts a pseudoaneurysm with a size of 1×1.4×1.5 cm. It was discovered 13 days after sinus surgery took place, which is quite early. – In general, such pseudoaneurysms evolve after 1 to 8 weeks. The authors prefer embolization rather than targeted endoscopic treatment (clipping) of the maxillary a. [389].

When entering the sphenoid sinus, the surgeon encounters the septal branch of the sphenopalatine a. (nasoseptal a.), in the lower third of the anterior wall of the sphenoid sinus [12], [390]. In the area of the anterior wall of the sphenoid sinus, it is mostly divided into three branches which supply the nasal mucous membrane [391]. In about 3% of pituitary surgery, postoperative bleeding from this vessel is observed. Within the scope of ENT routine surgery, an electrosurgical handling of this vessel is possible without any complication. In case or repeated perioperative bleeding, angiography with selective embolization will only be performed in extremely rare cases [101], [392], [393], [394]. This applies especially for embolization in case of a treatment-resistant nose bleeding after routine sinus surgery when the source of bleeding does not evolve the internal carotid artery. The exposure of radiation during embolization is relevant (around 18 minutes in single series). Moreover, embolization has a risk profile, in general, that shouldn't be neglected (e.g. neurologic/cerebrovascular complications, blindness, loss of sensation and skin necrosis) [395].

The pharyngeal ramus of the sphenopalatine a. passes through the palatovaginal canal, close to the floor of the sphenoid sinus. It is a rare source of bleeding, e.g. in the scope of the transpterygoid approach or while removing the floor of the sphenoid sinus [396].

Injury of the anterior ethmoidal a.

The anterior ethmoidal a. is most frequently identified (85%) at the skull base between the second and third ground lamella, traversing diagonally from posterior-laterally to anterior-medially. The angle between the artery and the lamina papyracea is around 60% and the vessel has a diameter of about 0.8 mm [397], [398], [399], [400].

In some of the cases the artery is located directly in the area of the osseous skull base, and more frequently (ca. 40%), it has a separate osseous canal at a distance of approximately 3.5 (1–8) mm [399], [400], [401]. Bilateral anatomy often reveals asymmetry (45%) – hence, the distance from the skull base to the anterior ethmoidal a. on the right side is larger in average than on the left side [402]. Dehiscences of the bony covering of the vessel are reported in 16–90% of cases [186], [390], [400], [402], [403]. According to anatomical studies, the anterior ethmoidal a. is missing in about 5–10% of cases [390], [403], [404].

The anterior ethmoidal a. can be easily injured during surgery of the anterior ethmoid. Arteries at risk are those with a larger distance to the skull base, arteries with bony dehiscences or those running within a ground lamella [398]. Lateral injuries in the area of a funnel-shaped, medial-directed protrusion of the orbital wall can result

in a threatening orbital hematoma, after retraction of the vessel stump (see above). In approximately 90% of cases, this protrusion of the orbit can be identified easily in the coronal CT scan. It is situated in the level below the superior oblique m., above the medial rectus m. [397], [401], [405].
If the artery has been injured and is bleeding into the ethmoidal cavity, a bipolar or monopolar coagulation is generally used to stop the bleeding [113]. Many authors avoid the monopolar coagulation at the skull base due to possible secondary damage to the meninges [100], [133], [402]. Alternatively, clips are suggested, which, however, are not always effective, due to anatomical reasons [100], [402], [406].

Injury of the posterior ethmoidal a.

With a diameter of ca. 0.6 mm, the posterior ethmoidal a. is smaller than the anterior ethmoidal artery [100], [397], [404]. It runs almost regularly (in 92% of cases) at the level of the bony dorsal rhinobasis and is therefore more difficult to be identified endoscopically. Its course is mostly (95%) symmetrical and linear, with bony dehiscences occurring in almost 60% of cases [100], [390], [397]. The distance between the anterior and the posterior ethmoidal artery is approximately 10–14 mm and the distance from the latter to the optic nerve as well as to the anterior wall of the sphenoid is about 8–9 mm [12], [100], [403], [404]. In a coronal CT, a tip-like protrusion of the medial orbital wall at the location of the posterior ethmoidal a. can be seen in two thirds of cases [405]. According to literature, an aplasia of the artery may be observed in 2% to 34% of cases [404]. – Conversely, in up to 30% of cases, a third ethmoidal a. is described [390], [403].
As a general rule, the posterior ethmoidal a. can be injured during manipulations at the posterior ethmoid bone or during entry of the sphenoid sinus [12]. A case report depicts a secondary orbital hematoma without significant proptosis, but with blindness [407]. A subperiosteal orbital hematoma with visual impairment should be equally rare – symptoms were reversible after an emergency hematoma decompression [408]. Uncomplicated hemorrhages in the posterior shaft of the ethmoid bone are treated with electrocoagulation [100].

Injury of the internal carotid a.

From a neuroradiological/neurosurgical point of view, the course of the internal carotid a. may be subdivided into 5 to 7 sections. In the scope of routine sinus surgery, the cavernous (interdural/ intracavernous) and clinoid (interdural/paracavernous) sections are particularly relevant, and in exceptional cases, the cisternal (intradural/intracisternal) section may also be significant [409], [410], [411]. There are important neighbouring anatomical structures, especially the optic n. The distance between the internal carotid a. and the optic nerve is 2–10 mm, bridging the lateral optico-carotid recess [412], [413].
Surgery performed in the sphenoid sinus requires sufficient preoperative diagnostic measures based on cross-sectional imaging [95], [97]. Particularly in the axial CT, significant anatomical details or variants are displayed: In principle, the carotid a. nearly regularly bulges out in the anterior lateral wall of the sphenoid sinus (in 80% of cases) [409], [414]. In about 15% of cases, this protrusion in the medial direction is very prominent [106], [401]. Dorsally, another prominence of the artery can occur in the lateral wall of the sphenoid sinus. – The degree to which protrusions are seen is supposed to increase with age. The bony canal of the artery is 0.8 mm thick in average and is reduced to 0.5 mm above distinctive prominences [12], [412]. In more than 20% of cases, palpation results in a significant reduction of tissue resistance and in ca. 15% of cases, focal bony dehiscences are observed [12], [412], [414], [415]. In contrast, septa occur in the sphenoid sinus in 1% of cases, establishing a connection to the internal carotid a. [106].
The exact incidence rate of carotid injuries in paranasal sinus surgery is unknown. According to literature, carotid artery injuries occur with a rate of 0.3% in surgery of diffuse chronic rhinosinusitis [72]. For pituitary surgery, the rate is about 1% [101], [392], [416] and for rhinoneurosurgical procedures, the rate is approximately 0.3% to 0.9% of cases [70]. In the last mentioned operations, the risk increases considerably in revision surgery, after radiation therapy or if there is a tumor infiltration of the carotid [176].
In routine paranasal sinus surgery, the most frequent defect site of the carotid a. is shortly below the exit of the ophthalmic a. [417], sometimes with a preference regarding the left side [97]. In the scope of extensive rhinoneurosurgical procedures, further sources of bleeding, also from smaller branches of the carotid a., from the frontopolar arteries or from the ophthalmic a. must be considered [176]. – In very rare cases, even a laceration of the circle of Willis or a direct trauma of the anterior cerebral a. occurs, followed by life-threatening subarachnoid, intraparenchymal or intraventricular hemorrhage [102].
As a matter of principle, every ENT surgeon and every clinic should therefore have clear action plan at hand for the emergency of an internal carotid a. [97], [176].
For paranasal sinus surgery, the following measures are recommended in case of an injury of the cavernous internal carotid a.:

- Emergent insertion of a tight nasal packing as well as pharyngeal nasal packing, if applicable [176], [418], [419], [420], [421]. Several suctions must be kept available [95]. If nasal packing definitely cannot stop the bleeding, a compression of the internal carotid a. at the same side of the neck can be considered – with or without cervical incision [90], [95], [176], [418], [419]. However, with a good collateral circulation, the effect of this measure is not reliable and the manipulation may be time-consuming. Hence the compression (or even the ligature) of the ipsilateral carotid artery is

often referred to as being obsolete [420], [422]. Alternatively, it was recommended that an assistant should compress both carotids at the neck for no longer than 2 minutes, so that the surgeon gains time for the emergency treatment within the sphenoid sinus or for inserting nasal packing [97]. An even longer compression time was described (maximum 5 minutes), this duration, though, seems obsolete [423].

- Treatment of the blood loss by establishing several extensive intravenous lines; amongst others, emergency blood transfusions [418], [419].
- Maintenance of the circulation. Several articles strongly recommend normotension, not to endanger the cerebral circulation disproportionally [176], [181], [419]. Others recommend controlled hypotension [90], [95], [418].
- Emergency transportation of the patient to a neuroradiological ward with angiography. The aim is to identify and treat the lesion with immediate neuroradiological intervention [419], [422] (Figure 9). Due to the unstable situation of the patient, a balloon occlusion test is often neither possible nor reasonable [418], [422]. Under optimal organizational and structural conditions, however, an extra-intracranial bypass could be discussed after having performed a temporary balloon occlusion indicating relevant secondary EEG changes. [90], [181], [423], [424], [425].
- Notification and consultation of the neurosurgical specialist [419].

During emergent nasal packing, often too high pressure is created locally ("overpacking"), resulting in a mechanical compression of the injured carotid a. which might trigger severe consequences (reduced perfusion – ischemia) [426]. Additionally, the arterial injury can no longer be identified in the angiographic image, so that the otolaryngologist has to loosen the nasal packing and the angiography is repeated [95], [176], [418], [422]. Due to the former reason the otolaryngologist should be present during neuroradiological diagnostics and intervention [176].

In case of a very small lesion in the carotid vessel – provided appropriate local conditions, sufficient medical status of the patient and capabilities to pack the nose repeatedly – the surgeon should at first create an optimum access to the sphenoid sinus. The placement of an autologous muscle graft or allogenic material is recommended. This construction is fixed with fibrin glue and is tightened with packing. Alternatively, under favorable conditions, a specific vessel clip may be used [97], [426]. Occasional reports point out that such a supply was permanently successful preserving the arterial circulation [96]. However, after covering and 'gluing' the artery, a pseudoaneurysm may develop within a period of a couple of days to months (in average after three weeks) This may result in secondary, massive hemorrhage or in thromboembolism; an arterial occlusion, caused by the expanding aneurysm itself, was merely reported in a case report. For this reason an angiography is indicated postoperatively [95], [97], [389], [392], [407], [424], [427], [428], [429]. In case of an aneurysm secondary neuroradiological treatment is performed.

During a primary neuroradiological intervention after an accidental lesion of the carotid a., the vessel is mostly occluded by placing balloons proximal and distal or by placing 'coils'. There is an increasing number of reports about alternative treatment with 'stents' on a case-by-case basis, in which circulation is preserved. Here, specific complications, such as a vessel dissection, thrombosis, embolism or a vessel perforation have to be kept in mind. Balloons can get displaced and then may increase the risk of new bleeding. Postoperatively, patients with vessel stents receive anticoagulant drugs (Clopidogrel, ASS 100 mg) [95], [176], [417], [420], [422], [423], [428]. Within the first 24 hours after the neuroradiological intervention, a CCT control should be performed. Later on a control angiography should take place [176], [418]. The defect site in the sphenoid sinus should be covered secondarily, for example with fascia [95] (Figure 9).

Hemorrhages from the cavernous sinus are mostly much less demanding. Bleeding is interrupted by placing hemostatic material directly and applying smooth pressure. The material is inserted, covered with neuro-cotton wool and lightly pressed [176].

In principle, hemostasis during rhino-neurosurgical procedures as well as during sinus surgery is based upon bipolar coagulation, compression, nasal packing or ligature as well as upon the application of clips. However, in case of an exposed dura, a sufficient compression is not always possible and an external nasal packing additionally creates the risk of bleeding in intracranial direction. The surgical team ("two-surgeons-four-hands", "four-hands-two-minds") must be experienced. Immediately after the incidence, a second suction is introduced into the operating field and the endoscope is directed to a protected place; if applicable, equipped with a rinsing and suction device. In favorable individual cases, it might be possible to direct the jet of blood into the suction, to display small lacerations of the artery and to fuse and glue them by means of bipolar coagulation [176], [421], [430].

The use of an intraoperative Doppler is recommended as a measure of prevention [101], [416]. If an ordinary hemostasis is not successful, further nasal packing is applied and an emergency transfer of the patient to the neuroradiological ward is carried out [181].

The prognosis of an injury of the carotid a. in routine paranasal sinus surgery is determined by the risk of blood loss, a cerebral ischemia or an intracranial hematoma. An injury of the carotid a. in the cavernous segment may induce a carotid-cavernous fistula, resulting (even sometimes with delay), in a chemosis, a proptosis, orbital pain, diplopia and bruit (a humming sound within the skull due to high blood flow through the arteriovenous fistula). This condition is treated through neuroradiological intervention [89], [419], [431].

The mortality rate of relevant carotid lesions is about 17% [422], [432]. With a balloon occlusion, the global rate of complications is expected to be between 8–20% and in

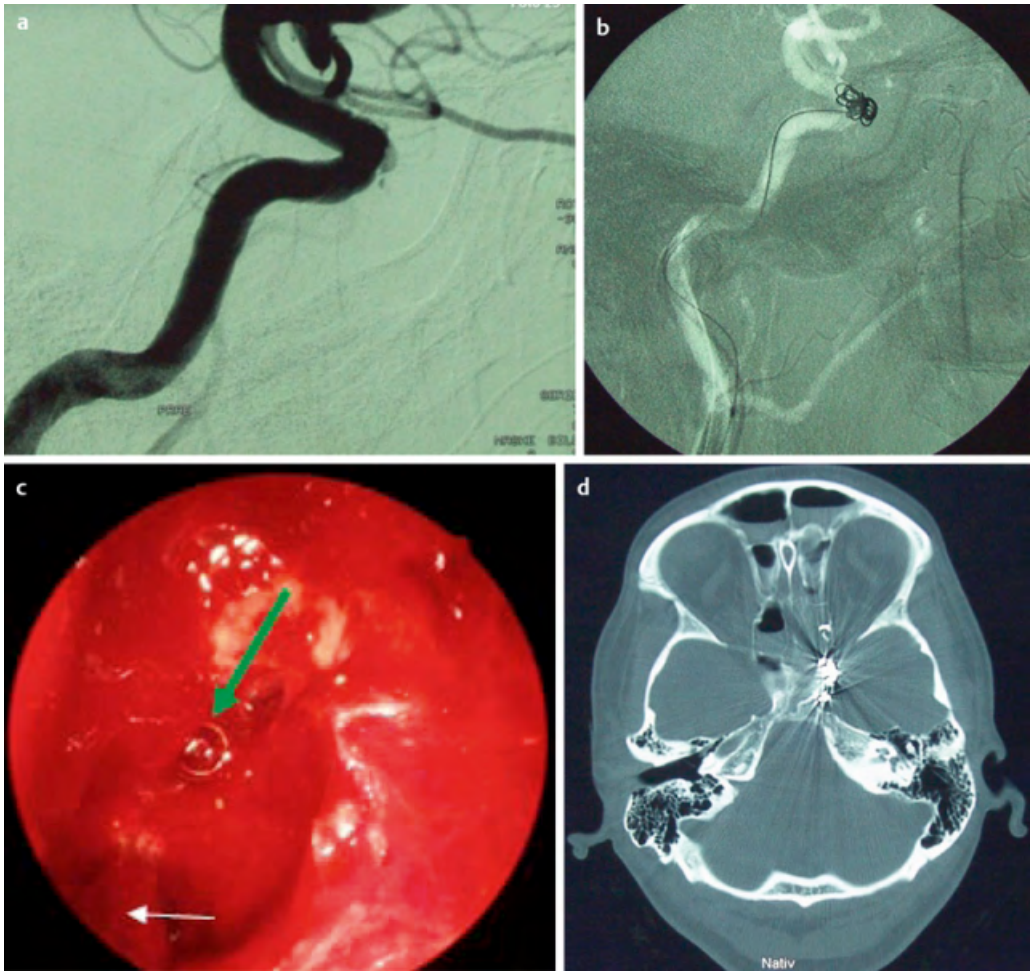

Figure 9: Laceration of the left-sided internal carotid a. as a complication of routine paranasal sinus surgery.
a. Angiogram of the internal carotid artery revealing a lesion located at the anterior bending (anterior 'genu').
b. Occlusion of the artery by coils.
c. Revision surgery of the respective sphenoid sinus revealing a partly exposed coil (green arrow: coil; white arrow: suction device).
d. Post-treatment axial CT scan depicting the coils.

cases of emergency procedures, a less favorable rate is to be assumed. Even after a successful occlusion-test complications following the definitive occlusion cannot be excluded [95], [97], [417], [420]. However, the test does have a relatively low rate of complications (3%) [433]. Immediate mortality rate in case of a bleeding from the pseudoaneurysm is about 30% [428].

5.3 Reduced vision, visual field defects

The optic n. often bulges into the superior-lateral wall of the sphenoid sinus. In this regard, very different frequencies are found in literature: 8–100% [12]. In 8% of cases, the canal of the optic n. protrudes into the sphenoid sinus by half of its diameter, whilst in 1% of cases, with a large lateral recess of the sphenoid sinus, i.e. a well pneumatized ant. clinoid process, it passes partially "freely" through the sphenoid sinus or through a posterior (sphenoethmoidal) ethmoidal cell [106], [434], [435]. The average bone thickness in the direction of the sphenoid sinus is 0.3 mm [412], however, in about three quarters of all cases, it is said to be 0.5 mm [436]. Bony dehiscences are observed in 4–8% (in case of distinct prominence: in 12%) [12], [412], [435].

Only a minority of sinus surgeons (6%) routinely initiates an ophthalmological consultation before sinus surgery [437]. Hence it is even more important to look out for a history of previous eye defects preoperatively. Perioperatively, this damage might only appear to deteriorate, e.g. as a decompensation of a functionally balanced anisometropia. As a consequence, unnecessary emergency measures might be taken, even medico-legal problems might arise [438].

Perioperative blindness in paranasal sinus surgery occurs in case of a direct injury of the nerve, a drug-induced interruption of local blood supply or a hematoma (in extremely rare cases also by an emphysema, see above) or in case of damaging the central nervous system, as, for instance through meningitis [76].

Direct mechanical damage to the optic nerve is only reported in exceptional individual cases [439], [440]. Here, during removal of the covering bone, the nerve can be damaged or destroyed in the cranial, lateral wall of the sphenoid sinus [441] or within the orbit [442]. In other

cases, injuries of the optic n. occurred following a lesion of the lamina papyracea by an accidental monopolar electrocoagulation of the nerve [83], [443]. A case report of a severe, direct injury of the eyeball across the lamina papyracea caused by an electrosurgical tube (without direct nerve damage) seems to be exceptional [444]. In case of an injury of the optic n., it is not rare that a combined defect with destruction of the eye muscles is found [440].

Compared with direct lesions, indirect injuries of the optic nerve caused by a retrobulbar hematoma occur more frequently [83], [439]. After mechanical destruction of the lamina papyracea, a hemorrhage in the dorsal orbital apex was triggered with an "orbital apex syndrome" and with indirect loss of vision with ophthalmoplegia [443].

Loss of vision as a complication of adrenaline-soaked (e.g. 1:5000) nasal packing placed into the wound area is known. Adrenaline resorption with consecutive spasm of the vessel network around the optic n. and an ischemic neuropathy was supposed to be the cause [152].

After every postoperatively noticed or supposed visual reduction, an ophthalmological emergency consultation should occur. Imaging (e.g. MRI) is strongly recommended [445]. After mechanical injury of the nerve, collateral damage has to be searched for, e.g. in the orbital apex or at the skull base [76].

If the optic n. is visibly cut through, there is no specific treatment. Even if nerve continuity is preserved, the immediate treatment of the perioperative visual reduction is problematic.

The regimen is individualized and is under ophthalmological guidance. If neurapraxia or a hematoma is suspected, a high dose corticosteroid treatment is followed out (e.g. intravenous dexamethasone 0.5–1 mg/bodyweight, alternatively an oral treatment with different scheme) [68]. The concept is aligned to the treatment of traumatic optic neuropathy – evidence of which, however, still remains a subject of debate [71]. Traumatology and neurology provide some experimental evidence to suggest that corticosteroids may also hinder the restitution of an optic nerve [334], [338], [441], [446], [447]. In specific cases, decompression of the nerve may be discussed – however, its benefit has not been proven yet [12], [76].

Under certain, adverse conditions, the symptoms of an ischemic optic-neuropathy may appear within the scope of sinus surgery, a disease of which little is known. In these rare cases, neither mechanical injury of the nerve has occurred nor has the lamina papyracea been damaged. Elderly patients with a history of chronic diseases, such as, diabetes/diabetic neuropathy, hypertension, heart or kidney diseases, are affected. Reduced vascular perfusion with ischemia develops, eventually on the basis of relative anemia and/or intraoperative hypotension. The exact pathogenesis is not yet known. The resulting loss of vision or visual field reduction emerges immediately or with a delay of several hours to days. MRI displays a vaguely defined and swollen optic n. with otherwise normal structures. A decompression of the optic nerve does not always seem appropriate. Administration of cortisone (e.g. 4 x 250 mg Methylprednisolone per day for 3 days) is subject of controversy. An immediate normalization of blood pressure and hemoglobin (by means of transfusions) seems essential [448]. A case report described residual ethmoidal cells revealing opacification. An emergency revision surgery was performed with decompression of the orbit and periorbital incisure. Additionally, high dose corticosteroid treatment (Prednisolone 1000 mg intravenously) and calculated antibiotic treatment was initiated. Within a period of 4 weeks the condition of the patient improved. In another case, the optic n. was also decompressed and the subsequent improvement occurred within 6 days. These two cases were interpreted as a consequence of an infectious impairment of the optic n. due to remaining inflamed posterior ethmoidal cells [445].

5.4 Diplopia

In endonasal surgery of the paranasal sinuses, an impairment of the medial rectus m. is likely to occur with an incidence of approximately 1/1000. In general, these injuries result of a fracture of the inferior lamina papyracea with perforation, destruction or incarceration of the muscle. The middle or posterior ethmoid is most at risk – as hardly any fat is situated between the muscle and the bony orbital wall [76], [104], [363], [449]. In rare cases, there is a particular risk due to a congenital or posttraumatic bulge of the lamina papyracea with or without direct embedding of parts of the muscle [107], [450]. Other eye muscles are distinctly less often injured intraoperatively: The inferior rectus muscle may be damaged in surgeries involving the maxillary sinus and the superior oblique (trochlea) muscle may be lacerated in extended endonasal frontal sinus surgery with a drill for instance. Injuries of the inferior oblique m. have also been described [71], [76], [104], [363], [451], [452], [453].

In the majority of cases, only one eye muscle is damaged, with a relevant orbital hematoma developing additionally in one quarter of patients. Occasionally, however, severe combined damage affecting three muscles, for example, has been observed with additional bleeding, retinal damage or lesions of the optic n. or of the oculomotor n. [104], [453], [454].

Generally 5 typical causes for a postoperative motility disorder of the eye may be distinguished:

1. Partial or complete transection of the muscle.
2. Contusion with hematoma of the muscle tissue.
3. Impairment of the oculomotor n., e.g. at the point of transition between the middle and the dorsal third of the medial rectus muscle.
4. Prolapse and incarceration of muscle parts and/ or fat into a defect of the orbital wall.
5. Destruction of intraorbital fascia with irregular scarring ("fat adherence syndrome") [363], [453], [455], [456].

Very often (50%), eye muscle damage is not noticed intraoperatively by the surgeon [453]. Muscle tissue that is

surprisingly evident in routine histologic specimens (Figure 10) might be problematic for medico-legal reasons. In general, periorbital damage should be detectable intraoperatively by means of the bulbus pressure test [453]. If, beyond that, intraoperatively suspected eye muscle damage occurs, an ophthalmologist should be notified and consulted immediately [113], [363].

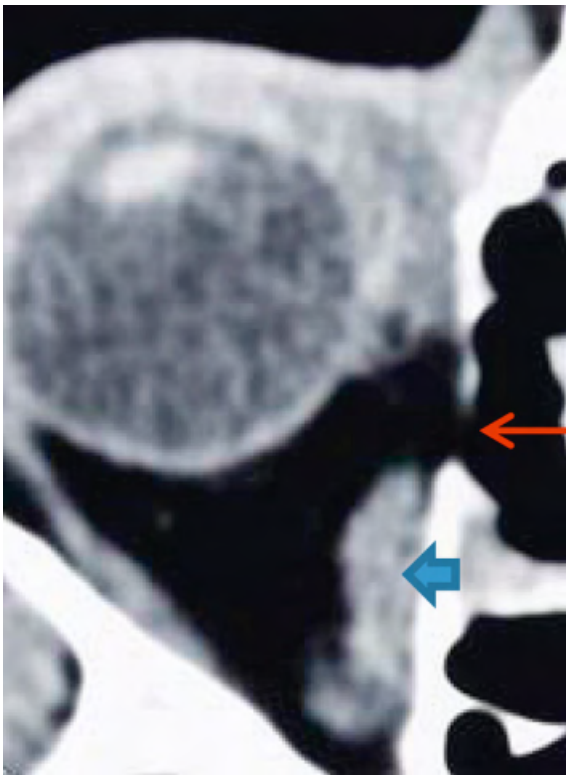

Figure 10: Postoperative axial CT-scan of the left side showing destruction of the lamina papyracea (red arrow) and also complete transsection of the medial rectus muscle in the course of routine paranasal sinus surgery (blue arrow: retracted stump of the muscle).

With few exceptions, diplopia appears immediately after the operation as a result of the injury [453]. All relevant findings should be submitted immediately for evaluation by means of imaging. The clarification of an eye muscle injury with displacement or incarceration or the display of a contraction of the dorsal muscle parts most likely succeeds after complete sectioning with a contrast-enhanced MRI; evaluation is done in three planes. At best, multipositional MR imaging might allow to draw conclusions about the contractility of the muscles. In the further course, a repeated MRI may also document stages of repair, as swelling of muscle tissue is followed by atrophy. Other sources recommend a CT as initial diagnostic measure for all orbital complications, as differentiated analysis of the injury is hindered initially through hematomas and accompanying edema [71], [76], [334], [363], [455], [457], [458]. Generally, the findings of CT and MRI correlate well with the ophthalmological functional examinations [449].

Regarding treatment of acute, iatrogenic eye muscle damage, an early surgical intervention should be performed within 1 to 2 weeks, if a muscle was completely intersected or if an incarceration of tissue or a skewering of bone fragments into the muscle is suspected clinically or via imaging [71], [104], [453], [459]. Surgery is performed as soon as the eye's degree of swelling permits it [460]. A reconstruction of the medial rectus m. may be successful if the remaining posterior segment is functionally intact and longer than 20 mm. In case of excessive destruction, a muscle transposition might be sought; alternatives are graft interpositions or specific suturing techniques [363], [453], [458], [461]. Manifest eye movement disorders can also be caused without direct lesion of the eye muscle in case of destruction of the orbital fascia, resulting in irregular scars ("fat adherence syndrome") [71]. In order to exclude corresponding damage in revision surgery, aggressive orbital dissections should be avoided during further surgical therapy [461]. Reconstruction of the medial orbital wall directed to the ethmoidal cavity, using alloplastic material, often cannot prevent a secondary, bothering scar formation [358], [462]. In individual cases, an immediate cortisone therapy is applied in an effort to minimize the inflammatory response of the orbital tissue [71].

In case of partial damage, literature recommends both an observant and an active approach [459]. Contractures of the antagonists of damaged muscles can already be observed after 2 weeks. Especially in cases of severe injuries, revision surgery performed before fibrosis begins to occur, i.e. within two to three weeks, is easier, from a technical point of view, and will probably be more successful. In contrast, spontaneous improvements were observed within a period of three months after slighter neuronal, vascular or direct muscle damage [71], [363], [455]. By means of botulinum toxin injections into the antagonists of damaged muscles, diplopic images can be improved faster, a secondary contracture of the antagonist is prevented and the traction force applied to the damaged muscle is reduced. For reasons which are not fully known, the injection can make a positive contribution to a long-term functional alignment of the extraocular muscles [76], [363], [458], [459]. In appropriate cases, the injection is combined with a surgical muscle reconstruction [455], [456].

Other forms of impairment are treated conservatively in the beginning [459]. If the muscle is only affected by bruising, neural or vascular damages, it may be justified to wait for 3–12 months [71], [133], [453]. Two to three months after a damage caused to the medial rectus m., strabismus surgery is indicated [116]. In two thirds of cases, several operations will be necessary [358], [458]. In the majority of cases after an ophthalmic surgery, ocular functional deficits remain, although most of the patients (90%) are satisfied with their eye sight function in daily life [451], [455], [458].

Extremely severe damages of the ocular muscles and the orbital tissue have been reported after the use of the microdebrider [71], [76], [185], [453]. The medial rectus m. is most frequently affected [17]. The muscle is sucked into the rotary tip of the debrider and is in danger of being

quickly destroyed through the 'shaving action'. This may also occur without any prominent orbital injury. Often the surgeon is not even aware of the damage. The perforation in the lamina papyracea may be difficult to identify, even in postoperative imaging [17], [71], [363], [449], [459]. In other cases, motility limitations can be distinctly higher than the damage seen at imaging. Here, diffuse deformities, known as "fat adherence symptom" (see above) are assumed to evolve, together with a 'de-compartmentalization' of the extraconal fat tissue, followed by adhesions between the periorbit, fat, sclera and extraocular muscles [17]. After injuries caused by the shaver, chances to reconstruct the medial rectus muscle successfully are rather limited [340].

In rhino-neurosurgical operations, especially in the parasellar and suprasellar region, in the area of the cavernous sinus or the clivus, thermal injuries or transections may lead to injuries of the abducens n. or the oculomotor n.. Frequently the oculomotor nerve recovers postoperatively from damages as long as the continuity of the nerve is preserved [102].

Pupil differences and changes in pupil size during surgical procedure

For various reasons, a mydriasis can occur during paranasal sinus surgery:

1. When decongestives are applied into the nose, sympathomimetic liquid from the soaked cotton wool may run out of the nostril. With the patient being in a supine position, the liquid runs paranasally into the medial corner of the eye [463], [464]. The resulting pupil dilation is usually much stronger than, e.g. in case of an afferent defect [122].
2. If similar substances are injected into the nasal mucosa, retrograde transport via the lacrymal ducts has been reported in rare cases [465].
3. Mydriasis can occur in case of a threatening intraoperative complications (intraorbital hematoma, injury of orbital structures, increased endocranial pressure, e.g. when endocranial hematoma occurs) [464]. Injuries of the optic n. don't necessarily lead to a dilation of the pupil – preserved pupillary reflexes provided, a corresponding unilateral mydriasis would only be seen if the opposite eye had continuously remained covered.
4. Mydriasis can be an accompanying symptom of an eye disorder which has not been noticed preoperatively [464].
5. In individual cases, a temporary paresis of the nasociliary n. and its connection to the oculomotor n., due to topical intranasal local anesthetics, has been postulated. Other incidences of mydriasis remained speculative [464], [466].

In individual cases, pupil differences without pathological substrate can occur during anesthesia. In a small percentage of the population, an observable anisocoria (i.e. a difference in pupils of 1 mm or more) exists in full health from the beginning [467].

Under general anesthesia, the light reflex cannot be judged. Therapy with opiates (e.g. Fentanyl) leads to miosis which, however, can decrease, due to an intraoperative sympathicus stimulus. Individual factors affect the size of the pupils during extubation; in some cases even, side differences, lasting about 20 minutes may occur during this process. Only after this specific time frame, a reliable test of the pupil reaction and a correct test to compare the pupils ("swinging flashlight test") is attainable [468], [469].

Based on the described circumstances, a number of recommended precautions can be deduced:

a. Before the operation, the surgeon should gain certainty about the patient's previous eye diseases.

b. Before the surgeon begins to operate the "initial position"(proptosis, pupil width) should be analyzed briefly.

c. During the operation, the eyes should always remain free from textile covering. The scrub nurse should get used to control the eye from the outside while surgery continues in the inside of the nose. Hence complications are indicated by a passive concurrent movement of the globe and can be noticed early.

d. As a matter of principle, the surgeon should be familiar with examination of an afferent pupillary defect, for instance by means of the pupil comparison test ("swinging flashlight test") [345], [468], [470].

Generally, a serious acute narrow angle glaucoma can be triggered by sympathomimetica in predisposed patients [463].

Furthermore a special case of a postoperative mydriasis after introducing a drug releasing placeholder (Stratus®) into the ethmoid bone was reported. The placeholder had perforated the dorsal orbital apex and caused permanent changes in the pupils. Even an emergency revision surgery with removal of the foreign material did not result in an improvement [471].

5.5 Enophthalmos

Paranasal sinus surgery, in the broader sense, with extensive removal of the mucosa can cause a scarred distortion of the entire ethmoidal cavity in adults, combined with a medialization of the lamina papyracea. These transformations can be identified by postoperative imaging and may be associated with a subclinical enophthalmos [268], [472].

In children, after paranasal sinus surgery, a postoperative hypoplasia of the maxillary sinus with no external changes was described radiologically [473]. After unilateral ethmoidectomy in a pediatric case of an imminent orbital complication, merely a minimal facial asymmetry was visible in the postoperative CT [474]. Another case report presents a scarred insufficiency of the maxillary ostium with an involution of the equal-sided maxillary sinus and a slight, but noticeable flattening of the child's face [475]. A similar case of a postoperative scarred stenosis of the maxillary ostium and a secondary maxillary sinus ate-

lectasis with postoperative enophthalmos (3 mm) was also observed in an adult patient [476].
Studies in traumatology revealed that even with minor injuries (0.55 cm^2) of the medial orbital wall, a subclinical enophthalmos might be expected [352]. Individual cases are reported which tend to concur with this observation, describing a postoperative enophthalmos after injury of the medial orbital wall and the medial rectus m. [116].

5.6 Lacrimal duct injury, complications of endonasal dacryocystorhinostomy

Surgeons performing a paranasal sinus operation should be familiar with position and size of the efferent lacrimal ducts: The lacrimal sac is approximately 7 mm wide and extends 4–8 mm cranially beyond the anterior attachment ("axilla") of the middle turbinate [477], [478]. In half of the cases, the lacrimal sac is covered by parts of the agger nasi and in almost two thirds of all cases, the uncinate process is overlapping the lacrimal sac [479]. The distance between the free edge of the uncinated process and the anterior edge of the lacrimal sac is 5 mm (0–9 mm) [477], for the maxillary sinus ostium the distance is approximately 4 mm (0.5–18 mm) [390], [477], [480]. The lacrimal bone is very fragile, compared to the frontal process of the anterior maxilla. In average, it is only 100 µ thick and in 20% of all cases it has focal dehiscences [480].

Lacrimal duct injuries in paranasal sinus surgery

Epiphora develops in about 0.1 to 1.7 % of cases after sinus surgery [71], [98], [480], [481]. Inapparent injuries of the lacrimal ducts are described in 3% of cases (in individual cases up to 15%). Under favorable circumstances, such cases correlate with an unintended dacryocystorhinostomy [480], [481], [482] (Figure 11). An injury mostly occurs during infundibulotomy (uncinectomy), during surgery on the anterior frontal recess or during maxillary sinus fenestration in the anterior middle nasal passage – in the latter, particularly during the use of the backward cutting punch [71], [288]. Injuries occurring during a fenestration in the inferior nasal meatus should have become rare [91].
During the course of a routine sinus operation, frequently parts of the lacrimal bone or parts of the frontal process of the maxilla are removed in an undirected manner, without any direct malfunctions resulting. In right handed surgeons, the left side is supposed to be affected more frequently [481]. Pressure applied on the medial angle of the eye under endonasal endoscopic control can help to identify the tissue of the lacrimal sac and to prevent it from damaging during further manipulations [122].
After a relevant lesion of the efferent major tear ducts, the symptoms appear directly after the operation or with a delay of 2-3 weeks. Postoperative epiphora can subside spontaneously if the inflammatory reaction caused by the surgery has decreased [68], [480].

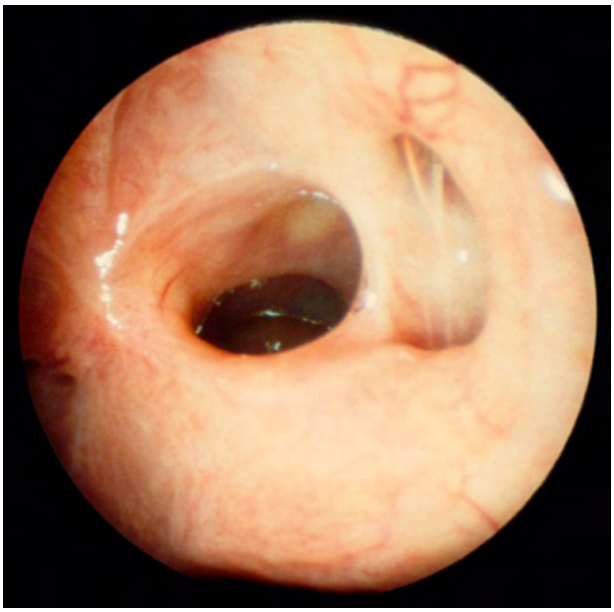

Figure 11: Endoscopic aspect of the left-sided nasal cavity with a middle meatal antrostomy (70° angled optical device: some crusts are shown inside the maxillary sinus). Anterior to the neo-ostium the nasolacrimal duct is shown, having been subjected to "unintended dacryocystorhinostomy". This event had no functional sequel.

Each patient with postoperative epiphora should be examined thoroughly. In case of doubt, an ophthalmologist should be consulted. There are often no direct consequences and the patient is kept under observation. If after one week, epiphora is still present, advanced diagnostic measures are indicated. First conclusions can be drawn after performance of a Schirmer test, rinsing or a fluorescein test ("Jones I and Jones II Test"). In special cases, a CT with dacryocystogram can produce additional information. The treatment of symptomatic iatrogenic lacrimal duct stenosis in general is dacryocystorhinostomy [98], [288], [480].

Complications of endonasal dacryocystorhinostomy

The effectiveness of endonasal dacryocystorhinostomy is undisputed, experienced surgeons have a success rate of more than 85% [483], [484].
Success of the operation may be limited due to an insufficient position or size of the lacrimal duct fenestration, combined with portions of bone or remains of the medial lacrimal sac left behind. During the first 4 weeks after the operation, the intranasal neo-ostium is shrinking regularly and then remains stable. The result of the surgery is affected by an excessive scar formation or enhanced granulations, for instance after extensive resection of mucosa. Further causes are synechiae, e.g. with the middle nasal turbinate (6–22%) or with a deviated nasal septum (5%). Irregular scars can trigger frontal sinusitis. In other cases, a "blind sac" of the efferent lacrimal ducts ("lacrimal sump syndrome") is formed, combined with an accumulation of tear fluid and consecutive, repeated epiphora or recurrent dacryocystitis. Mechanical

rinsing of the tear ducts from outside is retained in these cases [484], [485], [486], [487], [488].
Intra- and perioperatively, orbital fat prolapses (up to 10% are reported); postoperative bleeding (1%), eyelid hematomas (6%) or an emphysema of the skin may occur. If an increased amount of bone is exposed, postoperative pain can develop (3%). In 2% of cases, a generally delayed healing is expected, and a temporary postoperative kakosmia is stated in 9% of cases. Skin injury in the medial corner of the eye should be extremely rare, additionally, retrobulbar hematomas, eye muscle injury, burns at the nostril, stenosis of the canaliculi or conjunctival fistulas may occur [485]. The same applies for a case report of a cerebrospinal fluid fistula during the mechanical reclination of a deviated nasal septum for the purpose of exposing the lacrimal ducts [489].
If splints for lacrimal ducts (stents) are applied intraoperatively, this may result in a conjunctival irritation (for example, the formation of a loop), secondary injury of the lacrimal punctum or a premature loss of the splinting [486]. In individual cases, problems arise during or after removal of the splint, e.g. due to scarring.
In case of doubt, an inefficient dacryocystorhinostomy should be followed by endonasal revision surgery. Depending on their location, synechiae can be treated by a reduction of the tip of the medial turbinate or even correction of the nasal septum [485]. **The "lacrimal sump syndrome" c**an also be corrected easily [488]. Patients should be reminded that postoperatively, even after a successful surgery, air might get constantly blown into the medial corner of the eye whilst blowing their noses.

5.7 Skull base injury, tension pneumocephalus, encephalocele

A pneumocephalus is the presence of gas (air) in the cranial cavity. In most cases, it is based on a communication between extracranial and intracranial space. The air can be present in epidural, subdural, subarachnoid, intraventricular or intracerebral spaces. It might be tolerated well in one case, yet in other cases it could be responsible for dangerous findings and symptoms [490]. However, air entrapment is not obligatory in every skull base injury (Figure 12).
A minor defect of the dura may act like a "valve". As a consequence, air is accumulated intracranially and gets 'trapped' during intermittently increased pressure in the upper respiratory tract (e.g. during sneezing or during mask respiration). A second pathomechanism is air being sucked in, after cerebrospinal fluid has been discharged. As a result intracranial pressure increases gradually and a tension pneumocephalus develops. Symptoms are an altered state of consciousness, restlessness, headache, nausea, vomiting, eye motility disorders, ataxia, and spasms. If the underlying process is not interrupted, a pressure effect in the interhemispheric fissure (close to the motor cortex) might induce a diplegia. Additionally rupture of bridging veins may cause subdural hematomas and finally cardiac arrest [251], [491], [492], [493]. In individual cases, the neurological symptoms may have a latent period of several days [493].

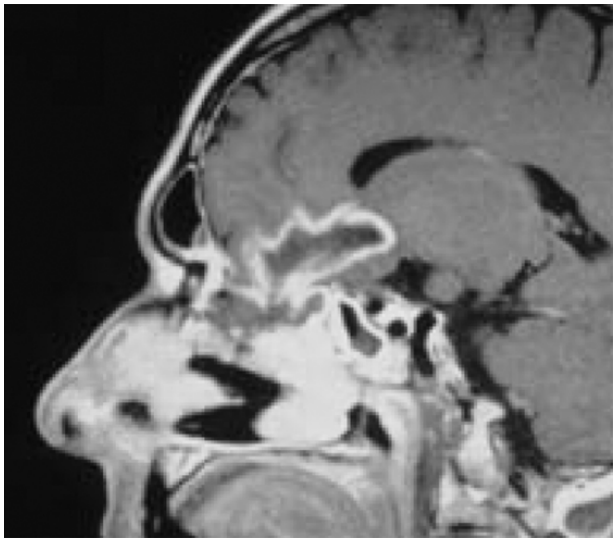

Figure 12: Postoperative sagittal MRT tomography revealing signs of a recent anterior skull base perforation by a.-p. directed force.

In axial plane imaging, the typical "Mount Fuji" sign is formed, due to the compression with tip-like protrusion of the frontal poles of the brain [491], [494], [495] (Figure 13). The mass effect of air does not always have to be spectacular and is not always bilateral [493]. After the diagnosis has been confirmed in the emergency CT scan, immediate neurosurgical decompression has to take place, e.g. by trepanation or performing a puncture, with simultaneous closure of the skull base defect [491], [496].

Figure 13: Axial CT-scan revealing tension pneumocephalus caused by a skull base perforation during routine paranasal sinus surgery (note: "Mount Fuji sign" of the anterior cerebral poles).

Intracerebral tension pneumocephelus may occur in rare cases. In those few cases, ineffective defect closure at the skull base was followed by a progressive accumulation of air subcortically in the frontal brain. Instead of the "Mount Fuji" sign, radiologically a frontal, expansive, intraparenchymal air bubble was identified [497], [498]. The pathophysiology and therapy are consistent with the usual tension pneumocephalus; the intracerebral air bubble may be released by means of a puncture. The same applies for extremely rare cases of an intraventricular tension pneumocephalus after paranasal sinus surgery. The specific cause for this intraventricular accumulation of air is not yet known [490], [499].

5.8 Meningitis, brain abscess, intracranial haemorrhage

Meningitis, brain abscess

Postoperative meningitis is rare, although it represents the most frequent intracranial complication in paranasal sinus surgery. It spreads through dural lesions, perivascular or vascular paths or even via perineural spaces of the olfactory fibers [90]. In rare individual cases only, an intracranial abscess or septic thrombosis of the cavernous sinus can be classified as a true complication of paranasal sinus surgery [500]. More frequently, they develop on the basis of a preexisting inflammation of the mucosa in the paranasal sinuses [90].

In rhino-neurosurgical procedures, the postoperative rate of meningitis is about 1–3% [102], [237], [248], [501], [502]. Risk factors are: a history of craniotomy or endonasal surgery, surgery with high degree of difficulty, preexisting external ventricular drainage or ventriculoperitoneal shunt, cerebrospinal fluid fistula postoperatively. On the contrary earlier irradiation, the patient's age, pathology, or the duration of a lumbar drainage do not affect the rate of meningitis. The incidence is within the same range as in conventional intracranial surgery or in pituitary surgery [101], [501], [502], [503], [504], [505].

Meningitis may occur with a delay of e.g. one week after routine surgery [197]. When suspecting meningitis a CT scan has to be ordered immediately followed by a lumbar puncture. Symptoms or findings are e.g. fever, laboratory diagnostics indicating major inflammation, headache and neck pain, as well as an impaired consciousness. The patient should be monitored intensively and an active cerebrospinal fluid fistula needs to be detected [182].

Rarely (0.9%), a frontal brain abscess was reported after rhino-neurosurgical surgery. Mainly responsible are staph. aureus, gram negative bacteria or polymicrobial colonization. Acute sinusitis is more frequent postoperatively, for instance in the area of the surgical corridor of the sphenoid bone. Here, revision surgery including a microbial probe is recommendable [102], [248].

Most studies imply that prophylactic administration of antibiotics does not reduce the risk of meningitis or brain abscess in skull base surgery [503]. In case of antibiotic prophylaxis, it should be applied half an hour before the first incision; in uncomplicated rhino-neurosurgical operations, it may be restricted to 24–48 h [504], [506], [507], [508]. Other rhinological references recommend antibiotic treatment 3 days preoperatively for 7–14 days – depending on the duration of nasal packing [509], [510], [511], [512]. Preoperative microbial swabs are inappropriate for calculated antibiotic treatment [513], [514]. In routine cases, cefazolin, ceftazidim or amoxicillin/clavulanic acid are recommended as monotherapy. When there is an intolerance, vancomycin or clindamycin are also recommended [504], [505], [506], [510], [515], [516].

Subdural hematoma, cerebral hemorrhage, ischemia

Uncomplicated cerebrospinal fluid fistulas have been mentioned in 4.3. They may lead to severe complications, e.g. by means of suction of tissue into the skull base defect, causing bleeding of intradural or subarachnoid vessels or from branches of the anterior cerebral a. or the anterior ethmoidal a. Additionally this may result in an epidural, subdural or intracerebral haematoma, a localized cerebral infarction or even a traumatic aneurysm [90], [91], [517]. Instantaneous fatal bleeding can possibly occur due to an injury of the internal carotid a., the anterior cerebral a. or the anterior communicating a..Serious damage can also be triggered by induced arterial spasms [90]. The defect at the skull base can cause a secondary herniation of brain tissue [518]. An iatrogenic encephalocele can develop slowly within months and might only become apparent though meningitis [200].

After extensive reconstruction of the frontobasal region and after a large amount of CSF has been discharged, intracranial pressure may drop, which in turn can result in displacement of the graft or tension on the bridging veins causing a subdural haematoma. For these reasons, a lumbar drainage is contraindicated in case of a prominent pneumocephalus. After extensive surgical procedures, a CT control must be performed on the first or second postoperative day [251].

5.9 Direct mechanical cerebral trauma, severe combined injuries

Fatal, partially lethal complications with mechanical destruction of cerebral tissue are limited to extremely rare cases in routine paranasal sinus surgery. Corresponding reports are mostly from earlier decades [349], [519]. In individual cases, severe combined injuries of brain and vessels can occur, e.g. with a traumatic aneurysm of the anterior cerebral a. [198]. Smaller case series report a clustering of corresponding incidents, partly on the right hand side and partly on the left hand side [520], [521].

Intraoperatively, the surgeon is mostly not aware of life-threatening brain damage, often only a "striking bleeding tendency" is registered (Figure 14). The removal of "indistinct tissue" for histological analysis, which then turns out to be orthotopic cerebral tissue, is tragic. The same

applies for the accidental discovery of cerebral tissue during routine histology. Serious injury patterns have also been induced accidentally with the shaver.

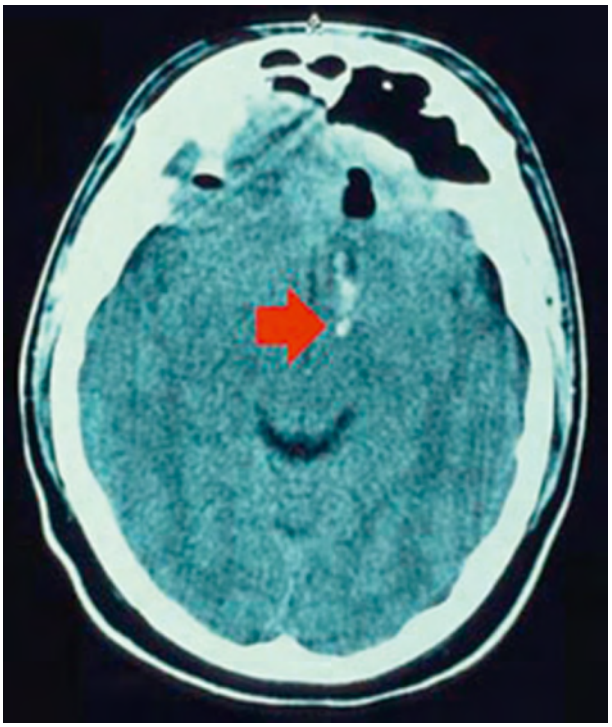

Figure 14: Postoperative axial CT-scan following seemingly uneventful routine paranasal sinus surgery. Obviously a major skull base perforation has happened and a piece of bone (red arrow) was transferred into the remote brain tissue. The surgeon noticed an increased intraoperative blood loss only.

Postoperatively, patients show suspicious symptoms such as lasting clouding of consciousness, disorientation or somnolence, and, in addition, focal neurological signs, for instance myoclonia or headaches in recovery phase. In other cases, postoperative bleeding with liquorrhea occurs [197], [198], [522], [523], [524], [525]. In rare cases, after a supposedly normal operation and healing process, only atypical or strikingly intense headaches were observed [526].

In case of doubt, a cCT or an MRI should be ordered immediately, in order to determine the existence and extent of the damage and to exclude a pneumocephalus or bleeding requiring therapy. The MRI displays more subtle parenchymal damage and also the chronological sequence of a resorption of hemorrhages [133], [526]. In an acute case, emergency neurosurgical consultation has to be performed directly after imaging. After injury of the frontal brain, a permanent “frontal brain syndrome” can occur, with personality changes (loss of motivation, apathy), behavioral and memory disorders [90], [523].

In medico-legal assessment of cerebral trauma during routine sinus surgery, the discussion erratically accentuates regarding surgical negligence, if cerebral tissue is evident in routine histology and if the patient does not display anatomical or constitutional abnormalities. Another topic of discussion is the putative direct damage of brain tissue by instruments. The intracerebral injury pattern as revealed by imaging might provide guiding hints: a vertically positioned bleeding into the cerebral tissue, located ’on top’ of the skull base, is evident for direct and proceeding penetration of the internal brain. In contrast, an unknowingly triggered subarachnoid hemorrhage in case of a superficial injury of the skull base does not unambiguously indicate negligence, even if severe secondary neurological damages occur [527].

In rhino-neurosurgery, the continuously increasing complexity of surgical procedures naturally also induces a higher number of differentiated neurological complications. In positive case series, temporary neurological deficiencies are reported in 2.5% of patients and permanent damage occurs in ca. 2% [70]. In the area of the pituitary, e.g. diabetes insipidus or panhypopituitarism can develop after a mechanical injury of the gland or its supplying vessels [102], [182]. Besides vessel damage, amongst others, lesions of the cranial nerves II, III, V, VI, IX, X, XII were observed. The rate of severe (intra- or perioperative) complications including infections and organ failure was 2.6%, the mortality rate was 0.9%. Here, patients older than 60 years, patient with complex surgeries and patients with postoperative CSF fistula were particularly affected [70].

5.10 Toxic shock syndrome

“Toxic shock syndrome” (TTS) results from an infection with toxin-producing strains of staph. aureus, and possibly also by streptococci. The primary infection often is not very distinctive. However, released toxins act as superantigens and quickly generate a progressive disease with a disease pattern similar to sepsis. In otorhinolaryngology the transition from the nasal colonization to infection by staph. aureus is also as crucial as the individual potential of microbes in the production of toxins [528].

In a large number of cases the initial source is nasal packing. The incidence of TSS in nasal surgery is indicated with 16/100,000. Rare cases have occurred in connection with the use of septum foils, due to a special postoperative formation of crusts or following chronic or acute rhinosinusitis without any abnormalities [528], [529], [530], [531]. In a single case a TTS with primary, life-threatening phlegmonous gastritis occurring shortly after sinus surgery was reported [532]. Individual cases of illness may develop with a delay, i.e. days to weeks after sinus surgery [76], [531]. A secure protection by perioperative prophylactic antibiotics or antibacterial ointments does not exist [533]. The resulting sepsis develops rapidly, e.g. in the course of hours, with sudden fever, hypotension, and a progressive multi-organ failure.

The first therapeutic goal is eliminating the bacterial source. This happens e.g. by removing nasal packing immediately and by eliminating retentions, secretions and debris by means of endoscopic assistance followed by rinsing. Blood cultures are taken. Therapy is based on substituting fluid, adjusting the acid-base balance and electrolytes as well as monitoring renal function. Regarding combined antibiotic therapy, recommendations should

be taken into consideration where certain substances have shown to lead to a reduced toxin release (e.g., clindamycin), in combination with e.g. vancomycin. Further treatment, if necessary, is performed according to guidelines for bacterial sepsis. In comparison prognosis of diseased cases in otorhinolaryngology is good, though globally a mortality rate of 4–22% is specified [528], [531].
Criteria of toxic shock syndrome TTS (from [528]):

1. Fever ≥38.9°C
2. Rash: diffuse or macular, erythroderma
3. Skin desquamation, especially on palms and soles, 1–2 weeks after outbreak of the disease
4. Hypotension - systolic blood pressure <90 mmHg in adults
5. Multi-organ involvement - three or more of the following symptoms or findings:
   a. Gastrointestinal: vomiting or diarrhea at outbreak
   b. Muscular: severe myalgia or increased creatine phosphokinase
   c. Mucosa: vaginal, oropharyngeal, or conjunctival hyperaemia
   d. Renal: urea nitrogen or creatinine above twice the standard value
   e. Liver: serum bilirubin above twice the standard value
   f. Haematology: thrombocytes <100×109 L-1
   g. CNS: disorientation, or disturbance of consciousness without focal neurologic signs

Negative results:

- negative blood culture, negative microbial probe of the throat and negative bacterial CSF diagnostics (blood culture may be positive for S. aureus)
- negative test for leptospirosis, measles, rickettsiosis

Likely TTS: 5 criteria are met.
TTS confirmed: 6 criteria are met.

5.11 Anosmia

The topography of the olfactory mucosa and postoperative hyposmia was noted in chapter 4.5. The rate of postoperative anosmia as a complication of sinus surgery is about 0.07% to 1% [72], [534]. In rhino-neurosurgical surgery, anosmia may be an inevitable consequence due to tumour resection e.g. in the olfactory fossa – in other cases it results from generous resection of turbinate or mucosa [182]. Altogether, the rate of postoperative anosmia is approximately 2% [326], [393].
In the U.S., postoperative anosmia is one of the most frequent reasons for a legal dispute. Hence, detailed preoperative informational conversation is useful, but currently still not common [524], [535].

6 Structural quality

Instruments

Adequate instrumentation is fundamental in endonasal endoscopic sinus surgery. The hospital manager has the duty to equip the surgeon with appropriate instruments [536]. In the present context these necessarily include optical aids such as endoscopes in different angles. Requirements are significantly enhanced for Rhino-Neurosurgery [181]. Recently video system standards have improved significantly (HDTV). In light of this, previous studies need an update in regard of technical standards [537]. In contrast, it must be noted that endonasal procedures using headlights are still considered as equal [264], [538]. When equipping the OR with video systems ergonomic aspects have to be taken into account – about ¾ of sinus surgeons complain about OP-related symptoms, especially in the shoulder and neck area about the length of time. These kind of problems occur especially after lengthy rhino-neurosurgeries [539].
For endonasal haemostasis an equipment for bipolar coagulation is necessary. Monopolar instruments are generally appropriate, but its use in the sphenoid sinus, the base of the skull and intracranially (rhino-neurosurgery) is not recommended [181].
After using the shaver, faster healing with a lower rate of interfering crusts, synechia or scarring displacements of the middle turbinate was reported in literature [274]. From other sides, no corresponding benefits have been described [540], [541]. The particular risk of shavers has been pointed out in detail [340], [542]. There is no valid data on the absolute rate of complications compared to conventional instruments. However, the dimension of the damage caused by accidents with a shaver is often increased (see above). At the skull base, the surgeon's view is limited due to the relatively wide tip of the instrument – generally tactile feedback is lacking [543].
For the overall result, true cutting micro-instruments neither provide specific benefits [544], [545]. They lead to a reduced rate of postoperative synechiae- but they have no effect on the subjective and objective surgical outcome [546].
Routine use of endoscopes with "cold light sources" may cause burns: the rigid (4 mm diameter) endoscopes heat up at the top with temperatures up to 60°C. The distal end of light transmission cables may heat up to 200°C within one minute only [547]. Fires of the covers or patient's skin burns are feared. Similar problems were reported due to damaged isolation of electrosurgical devices [65].
Robot systems in sinus surgery are in their early stages of development [548], their use in routine surgery is in remote future.

Balloon dilatation

Generally the balloon dilatation of sinus ostia may be considered as a safe surgical procedure [549], [550],

[551]. The most common problem in dealing with these systems is that the ostium or channel is impassable for the guide wire. This may be caused by scars, anatomical irregularity or local polyp growth. As a result, a complication of inadvertent dilation of the secondary maxillary ostium, a submucosal passage of the guide wire and balloon or an injury of the orbit may occur [288], [552]. After dilatation about 8% of the patients may develop sinusitis, which responds usually well to antibiotic treatment [553]. The dilatation of the frontal sinus ostium might cause local microfractures, which in turn may lead to sinusitis relapse via local inflammation respectively osteitis [554]. Literature reports an incidence of failed dilatations at about 6–19%. In a single case, a local lymphoma was overlooked during dilatation [555].
Material flaws (e.g. rupture or loss of pressure of the balloon, a bent probe, an obstructed guide catheter) were observed in 3% of dilatations [553]. In a single case, a septal hematoma occurred during dilation of the sphenoid ostium – the patient though was under a permanent warfarin therapy due to cardiac disease [556]. In addition, one case report deals with a lesion of the skull base during dilatation of the frontal sinus, probably caused by the rigid guide catheter [557].

Navigation systems

In a survey published in 2006 in the United States only 31% of practicing otolaryngologists declared navigation systems as standard in sinus surgery. This image has changed: In the years 2005–2010 the rate of otorhinolaryngologists with access to a navigation system has increased to approximately 95%. The number of navigation-assisted surgeries has increased by 56% between 2007 and 2009. The numbers reflect an increase of navigation use in routine surgery [11], [13], [558].
In anatomical preparation, inexperienced surgeons had less complications when using the navigation device. Identification of landmarks is more accurate, though surgery takes longer time [559]. Statistical evidence for a reduced rate of complications in clinic, however, is almost impossible - under normal conditions several thousand subjects would be required in each cohort [15], [560], [561]. A tendency in favour of lesser complications when using navigation has been observed, especially less injuries of the orbital cavity and CSF fistulas [15], [562], [563], [564]. Surgeries were less frequently interrupted due to bleedings, although the total blood loss in the use of navigation was higher [565]. Other authors did not notice any effect on intraoperative complications or the (subjective or objective) result of the operation [15], [563], [564], [566], [567], [568], [569]. Complications were also caused by navigation- in some cases e.g. specifically as a result of a calibration error [76], [570]. In regard of these facts, the surgeon must be advised to control the system repeatedly during the operation by means of identified landmarks [571], [572]. Generally a divergence of 1-3 mm in routine surgery can be expected [559], [560], [567], [570], [572], [573], [574].
For the economic evaluation of medical navigation devices a setup time of about 15 min per case must be taken into account. For new systems, these values may be higher [560], [562], [564], [565], [569], [570], [572], [573], [574], [575]. Also, in case of an inexperienced surgeon the surgery itself is prolonged by approximately 16 min [569]. When technical inadequacies occur, time loss is significantly higher, and an additional amount of time is needed to adjust the data set [571]. Technical problems of navigation devices can lead to the termination of the procedure [65]. Other authors deny the loss of time, stating that especially during long procedures, time for setup is balanced by straightforwardness of the surgery [560], [566], [568], [576]. Generally, the costs increase with the use of navigation systems. Values are approximately 7% or around 500 € [560], [566], [572], [575]. In addition not all tomographic images of the patient can be used for navigation – in 2006 the rate was about 50% [576]. Here additional costs and stress must be taken into account [559], [570].
The American Academy of Otolaryngology-Head and Neck Surgery (AAO-HNS) recommends navigation assisted surgery in the following cases [11], [560], [562], [575], [577]:

- Revision surgery.
- Altered anatomy (developmental, postoperative or posttraumatic).
- Extensive nasal polyposis and sinus polyps.
- Disease with involvement of the frontal sinus, posterior ethmoid or sphenoid sinus.
- Disease in close relationship to the skull base, orbit, optic nerve, carotid artery.
- CSF fistula or skull base defect.
- Benign or malignant tumour.

Other authors limit this range of indications in surgery for chronic rhinosinusitis to e.g. a widely spread disease, surgical revisions and mucoceles or instructional surgeries and special anatomical conditions [15], [573], [578], [579]. Due to a survey of surgeons, the extent of the disease does not imply a benefit of the navigation system [579]. However, is a system available, it is often used in routine [568], [577]. It promotes the subjective safety and the anatomical precision, but does not replace the expertise [560], [573], [575] – the otorhinolaryngologist must master the anatomy and must not rely on a navigation system [524], [572].
As reflected in literature navigation systems are thus not indispensable components of the technical standards in routine paranasal sinus surgery. In other non-routine exceptional cases, however, not using navigation assistance needs to be justified [560], [572], [575], [580]. Regarding rhino-neurosurgery other conditions are applied: here, the navigation system is usually seen as standard. It reduces the duration of the surgery and reduces the rate of complications [560], [581].
Experienced and inexperienced surgeons have a different access to navigation systems:

Experienced surgeons use the navigation system in routine surgery in order to save time and to reduce personal time constraints. The basic surgical strategy does not change, although comparatively more extensive procedures (e.g. regarding the frontal sinus) using the navigation were reported [568]. There are different views concerning the influence of navigation on the completeness of routine interventions [561], [582]. In any case, subjective safety is higher and confidence in the technology increases with experience [562], [563], [564], [573], [583].
Junior otorhinolaryngologists benefit from navigation systems during their training [559], [566], [567], [571]. The personal learning curve is improved [572], the intraoperative "stress level" of the surgeon remains the same, however [584]. Untrained surgeons use the system more frequently than advanced surgeons, preferably in the area of the sphenoid sinus, the lamina papyracea, the skull base and frontal sinus. In about 50%, this leads to a modified surgical strategy. The completeness of the procedure increases subjectively and objectively [569], [576]. On the other hand inexperienced surgeons overestimate the benefit of the systems - as a result a dependent relationship and a negative effect on the personal development of individual action algorithms for intraoperative problem solving is feared ("surgical skill loss") [569]. For this reason, a general application is not recommended by different authors [567].

7 Process quality

Documentation in the OR, checklist

It has become customary to retrieve routine procedures by specific preoperative checklists before and during surgery. In addition, a ritualized preoperative coordination of the surgical team ("team time out") is often carried out [585], [586], [587]. A special "checklist", adapted to the specific needs of sinus surgery, was presented. A positive impact on formal procedures in the operating room was proven, a desired effect on the rate of complications can statistically not be secured [588], [589]. Standards of care in documentation and cooperation must be followed in sinus surgery. Operative reports should generally be written within 24 hours, and should not be modified at a later stage [76], [524]. During the entire hospitalization flaws in communication between physicians, patients and nurses or among physicians can lead to significant therapeutic and medico-legal problems [65]. Clinical procedures must be planned, secured and controlled taking into account the fact that monitoring and patient care is shared [536].
When complications occur, the attending physicians are well advised to pay attention to document all measures of diagnosis and therapy intensely. The surgeon is personally obliged to accurately inform all following physicians even at inconvenient times.

Wrong side surgery

"Wrong side surgery" can directly become a medico-legal issue even in routine sinus surgeries [590], [591]. Generally 10% of active ENT surgeons have experienced such cases [591]. For means of prevention different strategies are applied. A strict, systematic, direct analysis of preoperative imaging of each patient by the surgeon just before surgery in the OR is recommended. Special ENT radiological (Table 2) or general (see above) checklists can be used – in consideration of the inevitable additional organizational load [591], [592].

Tomographic representation of the anatomy

In the last decade preoperative imaging was not necessarily performed in every case, even a survey radiograph had been commonly used [437], [593]. The standard of preoperative imaging has changed, however: radiological scans (CT/MRI/DVT) are indicated before every sinus surgery (in more than one plane) [592], [594]. Reconstructions from axial spiral CT data sets are acceptable regarding certain quality standards [135], [199], [595]. In case of complex surgeries or extended frontal sinus surgery all three planes should be available [82], [113], [419]. The present technical status regarding modern virtual endoscopy on the basis of CT data sets doesn't provide any additional information [596].
Special instructions for evaluation of preoperative CT scans were presented [592], [594] (Table 2). In particular, pre-existing anomalies (malformation, condition after surgery, condition after trauma, destruction of tumours) should be taken into account [198] (Figure 15). Regarding anatomical variants, consistency of radiological and intraoperative findings can be expected in about 90% [263]. According to some authors, the rate of intraoperative complications is definitely higher if the corresponding CT images are not present in the operating room [76]. Other authors explicitly did not notice any corresponding influence [86], [597]. Nevertheless, the majority of authors supports the view, that constant access to imaging modalities during sinus surgery represents currents standards. In analogy with this view there are reports dealing with an injury of the internal carotid artery due to missing axial CT scans [420] or an encephalocele which was overlooked, resulting in CSF fistulas [76].

Postoperative nasal packing

Rhinologic literature presents various forms and properties of nasal packing with their specific risks [177]. Nationally and internationally, there is an increasing tendency to abolish nasal packing in routine sinus surgery [178], [282]. In the year 2000/2001 for instance, nasal packs were still applied in ¾ of patients in Great Britain [45]. In more recent studies nasal packing was not used in about 90% – however, preferably those patients without

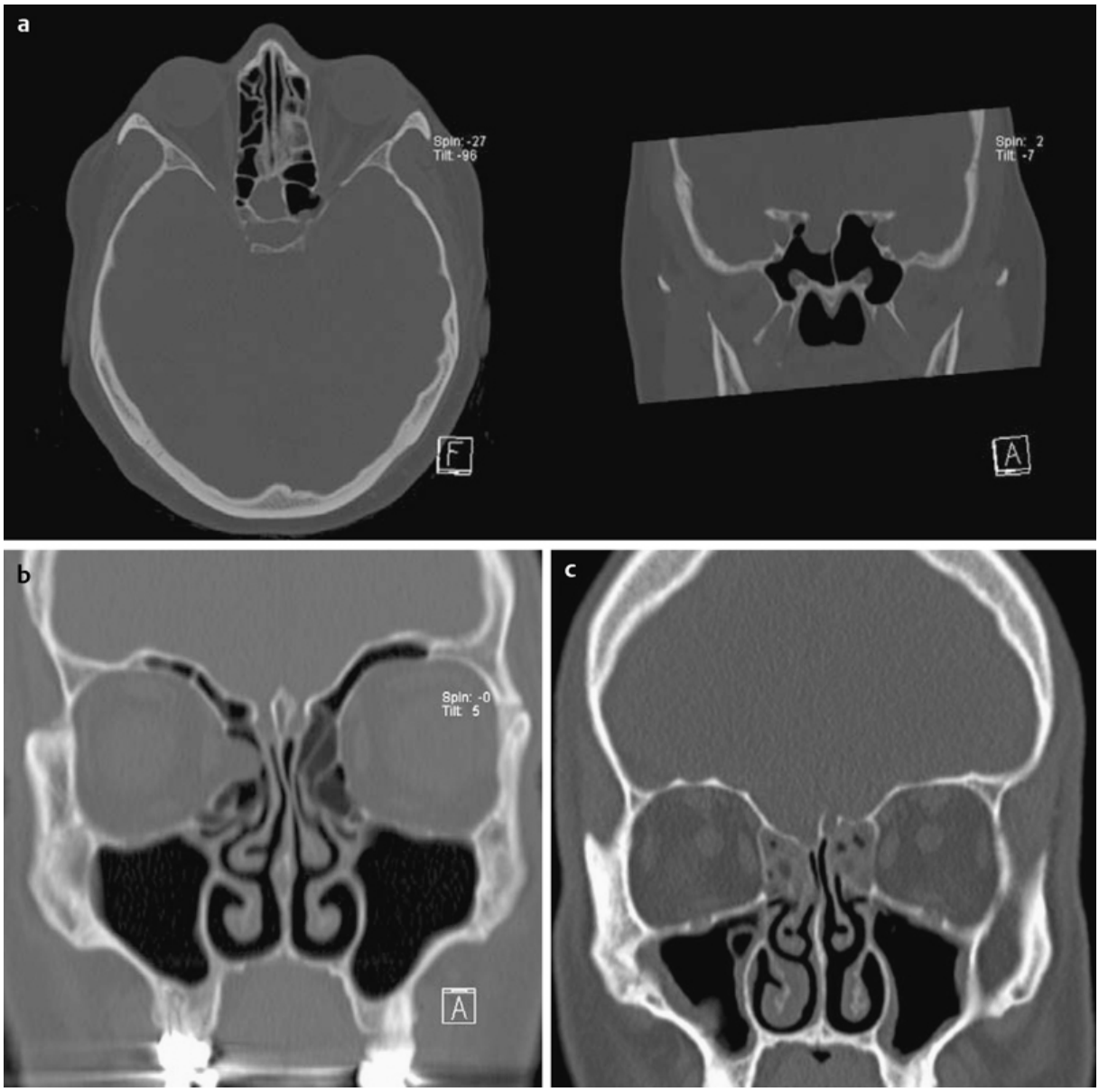

Figure 15: a. Incidental finding of a meningocele located at the roof of the sphenoid sinus.
b. incidental finding of a prolapse of orbital tissue into the aerated ethmoidal cell system.
c. Minor anatomical irregularity revealing asymmetry of the ethmoidal roof of the left and right side.

nasal packing had surgery under local anaesthesia or with low blood loss, without concomitant septal correction and without surgery of the lower turbinates [145], [598], [599]. In about 3% postoperative bleeding occurred and had to be treated secondarily [600]. The decision for or against nasal packing has to be carefully assessed bearing in mind individual, organizational aspects as well as the patient's medical history.

Accidentally remaining nasal packing in the nasal cavity is very rare [590]. In literature spectacular cases are known where nasal packs have been left behind for years [600], [601]. In a single case the packing remained for about 8 years. In this case sponge material had been inserted as an "inlay" to close off a defect of CSF fistula. At the location of the fistula an encephalocele had formed additionally [600]. In a single case where nasal packs had been left behind over 4 years a compensation of € 20,000 has recently been determined judicially [601]. In literature apart from these special cases, the rate of residual nasal packing is indicated with a rate of 0.08% to 0.2% [72]. Against the background of this issue security threads in nasal packing units must be recalled. At the end of each surgery a control through counting is an absolute standard – ultimately the surgeon is responsible for this 'count check' [601].

Outpatient sinus surgery

In overviews from Great Britain, the rate of outpatient sinus surgery (day surgery) was only about 17% in the last two decades [45], [593]. In contrast notifications from Norway, the USA and also from Great Britain depict a rate of about 85% [20], [115], [602] or e.g. a 47% rate of

"overnight" surgery, outpatient surgery in 45% and in-patient surgery in only 9% [93].
The patient population subjected to outpatient surgery is often exclusive: among others minor procedures, balloon dilatation, or possibly surgeries under local anaesthesia are preferred [602], [603], [604]. According to literature, patients subjected to a number of specific other interventions, such as advanced, isolated frontal sinus surgery, may be observed overnight and are released on the 1st postoperative day [77].
In outpatient cases the patient is released when he is fully awake and oriented postoperatively [155]. About 2/3 of day surgery cases are done without nasal packing; in other series, patient's nasal packing remains only for hours [602]. In the federal republic, guidelines for ambulatory surgery and day surgery of the German Society of Anaesthesiology and Intensive Care Medicine have to be taken into account (note the appendix).
In up to 20% of outpatient cases, treatment is altered from outpatient to in-patient due to an unexpected perioperative incidence [605]. Secondary clinical admissions of released patients with an ambulant surgery occur in about 5%. In some cases following symptoms apply: nausea / vomiting, circulatory problems, headache, epistaxis, especially CSF leaks, delayed orbital haematoma. Patients with comorbidities such as asthma or patients with conspicuous history of drugs (ondansetron) were preferentially affected in one study [335], [602], [606]. The overall risk may be increased in elective, ambulatory surgery. As a consequence, medico-legal issues may occur more frequently [607].

Histological diagnosis of the resected specimens

The histological examination of tissue removed during surgery can secure the diagnosis of chronic sinusitis; furthermore information regarding individualized postoperative treatment is obtained (e.g. neutrophilia, eosinophilia). Yet the benefit of the routine examination of tissue samples in chronic rhinosinusitis is called into question: in a case series with routine histology merely 0.1–1% surprisingly relevant diagnoses were found (usually inverted papillomas; rarely Wegener's, sarcoidosis, carcinoma, myeloma, and angiofibroma) [608], [609], [610], [611], [612]. In any case, histological examination of resected specimens is indicated for unilateral or macroscopically suspicious intraoperative findings, respectively in case of unusual pain or a history of epistaxis [610], [611], [613].
For dacryocystorhinostomy, the situation is similar from a statistical point of view: only in 0.2% a relevant finding (lymphoma) was unexpectedly discovered [614].
The use of shavers does not exclude adequate processing of resected specimens by the pathologist. In the worst case additional (non-decisive) information in the diagnosis of incident lymphoma is lost [615], [616].
It has to be considered that a histological examination can be useful in regard to medico-legal view. The histological specimen may function as a building block for evidence of a carefully performed surgery (absence of local foreign tissue in the resected specimen) and as detection of relevant tissue changes as proof for the indication. Due to this fact, histological examination of resected specimens in routine sinus surgery seems to be sensible by all means. With an increasing molecular phenotyping of chronic rhinosinusitis the importance of histological examination may increase.

Cooperation with anaesthesiology

Sinus surgery can generally be performed in local anaesthesia with anxiolytics (midazolam) and analgesia (fentanyl or alfentanil) e.g. procedures in "stand-by" [617]. Much more common, however, is general anaesthesia.
The cooperation between the ENT surgeon and the anaesthesiologist in the OR is based on the "Agreement on cooperation of surgical patient care" (see appendix). From the perspective of an anaesthesiologist special aspects of sinus surgery are e.g. problems with controlled hypotension or tachycardia after the insertion of adrenaline-soaked nasal packing. Perioperatively asthmatics may experience an exacerbation of their bronchial asthma. The rate is about 1.5%, hence is lower than in surgery under local anaesthesia [69], [72], [73]. In a broader sense, regarding the interdisciplinary working area in sinus surgery, the following aspects may lead to problems and discussions: dislocation of nasal packing, forgotten oropharyngeal occlusion, clots in the airway, aspiration of resected material, progressive edema of the mucosa e.g. after posterior nasal packing, numbness and subjective obstruction due to residual effects of local anaesthetics [618]. Paresis of the hypoglossal nerve in the scope of intubation for sinus surgery have been reported; in this case the complications has no causal relation to the surgical intervention itself [619].
Generally an accurate monitoring of circulatory parameters is essential during anaesthesia and with regard to the topical application of adrenalin indispensable. In case of controlled hypotension increased demands apply [153], [620].
Frequently in nasal surgery the anaesthesiologist applies pharyngeal packing to prevent aspiration or postoperative nausea and vomiting. The effectiveness of this measure is disputed. Conversely, the pharyngeal packing has its own risks, in particular causing local trauma with sore throat postoperatively, a swollen tongue or in very rare cases endangerment due to left over or residual packing [621], [622], [623], [624], [625]. In general more frequent postoperative nausea, possibly with vomiting (PONV: postoperative nausea and vomiting) has to be expected in ENT surgery [626].
In surgeries associated with higher blood loss, pharyngeal nasal packing still is indicated.
The anaesthesiologist may witness surgical complications. A severe phase of hypertension was reported after assumable intracerebral injection of epinephrine.

Episodes of striking hypotension may otherwise occur in case of skull base perforations and intracerebral vascular damage. Generally the anaesthesiologist has to be aware, that instable circulatory parameters or problems in waking the patient from anaesthesia or even possibly sudden focal neurological signs may mark a serious complication [519]. The interdisciplinary regime and management in case of major bleeding was mentioned before.

8 Medico-legal aspects

Surgical expertise

Generally, only surgeons capable of handling typical complications (e.g. lateral canthotomy/cantholysis) as well as performing external procedures if necessary, should operate on the paranasal sinuses [238]. Similar to the entire surgical training, sinus surgery mostly refers to an initial "learning curve". When endoscopic techniques were introduced, partly dramatic learning curves were described at first [81], [111]. Other references mention a less spectacular form of an increased complication rate for inexperienced surgeons during the first 100 procedures (e.g. 8%), with individual differences and dependencies of training and equipment [627], [628]. A structured training with supervision seems to enable learning techniques of endoscopic sinus surgery without affecting the safety of the patient and the subjective surgical outcome [299], [629], [630].

In general, the rate of complications of experienced ENT surgeons is regarded as lower in literature [62], [73]. Different authors question or deny these facts [63], [68], [74], [75], [86], reporting the usual complication rate of teaching hospitals [108] or even an increased rate of complications with experienced surgeons [88], [193].

In this controversy, the type of complication as well as the extent and frequency of intervention have been taken into account: inexperienced surgeons therefore have a higher risk of injuring the dura or the periorbit [105], [190], [627]. The accumulation of dura defects with beginners was contradicted from different side [196]. Other authors merely suggest an increase in synechiae or occluding scars in the ostium of the frontal sinus [631]. Relevant bleeding occurred without referring to the experience of the surgeon [39] – experienced surgeons, however, perform increasingly extensive surgery [75]. As a consequence, especially dramatic complications with medico-legal consequences are observed more frequently [93], [92], [632].

Preoperative medical information

Internationally the requirements for the scope of medical information are defined differently. The majority of surgeons in Anglo-American countries inform patients according to the "numeric standard", all complications with an incidence of ≥1% are mentioned towards the patient [88], [437], [633]. In the Federal Republic of Germany the actual incidence of potential complications is not relevant for medical information - rather, all risks that are specific or even surprising for the patient need to be discussed, provided that their implementation can change the future of their lives significantly [634]. Given that sinus surgery is mostly elective and the underlying disease is not life threatening, medical information has to meet relatively high demands.

In Great Britain only 50% of ENT surgeons inform patients regarding relevant bleeding preoperatively, 44% refer to blindness and merely 1/3 to diplopia [437]. According to surveys American otorhinolaryngologists consider the following complications essential regarding preoperative medical information for sinus surgery: CSF fistula, injury of the orbit, bleeding, infection and risks of anaesthesia. Less than half of the surgeons mention anosmia, epiphora, cerebrovascular complications, myocardial infarction, death and atrophic rhinitis [633]. In 40% death is explicitly stated as a complication. In literature, further reference to meningitis, permanent diplopia, intraorbital hematoma, loss of vision and intracranial lesions is encouraged [76], [84].

Especially young and educated patients have increased demands for thorough preoperative information. In surveys the interest in preoperative medical information exceeded the average expectation of physicians – 40% of respondents were even interested in risks with an incidence of 1/1000 [635], [636]. Although anxiety may be provoked, patients appreciate detailed information – the number of patients that consequently withdraw from surgery is small (2%) [78]. A template, listing complications without additional comments is inadequate [607]. According to subsequent analysis, patients wished that the longer post-operative recovery had been addressed. The same applies for non-surgical treatment alternatives [78]. In every case the chances of the surgery have to be discussed realistically- complete and permanent elimination of all symptoms cannot be achieved through sinus surgery [524].

One third of patients experiencing surgical complications reported subjective deficits regarding preoperative medical information [607], [637]. On the contrary, compensation is frequently granted for a complication in court, which has been explicitly mentioned during preoperative information [638].

Medical behavior

If a surgical complication arises, the surgeon should try to remain calm and review the situation. The objective is to estimate, whether continuing the treatment with the resources at hand is still possible and reasonable and also whether additional medical disciplines should be involved either generally or as an emergency measure [197], [580].

After surgery, immediate communication with the patient and his relatives is particularly important. A complete explanation of the complication is requested by the vast majority of the patients - the number of physicians with

this point of view is significantly smaller [607], [639], [640]. In order to overcome deficiencies in communication adequate guidelines on a secure legal basis are available to the physician and the general public (alliance for patient security: "Aktionsbündnis Patientensicherheit" http://www.aktionsbuendnis-patientensicherheit.de/apsside/Reden_ist_Gold_final.pdf). Most of the time little attention is paid to the fact that confronting the surgeon with a possible error in treatment leads to relevant emotional stress proportional to the observed results for the physician as a person ("the second victim"). In the daily clinical routine support in such situations often remains inadequate [641], [642], [643].

Medico-legal assessment

Generally, errors in treatment cannot always be avoided [643]. The physician can be accused of or exculpated from them – however, an internal assessment or the evaluation of a consultant needs to be conducted for each case individually [644]. Endonasal sinus surgery is explicitly classified in some references as "potentially-high-risk-surgery" with a high affinity to medico-legal problems [65], [607].

In general, the vast majority of patients stays out of the way of a legal conflict after the experience of an operation with complications. If a legal conflict arises however, "sinusitis" is the most common diagnosis in ENT-surgery in the USA. Most argued subjects are the correct surgical technique followed by questioning the preoperative medical information and the indication for the operation [632], [637]. In most cases the center of the argument revolves around an intracranial or orbital complication (including a CSF fistula or blindness) and anosmia [524], [638], [645].

Concerning the forensic assessment of routine surgery for chronic rhinosinusitis the following circumstances should be discussed:

- An expert at court is not urged to measure a given treatment against the best possible treatment or his own method in the case at hand. He should in fact only evaluate if treatment is justifiable concerning the principle of free choice of method [634].
- Since medical treatments permanently are subject to optimization ("dynamic measure of care") the medical standard given at the time of the treatment is considered as the measure for an experts assessment [646].
- The expert should only use the term "severe negligence" (coarse error in treatment) after a very careful evaluation and providing a detailed explanatory statement. "Severe negligence" is not a "distinct error". A coarse ("fundamental") error in treatment is only given, when elemental rules of diagnostics and/or therapy are violated [634]. An accidental, isolated skullbase- and dural injury for instance, does not qualify directly as a definitive error, let alone severe negligence.

In most cases the conformance of different experts at court on the same case is principally sufficient, for some series though it is merely as high as 60%. If the damage at hand is severe and lasting, a general tendency for less surgeon-favorable advisory opinions can be observed [647], [648].

In lawsuits in the USA the judges decided for and against the accused physician in approximately 50% of the cases. The financial compensation in these cases where not in relationship to the incurred damage – surprisingly fatalities were compensated below average [637], [638].

9 Training issues

Against the background of diminishing financial resources and raised medico-legal demands training issues play an increasingly important role in all surgical disciplines [649]. Therefore the operating room cannot be the primary forum for gaining surgical experience in the future [650].

Generally more intensive, maybe multimedial studies of anatomy and formal operation techniques should lead to a reduction in complications of beginners [651]. Besides, dissection and preparation courses for basic training are held in high esteem by both teachers and students, although their effect and efficiency in regard to acquiring surgical expertise has so far not been studied extensively [582], [652]. In addition, young ENT surgeons are encouraged to attend special dissection courses [653].

In order to learn and train endoscopic surgery techniques, endonasal, endoscopic dissections using cadaver specimens are certainly unmatched. Quite a number of special dissection manuals have been published [654], [655], [656], [657], [658], [659], [660], [661], [662]. Ideal conditions would imply a training laboratory available in every teaching clinic [663]. However, due to the difficult provision of suitable anatomic specimens, strict limits are set. In the Federal Republic of Germany, anatomists recently argued against a liberalized practice concerning the provision of unfixed anatomical specimens in a position paper [664]. According to some authors, animal specimens, e.g. sheep or lamb, are suitable for training purposes [665]. Other authors have worked out more detailed training programs for paranasal sinus surgery, using a sheep model [666], [667], [668].

As an alternative or a replacement, differently equipped computational simulators (e.g. "Endoscopic Sinus Surgery Simulator ES3", "Virtual Sinus Surgery Simulator", "VoxelMan SinuSurg", "Nasal Endoscopy Simulator") and training programs have been developed [669], [670], [671], [672], [673], [674].

It could be shown that the use of appropriate simulators enhances the study of sinus anatomy [675], [676]. However, effective training models for sinus surgery should not only communicate geometry (anatomy), but also haptic skills, as well as "characteristics of incision" [677], [678], [679]. Conversely, abstract training of manual dexterity without any concrete relation to sinus

anatomy is not sufficient, either [680], [681]. Students find it most difficult to master three-dimensional endoscopic anatomy, especially in the case of irregularities (previous operations) or manipulation controlled by optics revealing different angles of view [680].

In general, improved simulators could not only be used to teach anatomy, but also to measure surgical skills with regard to perception, visual-spatial coordination and psychomotricity. If applicable, the results could be compared competitively to those of other test candidates [669], [682], [683]. Although the benefit for effective surgical dissection was sometimes estimated to be low [84], [684], new comparative studies already reveal a positive approach, at least partially [10]. Simulator training preserves resources of the teaching clinics [685] and is especially suited for junior residents [684], [685]. The completion of simulator practices shows a learning curve with plateau formation approaching the values reached by experienced surgeons [685], [686]. This competence in using the simulator – either naturally existing or gained by exercise – is lasting and may allow predictions concerning later 'live-performance' in the operating room [10], [686], [687]. The results of the simulator exercise first and foremost depend on the intensity of exercise, not on the handedness or on specific living conditions (e.g., experience with video games, actively playing instruments) [688]. Other sources are rather cautious towards the benefit of simulators for concrete acting in the OR [675]. It has not yet been demonstrated whether simulator exercises definitely lead to an improved quality of patient care, i.e. to a lower rate of complications. – As a matter of principle, this claim will be difficult to prove [689].

As an alternative, elaborate (e.g. "Sinus Model Otorrhino Neuro Trainer S.I.M.O.N.T.") [690], [691] or simplified plastic models [692] have been introduced. Abstract training models with installed silicon face masks [693], [694] permit to train dexterity in confined space. In subsequent simulations using anatomical preparations, the learning curve was improved [695]. Complete alloplastic face models with all paranasal sinuses are useful, however, according to their nature, they are consumed in surgical practice and are therefore cost-intensive [696]. Generally their use would be justified e.g. in specific training of action plans in case of severe intraoperative complications. A remarkable up-to-date example hereof is the combination with an animal model: a sinus model made from foam ("S.I.M.O.N.T" [691], see above) was modified in the area of the sphenoid sinus. Subsequently, the appropriate artery of a living test animal (sheep, carotid artery) was exposed and integrated into the model instead of the human internal carotid artery [421], [426], [430].

After adjustment of the artery into the lateral wall of the sphenoid sinus, cooperation and effectiveness of the surgical team in the treatment of internal carotid artery injuries could be trained under "real life conditions". Extensive use of this animal model is hard to imagine for various reasons.

A training using preparations and simulators will only be successful if it is embedded into a defined clinical training curriculum [650]. The use of special evaluation forms is a tool for practical analysis of the actual competence of inexperienced sinus surgeons. Two special data forms have been validated ("Endoscopic Sinus Surgery Competence Assessment Tool ESSCAT" and "Endoscopic Sinus Surgery Assessment Tool") [697], [698]. Due to the repeated use of these forms in the operation room, the evolving competence of the sinus surgeon can be analyzed, quantified and compared. The observation that certain partial surgeries, such as identifying and dissecting the uncinate process have a high correlation with the surgeon's later 'overall performance', is remarkable [697]. These data can be used as part of a structured, individual measurement of success in surgical training.

In regard to interdisciplinary rhino-neurosurgery, the preconditions and requirements mentioned in this section apply in a higher sense. This type of surgery is only acceptable on the basis of a well-coordinated and experienced team and with the expectation of a sufficient number of cases. Suggestions for a gradual training, range from attending surgical courses to dissecting models to surgical training by special teams with defined cases of increasing complexity [699], [700]. Additionally, a rat model was developed, for the purpose of training such as dissecting vessels and treating basic vessel injuries in confined spaces [701]. Endoscopic hypophysis surgery is paradigmatic: Here, with reference to the observed learning curves, a subspecialization is discussed [702], [703]. In general 70–80 endoscopic pituitary surgeries are rated as adequate collection for sufficient surgical experience in this particular field [103]. In some places ENT surgeons assist unexperienced neurosurgeons in conquering the "nasal steps" during their first 40 pituitary surgeries [704].

10 Summary

Over the last two decades endonasal sinus surgery has substantially evolved and differentiated. There has been further development in minimalizing procedures and in expanding "rhino-neurosurgery" significantly. As a result, requirements in patient care, structure- and process quality as well as the training of future physicians has been intensified and diversified considerably in comparison to past publications e.g. [23], [520]. Special focus is set on appropriate standards in case of threatening or even manifest complications which have occurred intra- or postoperatively. The main concern of the present paper is to point out the common side effects and complications of endoscopic sinus surgery with its therapeutic consequences in regard to the current literature and to respond to the numerous open questions and contradictory recommendations. A final, summarizing list of keywords for routine use is displayed in Table 3 [79], [520].

Table 3: Special keywords to consider in context with medico-legal aspects of sinus surgery for the treatment of chronic rhinosinusitis (based on: [79]).

Medical history: • Before sinus surgery pay attention to certain preliminary damages (e.g. eye diseases, pupil differences) or risk factors (anticoagulant substances, e.g. ASS).
Preoperative examination: • Adequate preoperative imaging (multiplanar image, >1 plane) before every surgery (even minor surgeries). • Olfactory test recommended. • Ophthalmic examination recommended on individual basis.
Questions regarding indications for surgery: • Is there a possible connection between symptoms and diagnostic findings? • Are conservative treatment options exhausted and is that fact sufficiently documented? • Does the extent of the surgery comply with the diagnostic findings (pre-, intraoperatively)?
Preoperative medical information: • Detailed preoperative medical information (informed consent): mentioning all significant risks (e.g. irreversible damage of central nervous structures = brain damage, injury of intracranial blood vessels, injury of the optic nerve, diplopia, dry nose, loss of the sense of smell …), consequences of complications for independent living, individual notes (handwritten). • Adequate time span between medical consultation and surgery except in an emergency. • Language and terminology must be understandable for the patient.
Structure- and process quality: • Optic tools (endoscope, maybe microscope) available in the OR. • Common micro-instruments available. • Imaging (multiplanar image > 1 plane) available during surgery. • Sufficient expertise of the surgeon provided. • In individual cases a navigation system should be available: for complex surgeries and rhino-neurosurgical procedures.
Documentation: • Apply strict criteria regarding documentation. • Document the preoperative examination and treatment. • Store document of 'informed consent'. Offer a copy to the patient. • Dictate surgical report at the same day (no forms, avoid text-blocks).
Behavior of the physician after a surgery with complications: • Precise, prompt documentation of the medical decisions, actions (e.g. consultation of other specialists, imaging controls etc.) and interventions. • Backup documents. • Consult the patient and/or relatives; avoid time pressure. • Considerate choice of words. • Mention conciliation board of the medical associations.

Notes

Competing interests

The authors declare that they have no competing interests.

Acknowledgements

Thanks to Constanze Erdmann and Madlen Hackbart for supporting us in acquiring the necessary literature.

References

1. Chen Y, Dales R, Lin M. The epidemiology of chronic rhinosinusitis in Canadians. Laryngoscope. 2003 Jul;113(7):1199-205. DOI: 10.1097/00005537-200307000-00016

2. Fokkens WJ, Lund VJ, Mullol J, Bachert C, Alobid I, Baroody F, Cohen N, Cervin A, Douglas R, Gevaert P, Georgalas C, Goossens H, Harvey R, Hellings P, Hopkins C, Jones N, Joos G, Kalogjera L, Kern B, Kowalski M, Price D, Riechelmann H, Schlosser R, Senior B, Thomas M, Toskala E, Voegels R, Wang de Y, Wormald PJ. EPOS 2012: European position paper on rhinosinusitis and nasal polyps 2012. A summary for otorhinolaryngologists. Rhinology. 2012;50(Suppl 23):1-299. Available from: http://www.rhinologyjournal.com/supplement_23.pdf

3. Hedman J, Kaprio J, Poussa T Nieminen MM. Prevalence of asthma, aspirin intolerance, nasi polyposis and chronic obstruction pulmonary disease in a population-based study. Int J Epidemiology. 1999;28:717-22. DOI: 10.1093/ije/28.4.717

4. Stuck BA, Bachert C, Federspil P, Hosemann W, Klimek L, Mösges R, Pfaar O, Rudack C, Sitter H, Wagenmann M, Weber R, Hörmann K; German Society of Otorhinolaryngology, Head and Neck Surgery. Leitlinie "Rhinosinusitis"–Langfassung: S2-Leitlinie der Deutschen Gesellschaft für Hals-Nasen-Ohren-Heilkunde, Kopf- und Hals-Chirurgie [Rhinosinusitis guidelines–unabridged version: S2 guidelines from the German Society of Otorhinolaryngology, Head and Neck Surgery]. HNO. 2012 Feb;60(2):141-62. DOI: 10.1007/s00106-011-2396-7

5. Mattos JL, Woodard CR, Payne SC. Trends in common rhinologic illnesses: analysis of U.S. healthcare surveys 1995-2007. Int Forum Allergy Rhinol. 2011 Jan-Feb;1(1):3-12. DOI: 10.1002/alr.20003

6. Baumann I, Blumenstock G, DeMaddalena H, Piccirillo JF, Plinkert PK. Lebensqualität bei Patienten mit chronischer Rhinosinusitis: Validierung des Sino-Nasal Outcome Test-20 German Adapted Version [Quality of life in patients with chronic rhinosinusitis: validation of the Sino-Nasal Outcome Test-20 German Adapted Version]. HNO. 2007 Jan;55(1):42-7. DOI: 10.1007/s00106-005-1347-6

7. Seyring C, Bitter T, Böger D, Büntzel J, Eßer D, Hoffmann K, Jecker P, Müller A, Radtke G, Guntinas-Lichius O. Versorgungsforschung zu Nasennebenhöhlenoperationen in Thüringen: Epidemiologie und Ergebnisse [Health services research on paranasal sinus surgery in Thuringia: epidemiologic key data and outcome]. Laryngorhinootologie. 2012 Jul;91(7):434-9. DOI: 10.1055/s-0032-1304592

8. Cornet ME, Reinartz SM, Georgalas C, van Spronsen E, Fokkens WJ. The microdebrider, a step forward or an expensive gadget? Rhinology. 2012 Jun;50(2):191-8.

9. Cosway B, Tomkinson A, Owens D. The European positional paper on rhinosinusitis and nasal polyps: has the introduction of guidance on the management of sinus disease affected uptake of surgery and acute admissions for sinusitis? Eur Arch Otorhinolaryngol. 2013 Mar;270(3):889-92. DOI: 10.1007/s00405-012-2027-2

10. Fried MP, Sadoughi B, Gibber MJ, Jacobs JB, Lebowitz RA, Ross DA, Bent JP 3rd,Parikh SR, Sasaki CT, Schaefer SD. From virtual reality to the operating room: the endoscopic sinus surgery simulator experiment. Otolaryngol Head Neck Surg. 2010 Feb;142(2):202-7. DOI: 10.1016/j.otohns.2009.11.023

11. Hepworth EJ, Bucknor M, Patel A, Vaughan WC. Nationwide survey on the use of image-guided functional endoscopic sinus surgery. Otolaryngol Head Neck Surg. 2006 Jul;135(1):68-73. DOI: 10.1016/j.otohns.2006.01.025

12. Moeller CW, Welch KC. Prevention and management of complications in sphenoidotomy. Otolaryngol Clin North Am. 2010 Aug;43(4):839-54. DOI: 10.1016/j.otc.2010.04.009

13. Psaltis AJ, Soler ZM, Nguyen SA, Schlosser RJ. Changing trends in sinus and septal surgery, 2007 to 2009. Int Forum Allergy Rhinol. 2012 Sep-Oct;2(5):357-61. DOI: 10.1002/alr.21036

14. Ramakrishnan VR, Kingdom TT, Nayak JV, Hwang PH, Orlandi RR. Nationwide incidence of major complications in endoscopic sinus surgery. Int Forum Allergy Rhinol. 2012 Jan-Feb;2(1):34-9. DOI: 10.1002/alr.20101

15. Tabaee A, Hsu AK, Shrime MG, Rickert S, Close LG. Quality of life and complications following image-guided endoscopic sinus surgery. Otolaryngol Head Neck Surg. 2006 Jul;135(1):76-80. DOI: 10.1016/j.otohns.2006.02.038

16. Venkatraman G, Likosky DS, Morrison D, Zhou W, Finlayson SR, Goodman DC. Small area variation in endoscopic sinus surgery rates among the Medicare population. Arch Otolaryngol Head Neck Surg. 2011 Mar;137(3):253-7. DOI: 10.1001/archoto.2011.17

17. Bhatti MT, Giannoni CM, Raynor E, Monshizadeh R, Levine LM. Ocular motility complications after endoscopic sinus surgery with powered cutting instruments. Otolaryngol Head Neck Surg. 2001 Nov;125(5):501-9.

18. Venkatraman G, Likosky DS, Zhou W, Finlayson SR, Goodman DC. Trends in endoscopic sinus surgery rates in the Medicare population. Arch Otolaryngol Head Neck Surg. 2010 May;136(5):426-30. DOI: 10.1001/archoto.2010.58

19. Bhattacharyya N. Ambulatory sinus and nasal surgery in the United States: demographics and perioperative outcomes. Laryngoscope. 2010 Mar;120(3):635-8. DOI: 10.1002/lary.20777

20. Martin TJ, Yauck JS, Smith TL. Patients undergoing sinus surgery: constructing a demographic profile. Laryngoscope. 2006 Jul;116(7):1185-91. DOI: 10.1097/01.mlg.0000224506.42567.6e

21. Gilsbach JM, Mann W. Indikationen und Praxis der simultanen Neuro-Rhinochirurgie [Indications and general practice of simultaneous neuro-rhinosurgery]. Eur Arch Otorhinolaryngol Suppl. 1993;1:219-26.

22. Draf W, Berghaus A. Tumoren und Pseudotumoren ("tumorähnliche Läsionen") der frontalen Schädelbasis, ausgehend von der Nase, den Nasennebenhöhlen und dem Nasenrachenraum (einschliesslich der operativen Zugänge). Rhinochirurgisches Referat [Tumors and pseudotumors ("tumor-like lesions") of the frontal cranial base, originating in the nose, the paranasal sinuses and the nasopharynx (including surgical approach)]. Eur Arch Otorhinolaryngol Suppl. 1993;1:105-86.

23. Hosemann W. Die endonasale Chirurgie der Nasennebenhöhlen--Konzepte, Techniken, Ergebnisse, Komplikationen, Revisionseingriffe [Endonasal surgery of the paranasal sinuses--concepts, techniques, results, complications and revision interventions]. Eur Arch Otorhinolaryngol Suppl. 1996;1:155-269.

24. Stammberger H. Komplikationen entzündlicher Nasennebenhöhlenerkrankungen einschliesslich iatrogen bedingter Komplikationen [Complications of inflammatory paranasal sinus diseases including iatrogenically-induced complications]. Eur Arch Otorhinolaryngol Suppl. 1993;1:61-102.

25. Duncavage JA, Becker SS. The Maxillary Sinus – Medical and Surgical Management. New York: Thieme; 2011.

26. Hosemann W, Weber RK, Keerl RE, Lund VJ. Minimally Invasive Endonasal Sinus Surgery – Principles, Techniques, Results, Complications, Revision Surgery. New York: Thieme; 2000.

27. Rice DH, Schaefer SD. Endoscopic Paranasal Sinus Surgery. 3rd ed. Philadelphia: Lippincott Williams & Wilkins; 2004.

28. Simmen D, Jones N. Chirurgie der Nasennebenhöhlen und der vorderen Schädelbasis. Stuttgart: Thieme; 2005.

29. Stamm A. Transnasal Endoscopic Skull Base and Brain Surgery. New York: Thieme; 2011.

30. Wigand ME. Endoscopic Surgery of the Paranasal Sinuses and Anterior Skull Base. 2nd ed. Stuttgart: Thieme; 2008.

31. Wormald PJ. Endoscopic Sinus Surgery – Anatomy, Three-dimensional Reconstruction, and Surgical Technique. 2nd ed. New York: Thieme; 2008.

32. Govindaraj S, Adappa ND, Kennedy DW. Endoscopic sinus surgery: evolution and technical innovations. J Laryngol Otol. 2010 Mar;124(3):242-50. DOI: 10.1017/S0022215109991368

33. Kennedy DW. Technical innovations and the evolution of endoscopic sinus surgery. Ann Otol Rhinol Laryngol Suppl. 2006 Sep;196:3-12.

34. Shah RN, Leight WD, Patel MR, Surowitz JB, Wong YT, Wheless SA, Germanwala AV, Zanation AM. A controlled laboratory and clinical evaluation of a three-dimensional endoscope for endonasal sinus and skull base surgery. Am J Rhinol Allergy. 2011 May-Jun;25(3):141-4. DOI: 10.2500/ajra.2011.25.3593

35. Strauss G, Fischer M, Meixensberger J, Falk V, Trantakis C, Winkler D, Bootz F, Burgert O, Dietz A, Lemke HU. Bestimmung der Effizienz von intraoperativer Technologie: Workflow-Analyse am Beispiel der endoskopischen Nasennebenhöhlenchirurgie [Workflow analysis to assess the efficiency of intraoperative technology using the example of functional endoscopic sinus surgery]. HNO. 2006 Jul;54(7):528-35. DOI: 10.1007/s00106-005-1345-8

36. Tasman AJ, Feldhusen F, Kolling GH, Hosemann W. Video-Endoscope versus Endoscope for Paranasal Sinus Surgery: Influence on Visual Acuity and Color Discrimination. Am J Rhinology. 1999;13:7-10. DOI: 10.2500/105065899781389939

37. Welch KC, Stankiewicz JA. A contemporary review of endoscopic sinus surgery: techniques, tools, and outcomes. Laryngoscope. 2009 Nov;119(11):2258-68. DOI: 10.1002/lary.20618

38. McMains KC. Safety in endoscopic sinus surgery. Curr Opin Otolaryngol Head Neck Surg. 2008 Jun;16(3):247-51. DOI: 10.1097/MOO.0b013e3282fdccad

39. Siedek V, Pilzweger E, Betz C, Berghaus A, Leunig A. Complications in endonasal sinus surgery: a 5-year retrospective study of 2,596 patients. Eur Arch Otorhinolaryngol. 2013 Jan;270(1):141-8. DOI: 10.1007/s00405-012-1973-z

40. Castelnuovo P, Dallan I, Battaglia P, Bignami M. Endoscopic endonasal skull base surgery: past, present and future. Eur Arch Otorhinolaryngol. 2010 May;267(5):649-63. DOI: 10.1007/s00405-009-1196-0

41. Kurschel S, Gellner V, Clarici G, Braun H, Stammberger H, Mokry M. Endoscopic rhino-neurosurgical approach for non-adenomatous sellar and skull base lesions. Rhinology. 2011 Mar;49(1):64-73.

42. Kilty SJ, McLaughlin N, Bojanowski MW, Lavigne F. Extracranial complications of endoscopic transsphenoidal sellar surgery. J Otolaryngol Head Neck Surg. 2010 Jun;39(3):309-14.

43. Chiu AG, Kennedy DW. Disadvantages of minimal techniques for surgical management of chronic rhinosinusitis. Curr Opin Otolaryngol Head Neck Surg. 2004;12:38-42. DOI: 10.1097/00020840-200402000-00011

44. Hopkins C, Slack R, Lund V, Brown P, Copley L, Browne J. Long-term outcomes from the English national comparative audit of surgery for nasal polyposis and chronic rhinosinusitis. Laryngoscope. 2009 Dec;119(12):2459-65. DOI: 10.1002/lary.20653

45. Hopkins C, Browne JP, Slack R, Lund V, Topham J, Reeves B, Copley L, Brown P, van der Meulen J. The national comparative audit of surgery for nasal polyposis and chronic rhinosinusitis. Clin Otolaryngol. 2006 Oct;31(5):390-8. DOI: 10.1111/j.1749-4486.2006.01275.x

46. Bozdemir K, Kutluhan A, Çetin H, Yalçıner G, Bilgen AS. Comparison of outcomes of simple polypectomy plus balloon catheter dilatation versus functional endoscopic sinus surgery in nasal polyposis: a preliminary study. Am J Rhinol Allergy. 2011 May-Jun;25(3):198-200. DOI: 10.2500/ajra.2011.25.3608

47. Browne JP, Hopkins C, Slack R, Topham J, Reeves B, Lund V, Brown P, Copley L, van der Meulen J. Health-related quality of life after polypectomy with and without additional surgery. Laryngoscope. 2006 Feb;116(2):297-302. DOI: 10.1097/01.mlg.0000198338.05826.18

48. Dalziel K, Stein K, Round A, Garside R, Royle P. Systematic review of endoscopic sinus surgery for nasal polyps. Health Technol Assess. 2003;7:iii,1-159

49. Devars du Mayne M, Prulière-Escabasse V, Zerah-Lancner F, Coste A, Papon JF. Polypectomy compared with ethmoidectomy in the treatment of nasal polyposis. Arch Otolaryngol Head Neck Surg. 2011 Feb;137(2):111-7. DOI: 10.1001/archoto.2010.255

50. Khalil HS, Nunez DA. Functional endoscopic sinus surgery for chronic rhinosinusitis. Cochrane Database Syst Rev. 2006;(3):CD004458. DOI: 10.1002/14651858.CD004458.pub2

51. Kuehnemund M, Lopatin A, Amedee RG, Mann WJ. Endonasal sinus surgery: extended versus limited approach. Am J Rhinol. 2002 Jul-Aug;16(4):187-92.

52. Ragab SM, Lund VJ, Scadding G. Evaluation of the medical and surgical treatment of chronic rhinosinusitis: a prospective, randomised, controlled trial. Laryngoscope. 2004 May;114(5):923-30. DOI: 10.1097/00005537-200405000-00027

53. Lee JY, Lee SH, Hong HS, Lee JD, Cho SH. Is the canine fossa puncture approach really necessary for the severely diseased maxillary sinus during endoscopic sinus surgery? Laryngoscope. 2008 Jun;118(6):1082-7. DOI: 10.1097/MLG.0b013e318169028d

54. Ahmed J, Pal S, Hopkins C, Jayaraj S. Functional endoscopic balloon dilation of sinus ostia for chronic rhinosinusitis. Cochrane Database Syst Rev. 2011;(7):CD008515. DOI: 10.1002/14651858.CD008515.pub2

55. Blomqvist EH, Lundblad L, Bergstedt H, Stjärne P. A randomized prospective study comparing medical and medical-surgical treatment of nasal polyposis by CT. Acta Otolaryngol. 2009 May;129(5):545-9. DOI: 10.1080/00016480802298089

56. Masterson L, Tanweer F, Bueser T, Leong P. Extensive endoscopic sinus surgery: does this reduce the revision rate for nasal polyposis? Eur Arch Otorhinolaryngol. 2010 Oct;267(10):1557-61. DOI: 10.1007/s00405-010-1233-z

57. Smith TL, Kern R, Palmer JN, Schlosser R, Chandra RK, Chiu AG, Conley D, Mace JC, Fu RF, Stankiewicz J. Medical therapy vs surgery for chronic rhinosinusitis: a prospective, multi-institutional study with 1-year follow-up. Int Forum Allergy Rhinol. 2013 Jan;3(1):4-9. DOI: 10.1002/alr.21065

58. Scadding GK, Durham SR, Mirakian R, Jones NS, Drake-Lee AB, Ryan D, Dixon TA, Huber PA, Nasser SM; British Society for Allergy and Clinical Immunology. BSACI guidelines for the management of rhinosinusitis and nasal polyposis. Clin Exp Allergy. 2008 Feb;38(2):260-75. DOI: 10.1111/j.1365-2222.2007.02889.x

59. Poetker DM, Reh DD. A comprehensive review of the adverse effects of systemic corticosteroids. Otolaryngol Clin North Am. 2010 Aug;43(4):753-68. DOI: 10.1016/j.otc.2010.04.003

60. Poetker DM, Smith TL. What rhinologists and allergists should know about the medico-legal implications of corticosteroid use: a review of the literature. Int Forum Allergy Rhinol. 2012 Mar-Apr;2(2):95-103. DOI: 10.1002/alr.21016

61. Kidder TM. Malpractice considerations in endoscopic sinus surgery. Curr Opin Otolaryngol Head Neck Surg. 2002;10:14-8. DOI: 10.1002/alr.21016

62. Fokkens W, Lund V, Mullol J; European Position Paper on Rhinosinusitis and Nasal Polyps group. European position paper on rhinosinusitis and nasal polyps 2007. Rhinol Suppl. 2007;20:1-136. Available from: http://www.rhinologyjournal.com/supplement_20.pdf

63. Hopkins C, Browne JP, Slack R, Lund VJ, Topham J, Reeves BC, Copley LP, Brown P, van der Meulen JH. Complications of surgery for nasal polyposis and chronic rhinosinusitis: the results of a national audit in England and Wales. Laryngoscope. 2006 Aug;116(8):1494-9. DOI: 10.1097/01.mlg.0000230399.24306.50

64. Lander L, Roberson DW, Shah RK. Errors and adverse events in otolaryngology. Ear Nose Throat J. 2007 Jul;86(7):370-1.

65. Shah RK, Kentala E, Healy GB, Roberson DW. Classification and consequences of errors in otolaryngology. Laryngoscope. 2004 Aug;114(8):1322-35. DOI: 10.1097/00005537-200408000-00003

66. Bousquet J, Bachert C, Canonica GW, Casale TB, Cruz AA, Lockey RJ, Zuberbier T; Extended Global Allergy and Asthma European Network, World Allergy Organization and Allergic Rhinitis and its Impact on Asthma Study Group. Unmet needs in severe chronic upper airway disease (SCUAD). J Allergy Clin Immunol. 2009 Sep;124(3):428-33. DOI: 10.1016/j.jaci.2009.06.027

67. Brennan TA, Sox CM, Burstin HR. Relation between negligent adverse events and the outcomes of medical-malpractice litigation. N Engl J Med. 1996 Dec;335(26):1963-7. DOI: 10.1056/NEJM199612263352606

68. Rombout J, de Vries N. Complications in sinus surgery and new classification proposal. Am J Rhinol. 2001 Nov-Dec;15(6):363-70.

69. May M, Levine HL, Mester SJ, Schaitkin B. Complications of endoscopic sinus surgery: analysis of 2108 patients--incidence and prevention. Laryngoscope. 1994 Sep;104(9):1080-3. DOI: 10.1288/00005537-199409000-00006

70. Kassam AB, Prevedello DM, Carrau RL, Snyderman CH, Thomas A, Gardner P, Zanation A, Duz B, Stefko ST, Byers K, Horowitz MB. Endoscopic endonasal skull base surgery: analysis of complications in the authors' initial 800 patients. J Neurosurg. 2011 Jun;114(6):1544-68. DOI: 10.3171/2010.10.JNS09406

71. Bhatti MT, Stankiewicz JA. Ophthalmic complications of endoscopic sinus surgery. Surv Ophthalmol. 2003;48:389-402. DOI: 10.3171/2010.10.JNS09406

72. Dalziel K, Stein K, Round A, Garside R, Royle P. Endoscopic sinus surgery for the excision of nasal polyps: A systematic review of safety and effectiveness. Am J Rhinol. 2006;20:506-19. DOI: 10.2500/ajr.2006.20.2923

73. Nguyen QA, Cua DJ, Ng M, Rice DH. Safety of endoscopic sinus surgery in a residency training program. Ear Nose Throat J. 1999 Dec;78(12):898-902, 904.

74. Barroso Ribeiro R, Pinto Reis C, Sousa e Castro S, Pinto Ferreira J, Almeida e Sousa C. Endoscopic sinus surgery: a safe procedure among the less experienced surgeons? Auris Nasus Larynx. 2012 Oct;39(5):490-5. DOI: 10.1016/j.anl.2011.10.010

75. Soyka MB, Holzmann D. Correlation of complications during endoscopic sinus surgery with surgeon skill level and extent of surgery. Am J Rhinol. 2005 May-Jun;19(3):274-81.

76. Stankiewicz JA, Lal D, Connor M, Welch K. Complications in endoscopic sinus surgery for chronic rhinosinusitis: a 25-year experience. Laryngoscope. 2011 Dec;121(12):2684-701. DOI: 10.1002/lary.21446

77. Anderson P, Sindwani R. Safety and efficacy of the endoscopic modified Lothrop procedure: a systematic review and meta-analysis. Laryngoscope. 2009 Sep;119(9):1828-33. DOI: 10.1002/lary.20565

78. Bowden MT, Church CA, Chiu AG, Vaughan WC. Informed consent in functional endoscopic sinus surgery: the patient's perspective. Otolaryngol Head Neck Surg. 2004 Jul;131(1):126-32. DOI: 10.1016/j.otohns.2004.02.027

79. Hosemann W, Kühnel T. Medico-legale Aspekte bei Nasennebenhöhlenoperationen. Teil 1: Komplikationsstatistik, Aufklärung, Operationsbericht, Verhalten nach einem operativen Zwischenfall. Teil 2: Postoperative Überwachung, Operation durch den Ungeübten, Qualitätssicherung. HNO-aktuell. 1994;2:315-19; 355-60.

80. Re M, Massegur H, Magliulo G, Ferrante L, Sciarretta V, Farneti G, Macrì G, Mallardi V, Pasquini E. Traditional endonasal and microscopic sinus surgery complications versus endoscopic sinus surgery complications: a meta-analysis. Eur Arch Otorhinolaryngol. 2012 Mar;269(3):721-9. DOI: 10.1007/s00405-011-1744-2

81. Stankiewicz JA. Complications of endoscopic intranasal ethmoidectomy. Laryngoscope. 1987 Nov;97(11):1270-3. DOI: 10.1288/00005537-198711000-00004

82. Rudert H, Maune S, Mahnke CG. Komplikationen der endonasalen Chirurgie der Nasennebenhöhlen. Inzidenz und Strategien zu ihrer Vermeidung [Complications of endonasal surgery of the paranasal sinuses. Incidence and strategies for prevention]. Laryngorhinootologie. 1997 Apr;76(4):200-15. DOI: 10.1055/s-2007-997414

83. Vanden Abeele D, Clemens A, Tassignon MJ, van de Heyning PH. Blindness due to electrocoagulation following functional endoscopic sinus surgery. J Laryngol Otol. 1996 Mar;110(3):261-4.

84. Kennedy DW, Shaman P, Han W, Selman H, Deems DA, Lanza DC. Complications of ethmoidectomy: a survey of fellows of the American Academy of Otolaryngology-Head and Neck Surgery. Otolaryngol Head Neck Surg. 1994;111:589-99. DOI: 10.1016/S0194-5998(94)70526-7

85. Barkun JS, Aronson JK, Feldman LS, Maddern GJ, Strasberg SM; Balliol Collaboration, Altman DG, Barkun JS, Blazeby JM, Boutron IC, Campbell WB, Clavien PA, Cook JA, Ergina PL, Flum DR, Glasziou P, Marshall JC, McCulloch P, Nicholl J, Reeves BC, Seiler CM, Meakins JL, Ashby D, Black N, Bunker J, Burton M, Campbell M, Chalkidou K, Chalmers I, de Leval M, Deeks J, Grant A, Gray M, Greenhalgh R, Jenicek M, Kehoe S, Lilford R, Littlejohns P, Loke Y, Madhock R, McPherson K, Rothwell P, Summerskill B, Taggart D, Tekkis P, Thompson M, Treasure T, Trohler U, Vandenbroucke J. Evaluation and stages of surgical innovations. Lancet. 2009;374:1089-96. DOI: 10.1016/S0140-6736(09)61083-7

86. Bernal-Sprekelsen M, Sudhoff H, Dazert S. Komplikationen nach endonasalen Eingriffen bei entzündlichen NNH-Erkrankungen. Laryngorhinootologie. 2004;83:23-8.

87. Ecevit MC, Sutay S, Erdag TK. The microdébrider and its complications in endoscopic surgery for nasal polyposis. J Otolaryngol Head Neck Surg. 2008 Apr;37(2):160-4.

88. Lund VJ, Wright A, Yiotakis J. Complications and medicolegal aspects of endoscopic sinus surgery. J R Soc Med. 1997 Aug;90(8):422-8.

89. Maniglia AJ, Chandler JR, Goodwin WJ Jr,Flynn J. Rare complications following ethmoidectomies: a report of eleven cases. Laryngoscope. 1981 Aug;91(8):1234-44. DOI: 10.1288/00005537-198108000-00004

90. Schnipper D, Spiegel JH. Management of intracranial complications of sinus surgery. Otolaryngol Clin North Am. 2004;37:453-42. DOI: 10.1288/00005537-198108000-00004

91. Vleming M, Middelweerd RJ, de Vries N. Complications of endoscopic sinus surgery. Arch Otolaryngol Head Neck Surg. 1992;118:617-23. DOI: 10.1001/archotol.1992.01880060067015

92. Weber R, Keerl R, Hosemann W, Schauss F, Leuwer R, Draf W. Komplikationen mit bleibenden Schäden bei endonasalen Nasennebenhöhlenoperationen--häufiger bei erfahrenen Operateuren [Complications with permanent damage in endonasal paranasal sinus operations--more frequent in experienced surgeons?]. Laryngorhinootologie. 1998 Jul;77(7):398-401. DOI: 10.1055/s-2007-996997

93. Gross RD, Sheridan MF, Burgess LP. Endoscopic sinus surgery complications in residency. Laryngoscope. 1997;107:1080-5. DOI: 10.1097/00005537-199708000-00014

94. Kinsella JB, Calhoun KH, Bradfield JJ, Hokanson JA, Bailey BJ. Complications of endoscopic sinus surgery in a residency training program. Laryngoscope. 1995;105:1029-1032. DOI: 10.1288/00005537-199510000-00003

95. Lippert BM, Ringel K, Stoeter P, Hey O, Mann WJ. Stentgraft-implantation for treatment of internal carotid artery injury during endonasal sinus surgery. Am J Rhinol. 2007 Jul-Aug;21(4):520-4. DOI: 10.2500/ajr.2007.21.3013

96. Weber R, Draf W, Keerl R, Schick B, Saha A. Endonasal microendoscopic pansinusoperation in chronic sinusitis. II. Results and complications. Am J Otolaryngol. 1997;18:247-53. DOI: 10.1016/S0196-0709(97)90004-1

97. Weidenbecher M, Huk WJ, Iro H. Internal carotid artery injury during functional endoscopic sinus surgery and its management. Eur Arch Otorhinolaryngol. 2005 Aug;262(8):640-5. DOI: 10.1007/s00405-004-0888-8

98. Castillo L, Verschuur HP, Poissonnet G, Vaille G, Santini J. Complications of endoscopically guided sinus surgery. Rhinology. 1996 Dec;34(4):215-8.

99. Wright ED, Agrawal S. Impact of perioperative systemic steroids on surgical outcomes in patients with chronic rhinosinusitis with polyposis: evaluation with the novel Perioperative Sinus Endoscopy (POSE) scoring system. Laryngoscope. 2007 Nov;117(11 Pt 2 Suppl 115):1-28. DOI: 10.1097/MLG.0b013e31814842f8

100. Patel ZM, Govindaraj S. The prevention and management of complications in ethmoid sinus surgery. Otolaryngol Clin North Am. 2010 Aug;43(4):855-64. DOI: 10.1016/j.otc.2010.04.010

101. Gondim JA, Almeida JP, Albuquerque LA, Schops M, Gomes E, Ferraz T, Sobreira W, Kretzmann MT. Endoscopic endonasal approach for pituitary adenoma: surgical complications in 301 patients. Pituitary. 2011 Jun;14(2):174-83. DOI: 10.1007/s11102-010-0280-1

102. Ransom ER, Chiu AG. Prevention and management of complications in intracranial endoscopic skull base surgery. Otolaryngol Clin North Am. 2010 Aug;43(4):875-95. DOI: 10.1016/j.otc.2010.04.012

103. Cappabianca P, Cavallo LM, Colao A, de Divitiis E. Surgical complications associated with the endoscopic endonasal transsphenoidal approach for pituitary adenomas. J Neurosurg. 2002 Aug;97(2):293-8. DOI: 10.3171/jns.2002.97.2.0293

104. Han JK, Higgins TS. Management of orbital complications in endoscopic sinus surgery. Curr Opin Otolaryngol Head Neck Surg. 2010 Feb;18(1):32-6. DOI: 10.1097/MOO.0b013e328334a9f1

105. Keerl R, Stankiewicz J, Weber R, Hosemann W, Draf W. Surgical experience and complications during endonasal sinus surgery. Laryngoscope. 1999 Apr;109(4):546-50. DOI: 10.1097/00005537-199904000-00005

106. Meyers RM, Valvassori G. Interpretation of anatomic variations of computed tomography scans of the sinuses: a surgeon's perspective. Laryngoscope. 1998;108:422-25. DOI: 10.1097/00005537-199803000-00020

107. Moulin G, Dessi P, Chagnaud C, Bartoli JM, Vignoli P, Gaubert JY, Castro F, Delannoy L, Sibartie A. Dehiscence of the lamina papyracea of the ethmoid bone: CT findings. AJNR Am J Neuroradiol. 1994 Jan;15(1):151-3.

108. Aletsee C, Deglmann M, Dieler R. Chirurgische Eingriffe an den Nasennebenhöhlen bei Sinusitiden und benignen Tumoren. Indikationen, Konzepte und Komplikationen einer Weiterbildungseinrichtung [Paranasal sinus surgery in chronic sinus disease and benign tumors indications, concepts and complications at a teaching institution]. Laryngorhinootologie. 2003 Jul;82(7):508-13. DOI: 10.1055/s-2003-40898

109. Stankiewicz JA, Chow JM. Two faces of orbital hematoma in intranasal (endoscopic) sinus surgery. Otolaryngol Head Neck Surg. 1999;120:841-7. DOI: 10.1016/S0194-5998(99)70324-4

110. Stankiewicz JA. Blindness and intranasal endoscopic ethmoidectomy: prevention and management. Otolaryngol Head Neck Surg. 1989 Sep;101(3):320-9.

111. Stankiewicz JA. Complications in endoscopic intranasal ethmoidectomy: an update. Laryngoscope. 1989 Jul;99(7 Pt 1):686-90. DOI: 10.1288/00005537-198907000-00004

112. Weber R, Draf W. Komplikationen der endonasalen mikroendoskopischen Siebbeinoperation [Complications of endonasal micro-endoscopic ethmoid bone operation]. HNO. 1992 May;40(5):170-5.

113. Javer AR, Alandejani T. Prevention and management of complications in frontal sinus surgery. Otolaryngol Clin North Am. 2010 Aug;43(4):827-38. DOI: 10.1016/j.otc.2010.04.021

114. Ramakrishnan VR, Palmer JN. Prevention and management of orbital hematoma. Otolaryngol Clin North Am. 2010 Aug;43(4):789-800. DOI: 10.1016/j.otc.2010.04.006

115. Danielsen A, Olofsson J. Endoscopic endonasal sinus surgery: a review of 18 years of practice and long-term follow-up. Eur Arch Otorhinolaryngol. 2006 Dec;263(12):1087-98. DOI: 10.1007/s00405-006-0129-4

116. Vassallo P, Tranfa F, Forte R, D'Aponte A, Strianese D, Bonavolontà G. Ophthalmic complications after surgery for nasal and sinus polyposis. Eur J Ophthalmol. 2001 Jul-Sep;11(3):218-22.

117. White E, Crosse MM. The aetiology and prevention of peri-operative corneal abrasions. Anaesthesia. 1998;53:157-61. DOI: 10.1046/j.1365-2044.1998.00269.x

118. Batra YK, Bali IM. Corneal abrasions during general anesthesia. Anesth Analg. 1977 May-Jun;56(3):363-5. DOI: 10.1213/00000539-197705000-00010

119. Gorton A, Keir J, Tahery J. Steri-strips as an aid to intra-operative monitoring of the eye during endoscopic sinus surgery. J Laryngol Otol. 2009 Feb;123(2):238-9. DOI: 10.1017/S002221510800340X

120. Cuddihy PJ, Whittet H. Eye observation and corneal protection during endonasal surgery. J Laryngol Otol. 2005 Jul;119(7):556-7. DOI: 10.1258/0022215054352234

121. Tzifa KT, Skinner DW. Peri-orbital surgical emphysema following functional endoscopic sinus surgery, during extubation. J Laryngol Otol. 2001 Nov;115(11):916-7. DOI: 10.1258/0022215011909341

122. Dunya IM, Salman SD, Shore JW. Ophthalmic complications of endoscopic ethmoid surgery and their management. Am J Otolaryngol. 1996;17:322-31. DOI: 10.1016/S0196-0709(96)90019-8

123. Sanu A, Jayanthi NV, Mohan AR. Pre-vertebral surgical emphysema following functional endoscopic sinus surgery. J Laryngol Otol. 2006 Nov;120(11):e38. DOI: 10.1017/S0022215106003288

124. Al-Shammari L, Majithia A, Adams A, Chatrath P. Tension pneumo-orbit treated by endoscopic, endonasal decompression: case report and literature review. J Laryngol Otol. 2008 Mar;122(3):e8. DOI: 10.1017/S002221510700165X

125. Fleishman JA, Beck RW, Hoffman RO. Orbital emphysema as an ophthalmologic emergency. Ophthalmology. 1984 Nov;91(11):1389-91.

126. Singh M, Phua VM, Sundar G. Sight-threatening orbital emphysema treated with needle decompression. Clin Experiment Ophthalmol. 2007 May-Jun;35(4):386-7. DOI: 10.1111/j.1442-9071.2007.01494.x

127. Rubinstein A, Riddell CE, Akram I, Ahmado A, Benjamin L. Orbital emphysema leading to blindness following routine functional endoscopic sinus surgery. Arch Ophthalmol. 2005 Oct;123(10):1452. DOI: 10.1001/archopht.123.10.1452

128. Cinčikas D, Ivaškevičius J, Martink÷nas JL, Balseris S. A role of anesthesiologist in reducing surgical bleeding in endoscopic sinus surgery. Medicina (Kaunas). 2010;46:730-4

129. Jacobi K, Rickauer AJ. Prophylaktische Analgesie bei endoskopischen Nasennebenhöhleneingriffen. Hämodynamik, Operationsbedingungen, Stressantwort [Prophylactic analgesia in functional endoscopic sinus surgery. Hemodynamics, surgical conditions, stress response]. Anasthesiol Intensivmed Notfallmed Schmerzther. 1999 May;34(5):278-87. DOI: 10.1055/s-1999-10822

130. Nair S, Collins M, Hung P, Rees G, Close D, Wormald PJ. The effect of beta-blocker premedication on the surgical field during endoscopic sinus surgery. Laryngoscope. 2004 Jun;114(6):1042-6. DOI: 10.1097/00005537-200406000-00016

131. Romlin B, Petruson K, Nilsson K. Moderate superficial hypothermia prolongs bleeding time in humans. Acta Anaesthesiol Scand. 2007 Feb;51(2):198-201. DOI: 10.1111/j.1399-6576.2006.01181.x

132. Fugh-Berman A. Herb-drug interactions. Lancet. 2000;355:134-8. DOI: 10.1016/S0140-6736(99)06457-0

133. Ulualp SO. Complications of endoscopic sinus surgery: appropriate management of complications. Curr Opin Otolaryngol Head Neck Surg. 2008 Jun;16(3):252-9. DOI: 10.1097/MOO.0b013e3282fdc3b2

134. Timperley D, Sacks R, Parkinson RJ, Harvey RJ. Perioperative and intraoperative maneuvers to optimize surgical outcomes in skull base surgery. Otolaryngol Clin North Am. 2010 Aug;43(4):699-730. DOI: 10.1016/j.otc.2010.04.002

135. Welch KC, Palmer JN. Intraoperative emergencies during endoscopic sinus surgery: CSF leak and orbital hematoma. Otolaryngol Clin North Am. 2008 Jun;41(3):581-96, ix-x. DOI: 10.1016/j.otc.2008.01.005

136. Ang-Lee MK, Moss J, Yuan CS. Herbal medicines and perioperative care. JAMA. 2001 Jul;286(2):208-16. DOI: 10.1001/jama.286.2.208

137. Beckert BW, Concannon MJ, Henry SL, Smith DS, Puckett CL. The effect of herbal medicines on platelet function: an in vivo experiment and review of the literature. Plast Reconstr Surg. 2007 Dec;120(7):2044-50. DOI: 10.1097/01.prs.0000295972.18570.0b

138. Greinacher A. Thrombozytenfunktionshemmer und chirurgische Eingriffe. Arzneiverordnung in der Praxis. 2010;37:128-33.

139. Sylvester DC, Coatesworth AP. Antiplatelet therapy in ENT surgery: a review. J Laryngol Otol. 2012 Apr;126(4):331-6. DOI: 10.1017/S0022215111003239

140. Hall R, Mazer CD. Antiplatelet drugs: a review of their pharmacology and management in the perioperative period. Anesth Analg. 2011 Feb;112(2):292-318. DOI: 10.1213/ANE.0b013e318203f38d

141. Korte W, Cattaneo M, Chassot PG, Eichinger S, von Heymann C, Hofmann N, Rickli H, Spannagl M, Ziegler B, Verheugt F, Huber K. Peri-operative management of antiplatelet therapy in patients with coronary artery disease: joint position paper by members of the working group on Perioperative Haemostasis of the Society on Thrombosis and Haemostasis Research (GTH), the working group on Perioperative Coagulation of the Austrian Society for Anesthesiology, Resuscitation and Intensive Care (ÖGARI) and the Working Group Thrombosis of the European Society for Cardiology (ESC). Thromb Haemost. 2011 May;105(5):743-9. DOI: 10.1160/TH10-04-0217

142. Schouten O, Bax JJ, Poldermans D. Management of patients with cardiac stents undergoing noncardiac surgery. Curr Opin Anaesthesiol. 2007 Jun;20(3):274-8. DOI: 10.1097/ACO.0b013e328105dac5

143. Athanasiadis T, Beule A, Embate J, Steinmeier E, Field J, Wormald PJ. Standardized video-endoscopy and surgical field grading scale for endoscopic sinus surgery: a multi-centre study. Laryngoscope. 2008 Feb;118(2):314-9. DOI: 10.1097/MLG.0b013e318157f764

144. Boezaart AP, van der Merwe J, Coetzee A. Comparison of sodium nitroprusside- and esmolol-induced controlled hypotension for functional endoscopic sinus surgery. Can J Anaesth. 1995 May;42(5 Pt 1):373-6. DOI: 10.1007/BF03015479

145. Orlandi RR, Lanza DC. Is nasal packing necessary following endoscopic sinus surgery? Laryngoscope. 2004 Sep;114(9):1541-4. DOI: 10.1097/00005537-200409000-00007

146. Ko MT, Chuang KC, Su CY. Multiple analyses of factors related to intraoperative blood loss and the role of reverse Trendelenburg position in endoscopic sinus surgery. Laryngoscope. 2008 Sep;118(9):1687-91. DOI: 10.1097/MLG.0b013e31817c6b7c

147. Wormald PJ, van Renen G, Perks J, Jones JA, Langton-Hewer CD. The effect of the total intravenous anesthesia compared with inhalational anesthesia on the surgical field during endoscopic sinus surgery. Am J Rhinol. 2005 Sep-Oct;19(5):514-20.

148. Albu S, Gocea A, Mitre I. Preoperative treatment with topical corticoids and bleeding during primary endoscopic sinus surgery. Otolaryngol Head Neck Surg. 2010 Oct;143(4):573-8. DOI: 10.1016/j.otohns.2010.06.921

149. Sieskiewicz A, Olszewska E, Rogowski M, Grycz E. Preoperative corticosteroid oral therapy and intraoperative bleeding during functional endoscopic sinus surgery in patients with severe nasal polyposis: a preliminary investigation. Ann Otol Rhinol Laryngol. 2006 Jul;115(7):490-4.

150. Lee HY, Kim HU, Kim SS, Son EJ, Kim JW, Cho NH, Kim KS, Lee JG, Chung IH, Yoon JH. Surgical anatomy of the sphenopalatine artery in lateral nasal wall. Laryngoscope. 2002 Oct;112(10):1813-8. DOI: 10.1097/00005537-200210000-00020

151. Higgins TS, Hwang PH, Kingdom TT, Orlandi RR, Stammberger H, Han JK. Systematic review of topical vasoconstrictors in endoscopic sinus surgery. Laryngoscope. 2011 Feb;121(2):422-32. DOI: 10.1002/lary.21286

152. Huang TW, Liu CM, Cheng PW, Yang CH. Posterior ischemic optic neuropathy following endoscopic sinus surgery. Otolaryngol Head Neck Surg. 2003;129:448-50. DOI: 10.1016/S0194-5998(03)00624-7

153. Anderhuber W, Walch C, Nemeth E, Semmelrock HJ, Berghold A, Ranftl G, Stammberger H. Plasma adrenaline concentrations during functional endoscopic sinus surgery. Laryngoscope. 1999;109:204-7. DOI: 10.1097/00005537-199902000-00006

154. Orlandi RR, Warrier S, Sato S, Han JK. Concentrated topical epinephrine is safe in endoscopic sinus surgery. Am J Rhinol Allergy. 2010 Mar-Apr;24(2):140-2. DOI: 10.2500/ajra.2010.24.3454

155. Crawley BK, Barkdull GC, Dent S, Bishop M, Davidson TM. Relative hypotension and image guidance: tools for training in sinus surgery. Arch Otolaryngol Head Neck Surg. 2009 Oct;135(10):994-9. DOI: 10.1001/archoto.2009.139

156. Leunig A. Vermeidung von und Umgang mit Blutungen während endoskopischer Nasennebenhöhlenchirurgie [Avoiding and dealing with bleeding during endoscopic sinus surgery]. Laryngorhinootologie. 2006 Apr;85(4):249-52. DOI: 10.1055/s-2006-939824

157. Cohen-Kerem R, Brown S, Villaseñor LV, Witterick I. Epinephrine/Lidocaine injection vs. saline during endoscopic sinus surgery. Laryngoscope. 2008 Jul;118(7):1275-81. DOI: 10.1097/MLG.0b013e31816dd2d9

158. Javer AR, Gheriani H, Mechor B, Flamer D, Genoway K, Yunker WK. Effect of intraoperative injection of 0.25% bupivacaine with 1:200,000 epinephrine on intraoperative blood loss in FESS. Am J Rhinol Allergy. 2009 Jul-Aug;23(4):437-41. DOI: 10.2500/ajra.2009.23.3339

159. Lee TJ, Huang CC, Chang PH, Chang CJ, Chen YW. Hemostasis during functional endoscopic sinus surgery: the effect of local infiltration with adrenaline. Otolaryngol Head Neck Surg. 2009 Feb;140(2):209-14. DOI: 10.1016/j.otohns.2008.09.029

160. John G, Low JM, Tan PE, van Hasselt CA. Plasma catecholamine levels during functional endoscopic sinus surgery. Clin Otolaryngol Allied Sci. 1995 Jun;20(3):213-5. DOI: 10.1111/j.1365-2273.1995.tb01850.x

161. Yang JJ, Li WY, Jil Q, Wang ZY, Sun J, Wang QP, Li ZQ, Xu JG. Local anesthesia for functional endoscopic sinus surgery employing small volumes of epinephrine-containing solutions of lidocaine produces profound hypotension. Acta Anaesthesiol Scand. 2005 Nov;49(10):1471-6. DOI: 10.1111/j.1399-6576.2005.00869.x

162. Shah RK, Hoy E, Roberson DW, Nielsen D. Errors with concentrated epinephrine in otolaryngology. Laryngoscope. 2008 Nov;118(11):1928-30. DOI: 10.1097/MLG.0b013e318180ec8d

163. Sartcaoglu F, Celiker V, Basgul E, Yapakci O, Aypar U. The effect of hypotensive anaesthesia on cognitive functions and recovery at endoscopic sinus surgery. Eur J Anaesthesiol. 2005;22:157-9. DOI: 10.1017/S0265021505230284

164. Jacobi KE, Böhm BE, Rickauer AJ, Jacobi C, Hemmerling TM. Moderate controlled hypotension with sodium nitroprusside does not improve surgical conditions or decrease blood loss in endoscopic sinus surgery. J Clin Anesth. 2000;12:202-7. DOI: 10.1016/S0952-8180(00)00145-8

165. Eberhart LH, Folz BJ, Wulf H, Geldner G. Intravenous anesthesia provides optimal surgical conditions during microscopic and endoscopic sinus surgery. Laryngoscope. 2003 Aug;113(8):1369-73. DOI: 10.1097/00005537-200308000-00019

166. Blackwell KE, Ross DA, Kapur P, Calcaterra TC. Propofol for maintenance of general anesthesia: a technique to limit blood loss during endoscopic sinus surgery. Am J Otolaryngol. 1993;14:262-6. DOI: 10.1016/0196-0709(93)90072-F

167. Sivaci R, Yilmaz MD, Balci C, Erincler T, Unlu H. Comparison of propofol and sevoflurane anesthesia by means of blood loss during endoscopic sinus surgery. Saudi Med J. 2004 Dec;25(12):1995-8.

168. Pavlin JD, Colley PS, Weymuller EA Jr, Van Norman G, Gunn HC, Koerschgen ME. Propofol versus isoflurane for endoscopic sinus surgery. Am J Otolaryngol. 1999;20:96-101. DOI: 10.1016/S0196-0709(99)90018-2

169. Beule AG, Wilhelmi F, Kühnel TS, Hansen E, Lackner KJ, Hosemann W. Propofol versus sevoflurane: bleeding in endoscopic sinus surgery. Otolaryngol Head Neck Surg. 2007 Jan;136(1):45-50. DOI: 10.1016/j.otohns.2006.08.006

170. Boezaart AP, van der Merwe J, Coetzee AR. Re: Moderate controlled hypotension with sodium nitroprusside does not improve surgical conditions or decrease blood loss in endoscopic sinus surgery. J Clin Anesth. 2001;13:319-320. DOI: 10.1016/S0952-8180(01)00247-1

171. Eberhart LH, Kussin A, Arndt C, Lange H, Folz BJ, Werner JA, Wulf H, Kill C. Effect of a balanced anaesthetic technique using desflurane and remifentanil on surgical conditions during microscopic and endoscopic sinus surgery. Rhinology. 2007 Mar;45(1):72-8.

172. Nekhendzy V, Lemmens HJ, Vaughan WC, Hepworth EJ, Chiu AG, Church CA, Brock-Utne JG. The effect of deliberate hypercapnia and hypocapnia on intraoperative blood loss and quality of surgical field during functional endoscopic sinus surgery. Anesth Analg. 2007 Nov;105(5):1404-9, table of contents. DOI: 10.1213/01.ane.0000282781.56025.52

173. Yaniv E, Shvero J, Hadar T. Hemostatic effect of tranexamic acid in elective nasal surgery. Am J Rhinol. 2006 Mar-Apr;20(2):227-9.

174. Alimian M, Mohseni M. The effect of intravenous tranexamic acid on blood loss and surgical field quality during endoscopic sinus surgery: a placebo-controlled clinical trial. J Clin Anesth. 2011 Dec;23(8):611-5. DOI: 10.1016/j.jclinane.2011.03.004

175. Athanasiadis T, Beule AG, Wormald PJ. Effects of topical antifibrinolytics in endoscopic sinus surgery: a pilot randomized controlled trial. Am J Rhinol. 2007 Nov-Dec;21(6):737-42. DOI: 10.2500/ajr.2007.21.3097

176. Solares CA, Ong YK, Carrau RL, Fernandez-Miranda J, Prevedello DM, Snyderman CH, Kassam AB. Prevention and management of vascular injuries in endoscopic surgery of the sinonasal tract and skull base. Otolaryngol Clin North Am. 2010 Aug;43(4):817-25. DOI: 10.1016/j.otc.2010.04.008

177. Beule AG, Weber RK, Kaftan H, Hosemann W. Ubersicht: Art und Wirkung geläufiger Nasentamponaden [Review: pathophysiology and methodology of nasal packing]. Laryngorhinootologie. 2004 Aug;83(8):534-51; quiz 553-6. DOI: 10.1055/s-2004-825695

178. Weber RK. Nasentamponade nach FESS--ein Auslaufmodell [Nasal packing after FESS--time is over?]. Laryngorhinootologie. 2009 Jun;88(6):379-84. DOI: 10.1055/s-0029-1220765

179. Kastl KG, Betz CS, Siedek V, Leunig A. Effect of carboxymethylcellulose nasal packing on wound healing after functional endoscopic sinus surgery. Am J Rhinol Allergy. 2009 Jan-Feb;23(1):80-4. DOI: 10.2500/ajra.2009.23.3267

180. Wang YP, Wang MC, Chen YC, Leu YS, Lin HC, Lee KS. The effects of Vaseline gauze strip, Merocel, and Nasopore on the formation of synechiae and excessive granulation tissue in the middle meatus and the incidence of major postoperative bleeding after endoscopic sinus surgery. J Chin Med Assoc. 2011 Jan;74(1):16-21. DOI: 10.1016/j.jcma.2010.09.001

181. Kassam A, Snyderman CH, Carrau RL, Gardner P, Mintz A. Endoneurosurgical hemostasis techniques: lessons learned from 400 cases. Neurosurg Focus. 2005 Jul;19(1):E7. DOI: 10.3171/foc.2005.19.1.8

182. Singh A, Germanwala AV. Management of postoperative complications of skull base surgery. Op Tech Otolaryngol Head Neck Surg. 2011;22:237-245. DOI: 10.1016/j.otot.2011.09.007

183. Sprinzl GM, Menzler A, Eckel HE, Sittel C, Koebke J, Thumfart WF. Bone density measurements of the paranasal sinuses on plastinated whole-organ sections: anatomic data to prevent complications in endoscopic sinus surgery. Laryngoscope. 1999;109:400-406. DOI: 10.1097/00005537-199903000-00011

184. White PS, Nassif R, Saleh H, Drew T. Pilot study of a device for measuring instrument forces during endoscopic sinus surgery. Acta Otolaryngol. 2004;124:176178. DOI: 10.1080/00016480410016568

185. Zeifer B. Sinusitis: postoperative changes and surgical complications. Semin Ultrasound CT MRI. 2002;23:475-491. DOI: 10.1016/S0887-2171(02)90038-7

186. Kainz J, Stammberger H. Das Dach des vorderen Siebbeines: Ein Locus minoris resistentiae der vorderen Schädelbasis. Laryngorhinootologie. 1988;67:142-149. DOI: 10.1055/s-2007-998473

187. Lebowitz RA, Terk A, Jacobs JB, Holliday RA. Asymmetry of the ethmoid roof: analysis using coronal computed tomography. Laryngoscope. 2001 Dec;111(12):2122-4. DOI: 10.1097/00005537-200112000-00007

188. Dessi P, Moulin G, Triglia JM, Zanaret M, Cannoni M. Difference in the height of the right and left ethmoidal roofs: a possible risk factor for ethmoidal surgery. Prospective study of 150 CT scans. J Laryngol Otol. 1994 Mar;108(3):261-2. DOI: 10.1017/S0022215100126477

189. Heaton CM, Goldberg AN, Pletcher SD, Glastonbury CM. Sinus anatomy associated with inadvertent cerebrospinal fluid leak during functional endoscopic sinus surgery. Laryngoscope. 2012 Jul;122(7):1446-9. DOI: 10.1002/lary.23305

190. Lee JC, Song YJ, Chung YS, Lee BJ, Jang YJ. Height and shape of the skull base as risk factors for skull base penetration during endoscopic sinus surgery. Ann Otol Rhinol Laryngol. 2007 Mar;116(3):199-205.

191. Hegazy HM, Carrau RL, Snyderman CH, Kassam A, Zweig J. Transnasal endoscopic repair of cerebrospinal fluid rhinorrhea: a meta-analysis. Laryngoscope. 2000 Jul;110(7):1166-72. DOI: 10.1097/00005537-200007000-00019

192. Schlosser RJ, Bolger WE. Nasal cerebrospinal fluid leaks: critical review and surgical considerations. Laryngoscope. 2004 Feb;114(2):255-65. DOI: 10.1097/00005537-200402000-00015

193. Grevers G. Anterior skull base trauma during endoscopic sinus surgery for nasal polyposis preferred sites for iatrogenic injuries. Rhinology. 2001 Mar;39(1):1-4.

194. Stammberger H, Greistorfer K, Wolf G, Luxenberger W. Operative Verschluss von Liquorfisteln der vorderen Schädelbasis unter intrathekaler Natriumfluoreszeinanwendung [Surgical occlusion of cerebrospinal fistulas of the anterior skull base using intrathecal sodium fluorescein]. Laryngorhinootologie. 1997 Oct;76(10):595-607. DOI: 10.1055/s-2007-997487

195. Platt MP, Shaye D, Parnes SM. Management of unexpected cerebrospinal fluid fistulae during endoscopic sinus surgery. Am J Rhinol. 2007 Sep-Oct;21(5):611-4. DOI: 10.2500/ajr.2007.21.3073

196. Bachmann G, Djenabi U, Jungehülsing M, Petereit H, Michel O. Incidence of occult cerebrospinal fluid fistula during paranasal sinus surgery. Arch Otolaryngol Head Neck Surg. 2002;128:1299-1302. DOI: 10.1001/archotol.128.11.1299

197. Stankiewicz JA, Chow JM. The low skull base: an invitation to disaster. Am J Rhinol. 2004 Jan-Feb;18(1):35-40.

198. Grigorian A, Rajaraman V, Hunt CD. Traumatic intracranial aneurysms complicating anterior skull base surgery. J Craniomaxillofac Trauma. 1998;4(4):10-4.

199. Hopkins C, Dhillon S, Rogers G, Roberts D. Don't sue the surgeon: remineralisation of the skull base or a defect that never existed? J Laryngol Otol. 2011;7:1-4

200. Hudgins PA, Browning DG, Gallups J, Gussack GS, Peterman SB, Davis PC, Silverstein AM, Beckett WW, Hoffman JC Jr,. Endoscopic paranasal sinus surgery: radiographic evaluation of severe complications. AJNR Am J Neuroradiol. 1992 Jul-Aug;13(4):1161-7.

201. Martin TJ, Loehrl TA. Endoscopic CSF leak repair. Curr Opin Otolaryngol Head Neck Surg. 2007 Feb;15(1):35-9. DOI: 10.1097/MOO.0b013e3280123fce

202. Meco C, Oberascher G. Comprehensive algorithm for skull base dural lesion and cerebrospinal fluid fistula diagnosis. Laryngoscope. 2004 Jun;114(6):991-9. DOI: 10.1097/00005537-200406000-00007

203. Locatelli D, Rampa F, Acchiardi I, Bignami M, De Bernardi F, Castelnuovo P. Endoscopic endonasal approaches for repair of cerebrospinal fluid leaks: nine-year experience. Neurosurgery. 2006 Apr;58(4 Suppl 2):ONS-246-56; discussion ONS-256-7.

204. Tabaee A, Placantonakis DG, Schwartz TH, Anand VK. Intrathecal fluorescein in endoscopic skull base surgery. Otolaryngol Head Neck Surg. 2007 Aug;137(2):316-20. DOI: 10.1016/j.otohns.2006.11.012

205. Carrau RL, Snyderman CH, Kassam AB. The management of cerebrospinal fluid leaks in patients at risk for high-pressure hydrocephalus. Laryngoscope. 2005 Feb;115(2):205-12. DOI: 10.1097/01.mlg.0000154719.62668.70

206. Lloyd KM, DelGaudio JM, Hudgins PA. Imaging of skull base cerebrospinal fluid leaks in adults. Radiology. 2008 Sep;248(3):725-36. DOI: 10.1148/radiol.2483070362

207. Shetty PG, Shroff MM, Sahani DV, Kirtane MV. Evaluation of high-resolution CT and MR cisternography in the diagnosis of cerebrospinal fluid fistula. AJNR Am J Neuroradiol. 1998 Apr;19(4):633-9.

208. Wise SK, Harvey RJ, Neal JG, Patel SJ, Frankel BM, Schlosser RJ. Factors contributing to failure in endoscopic skull base defect repair. Am J Rhinol Allergy. 2009 Mar-Apr;23(2):185-91. DOI: 10.2500/ajra.2009.23.3293

209. Pletcher SD, Hoxworth JM, Goldberg AN, Murr AH, Glastonbury CM. Computed tomography imaging of the paranasal sinuses: direct versus reformatted coronal images. Otolaryngol Head Neck Surg. 2008 Jun;138(6):710-4. DOI: 10.1016/j.otohns.2008.03.001

210. La Fata V, McLean N, Wise SK, DelGaudio JM, Hudgins PA. CSF leaks: correlation of high-resolution CT and multiplanar reformations with intraoperative endoscopic findings. AJNR Am J Neuroradiol. 2008 Mar;29(3):536-41. DOI: 10.3174/ajnr.A0885

211. Bachmann-Harildstad G. Diagnostic values of beta-2 transferrin and beta-trace protein as markers for cerebrospinal fluid fistula. Rhinology. 2008 Jun;46(2):82-5.

212. Meco C, Arrer E, Oberascher G. Efficacy of cerebrospinal fluid fistula repair: sensitive quality control using the beta-trace protein test. Am J Rhinol. 2007 Nov-Dec;21(6):729-36. DOI: 10.2500/ajr.2007.21.3105

213. Reiber H, Walther K, Althaus H. Beta-trace protein as sensitive marker for CSF rhinorhea and CSF otorhea. Acta Neurol Scand. 2003;108:359-62. DOI: 10.1034/j.1600-0404.2003.00173.x

214. Schnabel C, Di Martino E, Gilsbach JM, Riediger D, Gressner AM, Kunz D. Comparison of beta2-transferrin and beta-trace protein for detection of cerebrospinal fluid in nasal and ear fluids. Clin Chem. 2004 Mar;50(3):661-3. DOI: 10.1373/clinchem.2003.024158

215. Warnecke A, Averbeck T, Wurster U, Harmening M, Lenarz T, Stöver T. Diagnostic relevance of beta2-transferrin for the detection of cerebrospinal fluid fistulas. Arch Otolaryngol Head Neck Surg. 2004 Oct;130(10):1178-84. DOI: 10.1001/archotol.130.10.1178

216. Arrer E, Meco C, Oberascher G, Piotrowski W, Albegger K, Patsch W. Beta-trace protein as a marker for cerebrospinal fluid rhinorrhea. Clin Chem. 2002 Jun;48(6 Pt 1):939-41.

217. Meco C, Oberascher G, Arrer E, Moser G, Albegger K. Beta-trace protein test: new guidelines for the reliable diagnosis of cerebrospinal fluid fistula. Otolaryngol Head Neck Surg. 2003;129:508-17. DOI: 10.1016/S0194-5998(03)01448-7

218. Seth R, Rajasekaran K, Benninger MS, Batra PS. The utility of intrathecal fluorescein in cerebrospinal fluid leak repair. Otolaryngol Head Neck Surg. 2010 Nov;143(5):626-32. DOI: 10.1016/j.otohns.2010.07.011

219. Wolf G, Greistorfer K, Stammberger H. Der endoskopische Nachweis von Liquorfisteln mittels der Fluoreszeintechnik. Ein Erfahrungsbericht über 925 Fälle [Endoscopic detection of cerebrospinal fluid fistulas with a fluorescence technique. Report of experiences with over 925 cases]. Laryngorhinootologie. 1997 Oct;76(10):588-94. DOI: 10.1055/s-2007-997486

220. Placantonakis DG, Tabaee A, Anand VK, Hiltzik D, Schwartz TH. Safety of low-dose intrathecal fluorescein in endoscopic cranial base surgery. Neurosurgery. 2007 Sep;61(3 Suppl):161-5; discussion 165-6. DOI: 10.1227/01.neu.0000289729.20083.dc

221. Senior BA, Jafri K, Benninger M. Safety and efficacy of endoscopic repair of CSF leaks and encephaloceles: a survey of the members of the American Rhinologic Society. Am J Rhinol. 2001;15:21-25. DOI: 10.2500/105065801781329356

222. Casiano RR, Jassir D. Endoscopic cerebrospinal fluid rhinorrhea repair: is a lumbar drain necessary? Otolaryngol Head Neck Surg. 1999 Dec;121(6):745-50. DOI: 10.1053/hn.1999.v121.a98754

223. Schaberg MR, Anand VK, Schwartz TH. 10 pearls for safe endoscopic skull base surgery. Otolaryngol Clin North Am. 2010 Aug;43(4):945-54. DOI: 10.1016/j.otc.2010.04.022

224. Keerl R, Weber RK, Draf W, Wienke A, Schaefer SD. Use of sodium fluorescein solution for detection of cerebrospinal fluid fistulas: an analysis of 420 administrations and reported complications in Europe and the United States. Laryngoscope. 2004 Feb;114(2):266-72. DOI: 10.1097/00005537-200402000-00016

225. Saafan ME, Ragab SM, Albirmawy OA. Topical intranasal fluorescein: the missing partner in algorithms of cerebrospinal fluid fistula detection. Laryngoscope. 2006 Jul;116(7):1158-61. DOI: 10.1097/01.mlg.0000217532.77298.a8

226. McMains KC, Gross CW, Kountakis SE. Endoscopic management of cerebrospinal fluid rhinorrhea. Laryngoscope. 2004 Oct;114(10):1833-7. DOI: 10.1097/00005537-200410000-00029

227. Mirza S, Thaper A, McClelland L, Jones NS. Sinonasal cerebrospinal fluid leaks: management of 97 patients over 10 years. Laryngoscope. 2005 Oct;115(10):1774-7. DOI: 10.1097/01.mlg.0000175679.68452.75

228. DelGaudio JM, Ingley AP. Treatment of pneumocephalus after endoscopic sinus and microscopic skull base surgery. Am J Otolaryngol. 2010 Jul-Aug;31(4):226-30. DOI: 10.1016/j.amjoto.2009.02.012

229. Bernal-Sprekelsen M, Bleda-Vázquez C, Carrau RL. Ascending meningitis secondary to traumatic cerebrospinal fluid leaks. Am J Rhinol. 2000;14:257-9. DOI: 10.2500/105065800779954473

230. Wagenmann M, Schipper J. Die transnasale Route zur Schädelbasis. Von der Nasennebenhöhlenchirurgie zur Schädelbasischirurgie. Laryngorhinootol. 2011;90:11-5.

231. Zweig JL, Carrau RL, Celin SE, Schaitkin BM, Pollice PA, Snyderman CH, Kassam A, Hegazy H. Endoscopic repair of cerebrospinal fluid leaks to the sinonasal tract: predictors of success. Otolaryngol Head Neck Surg. 2000 Sep;123(3):195-201. DOI: 10.1067/mhn.2000.107452

232. Hosemann W, Goede U, Sauer M. Wound healing of mucosal autografts for frontal cerebrospinal fluid leaks--clinical and experimental investigations. Rhinology. 1999 Sep;37(3):108-12.

233. Wang L, Kim J, Heilman CB. Intracranial mucocele as a complication of endoscopic repair of cerebrospinal fluid rhinorrhea: case report. Neurosurgery. 1999 Nov;45(5):1243-5; discussion 1245-6. DOI: 10.1097/00006123-199911000-00052

234. Gassner HG, Ponikau JU, Sherris DA, Kern EB. CSF rhinorrhea: 95 consecutive surgical cases with long term follow-up at the Mayo Clinic. Am J Rhinol. 1999;13:439-47. DOI: 10.2500/105065899781329610

235. Prickett KK, Wise SK, Delgaudio JM. Choice of graft material and postoperative healing in endoscopic repair of cerebrospinal fluid leak. Arch Otolaryngol Head Neck Surg. 2011 May;137(5):457-61. DOI: 10.1001/archoto.2011.12

236. Chang PJ, Sung YH, Tsai YC, Fang SY, Chen HH. Continuous cerebrospinal fluid drainage using a lumbar subarachnoid catheter for cerebrospinal fluid rhinorrhea after functional endoscopic sinus surgery. Acta Anaesthesiol Sin. 2002 Jun;40(2):97-9.

237. Kassam A, Carrau RL, Snyderman CH, Gardner P, Mintz A. Evolution of reconstructive techniques following endoscopic expanded endonasal approaches. Neurosurg Focus. 2005 Jul;19(1):E8.

238. Maier W, Laszig R. Komplikationen der endonasalen Nebenhöhlenchirurgie--diagnostische und therapeutische Konsequenzen [Complications of endonasal paranasal sinus surgery--diagnostic and therapeutic consequences]. Laryngorhinootologie. 1998 Jul;77(7):402-9. DOI: 10.1055/s-2007-996998

239. Weber R, Keerl R, Draf W, Schick B, Mosler P, Saha A. Management of dural lesions occurring during endonasal sinus surgery. Arch Otolaryngol Head Neck Surg. 1996;122:732-6. DOI: 10.1001/archotol.1996.01890190028008

240. Moralee SJ. Should prophylactic antibiotics be used in the management of cerebrospinal fluid rhinorrhoea following endoscopic sinus surgery? A review of the literature. Clin Otolaryngol Allied Sci. 1995 Apr;20(2):100-2. DOI: 10.1111/j.1365-2273.1995.tb00023.x

241. Brodie HA. Prophylactic antibiotics for posttraumatic cerebrospinal fluid fistulae. A meta-analysis. Arch Otolaryngol Head Neck Surg. 1997 Jul;123(7):749-52. DOI: 10.1001/archotol.1997.01900070093016

242. Daudia A, Biswas D, Jones NS. Risk of meningitis with cerebrospinal fluid rhinorrhea. Ann Otol Rhinol Laryngol. 2007 Dec;116(12):902-5.

243. Eftekhar B, Ghodsi M, Nejat F, Ketabchi E, Esmaeeli B. Prophylactic administration of ceftriaxone for the prevention of meningitis after traumatic pneumocephalus: results of a clinical trial. J Neurosurg. 2004 Nov;101(5):757-61. DOI: 10.3171/jns.2004.101.5.0757

244. Platt MP, Parnes SM. Management of unexpected cerebrospinal fluid leak during endoscopic sinus surgery. Curr Opin Otolaryngol Head Neck Surg. 2009 Feb;17(1):28-32. DOI: 10.1097/MOO.0b013e32831fb593

245. Caballero N, Bhalla V, Stankiewicz JA, Welch KC. Effect of lumbar drain placement on recurrence of cerebrospinal rhinorrhea after endoscopic repair. Int Forum Allergy Rhinol. 2012 May-Jun;2(3):222-6. DOI: 10.1002/alr.21023

246. Eljamel MS, Foy PM. Acute traumatic CSF fistulae: the risk of intracranial infection. Br J Neurosurg. 1990;4:381-5. DOI: 10.3109/02688699008992759

247. Bernal-Sprekelsen M, Alobid I, Mullol J, Trobat F, Tomás-Barberán M. Closure of cerebrospinal fluid leaks prevents ascending bacterial meningitis. Rhinology. 2005 Dec;43(4):277-81.

248. Harvey RJ, Smith JE, Wise SK, Patel SJ, Frankel BM, Schlosser RJ. Intracranial complications before and after endoscopic skull base reconstruction. Am J Rhinol. 2008 Sep-Oct;22(5):516-21. DOI: 10.2500/ajr.2008.22.3223

249. Harvey RJ, Parmar P, Sacks R, Zanation AM. Endoscopic skull base reconstruction of large dural defects: a systematic review of published evidence. Laryngoscope. 2012 Feb;122(2):452-9. DOI: 10.1002/lary.22475

250. Kassam AB, Thomas A, Carrau RL, Snyderman CH, Vescan A, Prevedello D, Mintz A, Gardner P. Endoscopic reconstruction of the cranial base using a pedicled nasoseptal flap. Neurosurgery. 2008 Jul;63(1 Suppl 1):ONS44-52; discussion ONS52-3.

251. Dallan I, Lenzi R, Muscatello L, Bignami M, Battaglia P, Castelnuovo P. Subdural haematoma after endoscopic skull base surgery: case report and lesson learned. Clin Neurol Neurosurg. 2011 Jul;113(6):496-8. DOI: 10.1016/j.clineuro.2011.01.009

252. Hadad G, Bassagasteguy L, Carrau RL, Mataza JC, Kassam A, Snyderman CH, Mintz A. A novel reconstructive technique after endoscopic expanded endonasal approaches: vascular pedicle nasoseptal flap. Laryngoscope. 2006 Oct;116(10):1882-6. DOI: 10.1097/01.mlg.0000234933.37779.e4

253. Fortes FS, Carrau RL, Snyderman CH, Prevedello D, Vescan A, Mintz A, Gardner P, Kassam AB. The posterior pedicle inferior turbinate flap: a new vascularized flap for skull base reconstruction. Laryngoscope. 2007 Aug;117(8):1329-32. DOI: 10.1097/mlg.0b013e318062111f

254. Simal Julián JA, Miranda Lloret P, Cárdenas Ruiz-Valdepeñas E, Barges Coll J, Beltrán Giner A, Botella Asunción C. Middle turbinate vascularized flap for skull base reconstruction after an expanded endonasal approach. Acta Neurochir (Wien). 2011 Sep;153(9):1827-32. DOI: 10.1007/s00701-011-1064-8

255. Zanation AM, Snyderman CH, Carrau RL, Kassam AB, Gardner PA, Prevedello DM. Minimally invasive endoscopic pericranial flap: a new method for endonasal skull base reconstruction. Laryngoscope. 2009 Jan;119(1):13-8. DOI: 10.1002/lary.20022

256. Fortes FS, Carrau RL, Snyderman CH, Kassam A, Prevedello D, Vescan A, Mintz A, Gardner P. Transpterygoid transposition of a temporoparietal fascia flap: a new method for skull base reconstruction after endoscopic expanded endonasal approaches. Laryngoscope. 2007 Jun;117(6):970-6. DOI: 10.1097/MLG.0b013e3180471482

257. Oliver CL, Hackman TG, Carrau RL, Snyderman CH, Kassam AB, Prevedello DM, Gardner P. Palatal flap modifications allow pedicled reconstruction of the skull base. Laryngoscope. 2008 Dec;118(12):2102-6. DOI: 10.1097/MLG.0b013e318184e719

258. Patel MR, Stadler ME, Snyderman CH, Carrau RL, Kassam AB, Germanwala AV, Gardner P, Zanation AM. How to choose? Endoscopic skull base reconstructive options and limitations. Skull Base. 2010 Nov;20(6):397-404. DOI: 10.1055/s-0030-1253573

259. Bleier BS, Wang EW, Vandergrift WA 3rd,Schlosser RJ. Mucocele rate after endoscopic skull base reconstruction using vascularized pedicled flaps. Am J Rhinol Allergy. 2011 May-Jun;25(3):186-7. DOI: 10.2500/ajra.2011.25.3587

260. Vaezeafshar R, Hwang PH, Harsh G, Turner JH. Mucocele formation under pedicled nasoseptal flap. Am J Otolaryngol. 2012 Sep-Oct;33(5):634-6. DOI: 10.1016/j.amjoto.2012.05.003

261. Ransom ER, Palmer JN, Kennedy DW, Chiu AG. Assessing risk/benefit of lumbar drain use for endoscopic skull-base surgery. Int Forum Allergy Rhinol. 2011 May-Jun;1(3):173-7. DOI: 10.1002/alr.20026

262. Mann WJ, Amedee RG, Jemma M. An assessment of radiologic discrepancies in patients with paranasal sinus disease. Am J Rhinol. 1992;6: 211-3. DOI: 10.2500/105065892781976673

263. Pöckler C, Brambs HJ, Plinkert P. Computertomographie der Nasennebenhöhlen vor endonasaler Operation [Computed tomography of the paranasal sinus prior to endonasal surgery]. Radiologe. 1994 Feb;34(2):79-83.

264. Wienke A. Stellt die Verletzung der harten Hirnhaut mit nachfolgendem Abfilessen von Hirnwasser einen Behandlungsfehler dar? Urteil des LG Bonn vom 12.8.1998-9 O 135/97 [Is injury to the dura mater with subsequent loss of cerebral spinal fluid a treatment error? The decision of LG Bonn on August 12, 1998-9 O 135/97]. Laryngorhinootologie. 1999 Jun;78(6):351-2. DOI: 10.1055/s-2007-996885

265. Khalil HS, Eweiss AZ, Clifton N. Radiological findings in patients undergoing revision endoscopic sinus surgery: a retrospective case series study. BMC Ear Nose Throat Disord. 2011;11:4. DOI: 10.1186/1472-6815-11-4

266. Mendelsohn D, Jeremic G, Wright ED, Rotenberg BW. Revision rates after endoscopic sinus surgery: a recurrence analysis. Ann Otol Rhinol Laryngol. 2011 Mar;120(3):162-6.

267. Mair EA, Bolger WE, Breisch EA. Sinus and facial growth after pediatric endoscopic sinus surgery. Arch Otolaryngol Head Neck Surg. 1995;121: 547-52. DOI: 10.1001/archotol.1995.01890050041008

268. Platt MP, Cunnane ME, Curtin HD, Metson R. Anatomical changes of the ethmoid cavity after endoscopic sinus surgery. Laryngoscope. 2008 Dec;118(12):2240-4. DOI: 10.1097/MLG.0b013e31818379cd

269. Silverman JB, Prasittivatechakool K, Busaba NY. An evidence-based review of endoscopic frontal sinus surgery. Am J Rhinol Allergy. 2009 Nov-Dec;23(6):e59-62. DOI: 10.2500/ajra.2009.23.3406

270. Tran KN, Beule AG, Singal D, Wormald PJ. Frontal ostium restenosis after the endoscopic modified Lothrop procedure. Laryngoscope. 2007 Aug;117(8):1457-62. DOI: 10.1097/MLG.0b013e31806865be

271. Hildenbrand T, Wormald PJ, Weber RK. Endoscopic frontal sinus drainage Draf type III with mucosal transplants. Am J Rhinol Allergy. 2012 Mar-Apr;26(2):148-51. DOI: 10.2500/ajra.2012.26.3731

272. Conger BT Jr,Riley K, Woodworth BA. The Draf III mucosal grafting technique: a prospective study. Otolaryngol Head Neck Surg. 2012 Apr;146(4):664-8. DOI: 10.1177/0194599811432423

273. Albu S, Tomescu E. Small and large middle meatus antrostomies in the treatment of chronic maxillary sinusitis. Otolaryngol Head Neck Surg. 2004 Oct;131(4):542-7. DOI: 10.1016/j.otohns.2004.02.045

274. Krouse JH, Christmas DA Jr,. Powered instrumentation in functional endoscopic sinus surgery. II. A comparative study. Ear Nose Throat J. 1996 Jan;75(1):42-4.

275. Lombardi D, Tomenzoli D, Buttà L, Bizzoni A, Farina D, Sberze F, Karligkiotis A, Castelnuovo P, Nicolai P. Limitations and complications of endoscopic surgery for treatment for sinonasal inverted papilloma: a reassessment after 212 cases. Head Neck. 2011 Aug;33(8):1154-61. DOI: 10.1002/hed.21589

276. Fernandes SV. Postoperative care in functional endoscopic sinus surgery? Laryngoscope. 1999 Jun;109(6):945-8. DOI: 10.1097/00005537-199906000-00020

277. Nilssen EL, Wardrop P, El-Hakim H, White PS, Gardiner Q, Ogston S. A randomized control trial of post-operative care following endoscopic sinus surgery: debridement versus no debridement. J Laryngol Otol. 2002 Feb;116(2):108-11. DOI: 10.1258/0022215021910041

278. Ryan RM, Whittet HB, Norval C, Marks NJ. Minimal follow-up after functional endoscopic sinus surgery. Does it affect outcome? Rhinology. 1996 Mar;34(1):44-5.

279. Bugten V, Nordgård S, Steinsvåg S. Long-term effects of postoperative measures after sinus surgery. Eur Arch Otorhinolaryngol. 2008 May;265(5):531-7. DOI: 10.1007/s00405-007-0501-z

280. Bugten V, Nordgård S, Steinsvåg S. The effects of debridement after endoscopic sinus surgery. Laryngoscope. 2006 Nov;116(11):2037-43. DOI: 10.1097/01.mlg.0000241362.06072.83

281. Fishman JM, Sood S, Chaudhari M, Martinez-Devesa P, Orr L, Gupta D. Prospective, randomised controlled trial comparing intense endoscopic cleaning versus minimal intervention in the early post-operative period following functional endoscopic sinus surgery. J Laryngol Otol. 2011;28:1-5

282. Tan BK, Chandra RK. Postoperative prevention and treatment of complications after sinus surgery. Otolaryngol Clin North Am. 2010 Aug;43(4):769-79. DOI: 10.1016/j.otc.2010.04.004

283. Rudmik L, Soler ZM, Orlandi RR, Stewart MG, Bhattacharyya N, Kennedy DW, Smith TL. Early postoperative care following endoscopic sinus surgery: an evidence-based review with recommendations. Int Forum Allergy Rhinol. 2011 Nov-Dec;1(6):417-30. DOI: 10.1002/alr.20072

284. Annys E, Jorissen M. Short term effects of antibiotics (Zinnat) after endoscopic sinus surgery. Acta Otorhinolaryngol Belg. 2000;54(1):23-8.

285. Franklin JH, Wright ED. Randomized, controlled, study of absorbable nasal packing on outcomes of surgical treatment of rhinosinusitis with polyposis. Am J Rhinol. 2007 Mar-Apr;21(2):214-7. DOI: 10.2500/ajr.2007.21.3011

286. Weber R, Hochapfel F, Leuwer R, Freigang B, Draf W. Tamponaden und Platzhalter in der endonasalen Chirurgie [Tampons and place holders in endonasal surgery]. HNO. 2000 Mar;48(3):240-56; quiz 253. DOI: 10.1007/s001060050041

287. Coleman JR Jr, Duncavage JA. Extended middle meatal antrostomy: the treatment of circular flow. Laryngoscope. 1996;106:1214-7. DOI: 10.1097/00005537-199610000-00007

288. Kim E, Duncavage JA. Prevention and management of complications in maxillary sinus surgery. Otolaryngol Clin North Am. 2010 Aug;43(4):865-73. DOI: 10.1016/j.otc.2010.04.011

289. Moukarzel N, Nehmé A, Mansour S, Yammine FG, Moukheiber A. Middle turbinate medialization technique in functional endoscopic sinus surgery. J Otolaryngol. 2000 Jun;29(3):144-7.

290. Rice DH, Kern EB, Marple BF, Mabry RL, Friedman WH. The turbinates in nasal and sinus surgery: a consensus statement. Ear Nose Throat J. 2003 Feb;82(2):82-4.

291. Scheithauer MO. Nasenmuschelchirurgie und "Empty Nose" Syndrom [Surgery of the turbinates and "empty nose" syndrome]. Laryngorhinootologie. 2010 May;89 Suppl 1:S79-102. DOI: 10.1055/s-0029-1246126

292. Kennedy DW. Middle turbinate resection: evaluating the issues--should we resect normal middle turbinates? Arch Otolaryngol Head Neck Surg. 1998 Jan;124(1):107. DOI: 10.1001/archotol.124.1.107

293. Houser SM. Empty nose syndrome associated with middle turbinate resection. Otolaryngol Head Neck Surg. 2006 Dec;135(6):972-3. DOI: 10.1016/j.otohns.2005.04.017

294. Banfield GK, McCombe A. Partial resection of the middle turbinate at functional endoscopic sinus surgery. J R Army Med Corps. 1999;145:18-9. DOI: 10.1136/jramc-145-01-05

295. Fortune DS, Duncavage JA. Incidence of frontal sinusitis following partial middle turbinectomy. Ann Otol Rhinol Laryngol. 1998 Jun;107(6):447-53.

296. Giacchi RJ, Lebowitz RA, Jacobs JB. Middle turbinate resection: issues and controversies. Am J Rhinol. 2000;14:193-7. DOI: 10.2500/105065800782102726

297. Marchioni D, Alicandri-Ciufelli M, Mattioli F, Marchetti A, Jovic G, Massone F, Presutti L. Middle turbinate preservation versus middle turbinate resection in endoscopic surgical treatment of nasal polyposis. Acta Otolaryngol. 2008 Sep;128(9):1019-26. DOI: 10.1080/00016480701827541

298. Soler ZM, Hwang PH, Mace J, Smith TL. Outcomes after middle turbinate resection: revisiting a controversial topic. Laryngoscope. 2010 Apr;120(4):832-7. DOI: 10.1002/lary.20812

299. Ramadan HH, Allen GC. Complications of endoscopic sinus surgery in a residency training program. Laryngoscope. 1995;105:376-9. DOI: 10.1288/00005537-199504000-00007

300. Rice DH. Middle turbinate resection: weighing the decision. Arch Otolaryngol Head Neck Surg. 1998 Jan;124(1):106. DOI: 10.1001/archotol.124.1.106

301. Stewart MG. Middle turbinate resection. Arch Otolaryngol Head Neck Surg. 1998 Jan;124(1):104-6. DOI: 10.1001/archotol.124.1.104

302. Lee JY, Lee SW. Preventing lateral synechia formation after endoscopic sinus surgery with a silastic sheet. Arch Otolaryngol Head Neck Surg. 2007 Aug;133(8):776-9. DOI: 10.1001/archotol.133.8.776

303. Bolger WE, Kuhn FA, Kennedy DW. Middle turbinate stabilization after functional endoscopic sinus surgery: the controlled synechiae technique. Laryngoscope. 1999 Nov;109(11):1852-3. DOI: 10.1097/00005537-199911000-00025

304. Friedman M, Landsberg R, Tanyeri H. Middle turbinate medialization and preservation in endoscopic sinus surgery. Otolaryngol Head Neck Surg. 2000 Jul;123(1 Pt 1):76-80. DOI: 10.1067/mhn.2000.105921

305. Friedman M, Schalch P. Middle turbinate medialization with bovine serum albumin tissue adhesive (BioGlue). Laryngoscope. 2008 Feb;118(2):335-8. DOI: 10.1097/MLG.0b013e318158198f

306. Friedman M, Tanyeri H, Landsberg R, Caldarelli D. Effects of middle turbinate medialization on olfaction. Laryngoscope. 1999 Sep;109(9):1442-5. DOI: 10.1097/00005537-199909000-00016

307. Thornton RS. Middle turbinate stabilization technique in endoscopic sinus surgery. Arch Otolaryngol Head Neck Surg. 1996;122:869-72. DOI: 10.1001/archotol.1996.01890200059013

308. Dutton JM, Hinton MJ. Middle turbinate suture conchopexy during endoscopic sinus surgery does not impair olfaction. Am J Rhinol Allergy. 2011 Mar-Apr;25(2):125-7. DOI: 10.2500/ajra.2011.25.3560

309. Grisel JJ, Atkins JH, Fleming DJ, Kuppersmith RB. Clinical evaluation of a bioresorbable implant for medialization of the middle turbinate in sinus surgery. Int Forum Allergy Rhinol. 2011 Jan-Feb;1(1):33-7. DOI: 10.1002/alr.20001

310. Forwith KD, Chandra RK, Yun PT, Miller SK, Jampel HD. ADVANCE: a multisite trial of bioabsorbable steroid-eluting sinus implants. Laryngoscope. 2011 Nov;121(11):2473-80. DOI: 10.1002/lary.22228

311. Escada PA, Lima C, da Silva JM. The human olfactory mucosa. Eur Arch Otorhinolaryngol. 2009 Nov;266(11):1675-80. DOI: 10.1007/s00405-009-1073-x

312. Leopold DA, Hummel T, Schwob JE, Hong SC, Knecht M, Kobal G. Anterior distribution of human olfactory epithelium. Laryngoscope. 2000 Mar;110(3 Pt 1):417-21. DOI: 10.1097/00005537-200003000-00016

313. Lopes G, Jankowski R. Anosmia following superior turbinate resection. Rev Laryngol Otol Rhinol (Bord). 2004;125:189-91.

314. Biedlingmaier JF, Whelan P. Analysis for olfactory epithelium using olfactory marker protein on endoscopically harvested middle turbinates. Am J Rhinol. 1996;10:221-4. DOI: 10.2500/105065896782103144

315. Kim KS, Choi YS, Kim HJ, Yoon JH. The risk of olfactory disturbance from conchal plate injury during ethmoidectomy. Am J Rhinol. 2003 Sep-Oct;17(5):307-10.

316. Briner HR, Simmen D, Jones N. Impaired sense of smell in patients with nasal surgery. Clin Otolaryngol Allied Sci. 2003;28:417-9. DOI: 10.1046/j.1365-2273.2003.00735.x

317. Pade J, Hummel T. Olfactory function following nasal surgery. Laryngoscope. 2008 Jul;118(7):1260-4. DOI: 10.1097/MLG.0b013e318170b5cb

318. Moore EJ, Kern EB. Atrophic rhinitis: a review of 242 cases. Am J Rhinol. 2001 Nov-Dec;15(6):355-61.

319. Chhabra N, Houser SM. The diagnosis and management of empty nose syndrome. Otolaryngol Clin North Am. 2009 Apr;42(2):311-30, ix. DOI: 10.1016/j.otc.2009.02.001

320. Hildenbrand T, Weber RK, Brehmer D. Rhinitis sicca, dry nose and atrophic rhinitis: a review of the literature. Eur Arch Otorhinolaryngol. 2011 Jan;268(1):17-26. DOI: 10.1007/s00405-010-1391-z

321. Ly TH, deShazo RD, Olivier J, Stringer SP, Daley W, Stodard CM. Diagnostic criteria for atrophic rhinosinusitis. Am J Med. 2009 Aug;122(8):747-53. DOI: 10.1016/j.amjmed.2008.12.025

322. Payne SC. Empty nose syndrome: what are we really talking about?. Otolaryngol Clin North Am. 2009 Apr;42(2):331-7, ix-x. DOI: 10.1016/j.otc.2009.02.002

323. Hosemann W, Wigand ME, Fehle R, Sebastian J, Diepgen DL. Ergebnisse endonasaler Siebbein-Operationen bei diffuser hyperplastischer Sinusitis paranasalis chronica [Results of endonasal ethmoid bone operations in diffuse hyperplastic chronic paranasal sinusitis]. HNO. 1988 Feb;36(2):54-9.

324. Weber RK, Werner JA, Hildenbrand T. Endonasal endoscopic medial maxillectomy with preservation of the inferior turbinate. Am J Rhinol Allergy. 2010 Nov-Dec;24(6):132-5. DOI: 10.2500/ajra.2010.24.3531

325. Gras-Cabrerizo JR, Massegur-Solench H, Pujol-Olmo A, Montserrat-Gili JR, Ademá-Alcover JM, Zarraonandia-Andraca I. Endoscopic medial maxillectomy with preservation of inferior turbinate: how do we do it? Eur Arch Otorhinolaryngol. 2011 Mar;268(3):389-92. DOI: 10.1007/s00405-010-1347-3

326. de Almeida JR, Snyderman CH, Gardner PA, Carrau RL, Vescan AD. Nasal morbidity following endoscopic skull base surgery: a prospective cohort study. Head Neck. 2011 Apr;33(4):547-51. DOI: 10.1002/hed.21483

327. Caicedo-Granados E, Carrau R, Snyderman CH, Prevedello D, Fernandez-Miranda J, Gardner P, Kassam A. Reverse rotation flap for reconstruction of donor site after vascular pedicled nasoseptal flap in skull base surgery. Laryngoscope. 2010 Aug;120(8):1550-2. DOI: 10.1002/lary.20975

328. Robinson SR, Baird R, Le T, Wormald PJ. The incidence of complications after canine fossa puncture performed during endoscopic sinus surgery. Am J Rhinol. 2005 Mar-Apr;19(2):203-6.

329. Robinson S, Wormald PJ. Patterns of innervation of the anterior maxilla: a cadaver study with relevance to canine fossa puncture of the maxillary sinus. Laryngoscope. 2005 Oct;115(10):1785-8. DOI: 10.1097/01.mlg.0000176544.72657.a6

330. Singhal D, Douglas R, Robinson S, Wormald PJ. The incidence of complications using new landmarks and a modified technique of canine fossa puncture. Am J Rhinol. 2007;21:316-9. DOI: 10.2500/ajr.2007.21.3022

331. Jang TY, Kim YH, Shin SH. Long-term effectiveness and safety of endoscopic vidian neurectomy for the treatment of intractable rhinitis. Clin Exp Otorhinolaryngol. 2010 Dec;3(4):212-6. DOI: 10.3342/ceo.2010.3.4.212

332. Lee JC, Lin YS. Endoscopic vidian neurectomy: update on techniques and evidence. Curr Opin Otolaryngol Head Neck Surg. 2012 Feb;20(1):66-72. DOI: 10.1097/MOO.0b013e32834e13d8

333. Lin PY, Cheng CY, Wu CC, Yen MY, Wang SJ, Liao KK, Lee SM. Bilateral neurotrophic keratopathy complicating Vidian neurectomy. Am J Ophthalmol. 2001;132:106-8. DOI: 10.1016/S0002-9394(00)00958-2

334. Bhatti MT. Neuro-ophthalmic complications of endoscopic sinus surgery. Curr Opin Ophthalmol. 2007 Nov;18(6):450-8. DOI: 10.1097/ICU.0b013e3282f0b47e

335. Arya AK, Machin D, Al-Jassim H. Late periorbital haemorrhage following functional endoscopic sinus surgery: a caution for potential day case surgery. BMC Ear Nose Throat Disord. 2006;6:11. DOI: 10.1186/1472-6815-6-11

336. Ballard SR, Enzenauer RW, O'Donnell T, Fleming JC, Risk G, Waite AN. Emergency lateral canthotomy and cantholysis: a simple procedure to preserve vision from sight threatening orbital hemorrhage. J Spec Oper Med. 2009;9(3):26-32.

337. Lima V, Burt B, Leibovitch I, Prabhakaran V, Goldberg RA, Selva D. Orbital compartment syndrome: the ophthalmic surgical emergency. Surv Ophthalmol. 2009 Jul-Aug;54(4):441-9. DOI: 10.1016/j.survophthal.2009.04.005

338. McClenaghan FC, Ezra DG, Holmes SB. Mechanisms and management of vision loss following orbital and facial trauma. Curr Opin Ophthalmol. 2011 Sep;22(5):426-31. DOI: 10.1097/ICU.0b013e3283499420

339. Sharma S, Wilcsek GA, Francis IC, Lee D, Coroneo MT, Harrison H, Wolf G, Stammberger H. Management of acute surgical orbital haemorrhage: an otorhinolaryngological and ophthalmological perspective. J Laryngol Otol. 2000 Aug;114(8):621-6. DOI: 10.1258/0022215001906327

340. Graham SM, Nerad JA. Orbital complications in endoscopic sinus surgery using powered instrumentation. Laryngoscope. 2003 May;113(5):874-8. DOI: 10.1097/00005537-200305000-00018

341. Katz B, Herschler J, Brick DC. Orbital haemorrhage and prolonged blindness: a treatable posterior optic neuropathy. Br J Ophthalmol. 1983;67:549-553. DOI: 10.1136/bjo.67.8.549

342. McInnes G, Howes DW. Lateral canthotomy and cantholysis: a simple, vision-saving procedure. CJEM. 2002 Jan;4(1):49-52.

343. Radius RL, Anderson DR. Reversibility of optic nerve damage in primate eyes subjected to intraocular pressure above systolic blood pressure. Br J Ophthalmol. 1981;65:661-72. DOI: 10.1136/bjo.65.10.661

344. Hargaden M, Goldberg SH, Cunningham D, Breton ME, Griffith JW, Lang CM. Optic neuropathy following simulation of orbital hemorrhage in the nonhuman primate. Ophthal Plast Reconstr Surg. 1996;12:264-72. DOI: 10.1097/00002341-199612000-00009

345. Mason JD, Haynes RJ, Jones NS. Interpretation of the dilated pupil during endoscopic sinus surgery. J Laryngol Otol. 1998 Jul;112(7):622-7. DOI: 10.1017/S0022215100141283

346. Schabdach DG, Goldberg SH, Breton ME, Griffith JW, Lang CM, Cunningham D. An animal model of visual loss from orbital hemorrhage. Ophthal Plast Reconstr Surg. 1994;10:200-5. DOI: 10.1097/00002341-199409000-00011

347. Hayreh SS, Jonas JB. Optic disk and retinal nerve fiber layer damage after transient central retinal artery occlusion: an experimental study in rhesus monkeys. Am J Ophthalmol. 2000;129: 786-95. DOI: 10.1016/S0002-9394(00)00384-6. Erratum in: Am J Ophthalmol. 2001;131:159.

348. Young VL, Gumucio CA, Lund H, McMahon R, Ueda K, Pidgeon L. Long-term effect of retrobulbar hematomas on the vision of cynomolgus monkeys. Plast Reconstr Surg. 1992 Jan;89(1):70-6; discussion 77-8.

349. Jones KR. Complications of Endoscopic Sinus Surgery. In: Weissler MC, Pillsbury III, eds. Complications of Head and Neck Surgery. New York: Thieme; 1995. p. 90-3.

350. Thompson RF, Gluckman JL, Kulwin D, Savoury L. Orbital hemorrhage during ethmoid sinus surgery. Otolaryngol Head Neck Surg. 1990 Jan;102(1):45-50.

351. Rochels R, Rudert H. Notfalltherapie bei traumatischem Orbitahämatom mit akuter Visusminderung [Emergency therapy of traumatic orbital hematoma with acute visual impairment]. Laryngorhinootologie. 1995 May;74(5):325-7. DOI: 10.1055/s-2007-997749

352. Lee WT, Kim HK, Chung SM. Relationship between small-size medial orbital wall fracture and late enophthalmos. J Craniofac Surg. 2009 Jan;20(1):75-80. DOI: 10.1097/SCS.0b013e318190df0d

353. Dallan I, Tschabitscher M, Castelnuovo P, Bignami M, Muscatello L, Lenzi R, Battaglia P, Sellari-Franceschini S. Management of severely bleeding ethmoidal arteries. J Craniofac Surg. 2009 Mar;20(2):450-4. DOI: 10.1097/SCS.0b013e31819b9803

354. Burkat CN, Lemke BN. Retrobulbar hemorrhage: inferolateral anterior orbitotomy for emergent management. Arch Ophthalmol. 2005 Sep;123(9):1260-2. DOI: 10.1001/archopht.123.9.1260

355. Becker W, Talley AR, Logan SE, Young VL. Effect of anterior chamber paracentesis on decreased retinal circulation due to retrobulbar hematoma in dogs. Plast Reconstr Surg. 1989;83:421-8. DOI: 10.1097/00006534-198903000-00002

356. Kersten RC, Kulwin DR. Anterior chamber paracentesis. Plast Reconstr Surg. 1989 Oct;84(4):701-3.

357. Mauger TF, Nye CN, Boyle KA. Intraocular pressure, anterior chamber depth and axial length following intravenous mannitol. J Ocul Pharmacol Ther. 2000;16:591-4. DOI: 10.1089/jop.2000.16.591

358. Ilieva K, Evens PA, Tassignon MJ, Salu P. Ophthalmic complications after functional endoscopic sinus surgery (FESS). Bull Soc Belge Ophtalmol. 2008;308:9-13.

359. Hislop WS, Dutton GN. Retrobulbar haemorrhage: can blindness be prevented? Injury. 1994;25:663-5. DOI: 10.1016/0020-1383(94)90009-4

360. Han JK, Caughey RJ, Gross CW, Newman S. Management of retrobulbar hematoma. Am J Rhinol. 2008 Sep-Oct;22(5):522-4. DOI: 10.2500/ajr.2008.22.3217

361. Zoumalan CI, Bullock JD, Warwar RE, Fuller B, McCulley TJ. Evaluation of intraocular and orbital pressure in the management of orbital hemorrhage: an experimental model. Arch Ophthalmol. 2008 Sep;126(9):1257-60. DOI: 10.1001/archopht.126.9.1257

362. Lin PW, Lin HC, Chang HW, Su CY. Effects of functional endoscopic sinus surgery on intraocular pressure. Arch Otolaryngol Head Neck Surg. 2007 Sep;133(9):865-9. DOI: 10.1001/archotol.133.9.865

363. Bleier BS, Schlosser RJ. Prevention and management of medial rectus injury. Otolaryngol Clin North Am. 2010 Aug;43(4):801-7. DOI: 10.1016/j.otc.2010.04.007

364. Yung CW, Moorthy RS, Lindley D, Ringle M, Nunery WR. Efficacy of lateral canthotomy and cantholysis in orbital hemorrhage. Ophthal Plast Reconstr Surg. 1994 Jun;10(2):137-41. DOI: 10.1097/00002341-199406000-00012

365. Goodall KL, Brahma A, Bates A, Leatherbarrow B. Lateral canthotomy and inferior cantholysis: an effective method of urgent orbital decompression for sight threatening acute retrobulbar haemorrhage. Injury. 1999;30:485-90. DOI: 10.1016/S0020-1383(99)00137-0

366. Vassallo S, Hartstein M, Howard D, Stetz J. Traumatic retrobulbar hemorrhage: emergent decompression by lateral canthotomy and cantholysis. J Emerg Med. 2002;22:251-6. DOI: 10.1016/S0736-4679(01)00477-2

367. Dalley RW, Robertson WD, Rootman J. Globe tenting: a sign of increased orbital tension. AJNR Am J Neuroradiol. 1989 Jan-Feb;10(1):181-6.

368. Saussez S, Choufani G, Brutus JP, Cordonnier M, Hassid S. Lateral canthotomy: a simple and safe procedure for orbital haemorrhage secondary to endoscopic sinus surgery. Rhinology. 1998 Mar;36(1):37-9.

369. McCord CD, Boswell CB, Hester TR. Lateral canthal anchoring. Plast Reconstr Surg. 2003 Jul;112(1):222-37; discussion 238-9. DOI: 10.1097/01.PRS.0000066340.85485.DF

370. Castro E, Seeley M, Kosmorsky G, Foster JA. Orbital compartment syndrome caused by intraorbital bacitracin ointment after endoscopic sinus surgery. Am J Ophthalmol. 2000;130:376-8. DOI: 10.1016/S0002-9394(00)00557-2

371. Bachor E, Dost P, Unger A, Ruwe M. Paraffinome--eine seltene Komplikation nach endonasaler Chirurgie [Paraffinoma--a rare complication following endonasal surgery]. Laryngorhinootologie. 1999 Jun;78(6):307-12. DOI: 10.1055/s-2007-996877

372. Feldmann R, Harms M, Chavaz P, Salomon D, Saurat JH. Orbital and palpebral paraffinoma. J Am Acad Dermatol. 1992;26:833-5. DOI: 10.1016/0190-9622(92)70116-W

373. Hasegawa T, Yukawa K, Suzuki M, Komiya T, Watanabe K. A case of eyelid paraffinoma that developed after endoscopic sinus surgery. Auris Nasus Larynx. 2011 Aug;38(4):538-42. DOI: 10.1016/j.anl.2010.09.009

374. Keefe MA, Bloom DC, Keefe KS, Killian PJ. Orbital paraffinoma as a complication of endoscopic sinus surgery. Otolaryngol Head Neck Surg. 2002 Dec;127(6):575-7. DOI: 10.1067/mhn.2002.129897

375. Tasman AJ, Faller U, Möller P. Sklerosierende Lipogranulomatose der Augenlider nach Siebbeinoperation: eine Komplikation nach Salbentamponade [Sclerosing lipogranulomatosis of the eyelids after ethmoid sinus surgery: a complication after ointment tamponade!]. Laryngorhinootologie. 1994 May;73(5):264-7. DOI: 10.1055/s-2007-997126

376. Hintschich CR, Beyer-Machule CK, Stefani FH. Paraffinoma of the periorbit—a challenge for the oculoplastic surgeon. Ophthal Plast Reconstr Surg. 1995;11:39-43. DOI: 10.1097/00002341-199503000-00007

377. Rosner M, Kurtz S, Shelah M, Rosen N. Orbital lipogranuloma after sinus surgery. Eur J Ophthalmol. 2000 Apr-Jun;10(2):183-6.

378. Witschel H, Geiger K. Paraffin induced sclerosing lipogranuloma of eyelids and anterior orbit following endonasal sinus surgery. Br J Ophthalmol. 1994;78:61-65. DOI: 10.1136/bjo.78.1.61

379. Sindwani R, Cohen JT, Pilch BZ, Metson RB. Myospherulosis following sinus surgery: pathological curiosity or important clinical entity? Laryngoscope. 2003 Jul;113(7):1123-7. DOI: 10.1097/00005537-200307000-00005

380. Biedlingmaier JF, Aronsky MA, Whelan PJ. Myospherulosis of the upper eyelid as a complication of endoscopic sinus surgery. Am J Rhinol. 1997;11:345-7. DOI: 10.2500/105065897781286043

381. Alfieri A, Jho HD, Schettino R, Tschabitscher M. Endoscopic endonasal approach to the pterygopalatine fossa: anatomic study. Neurosurgery. 2003;52:374-8; discussion 378-80. DOI: 10.1227/01.NEU.0000044562.73763.00

382. Antunes Scanavini AB, Navarro JA, Megale SR, Lima RS, Anselmo-Lima WT. Morphometric evaluation of the sphenopalatine foramen for endonasal surgery. Rhinology. 2010 Dec;48(4):441-5.

383. Midilli R, Orhan M, Saylam CY, Akyildiz S, Gode S, Karci B. Anatomic variations of sphenopalatine artery and minimally invasive surgical cauterization procedure. Am J Rhinol Allergy. 2009 Nov-Dec;23(6):e38-41. DOI: 10.2500/ajra.2009.23.3403

384. Pádua FG, Voegels RL. Severe posterior epistaxis-endoscopic surgical anatomy. Laryngoscope. 2008 Jan;118(1):156-61. DOI: 10.1097/MLG.0b013e31815708d0

385. Schwartzbauer HR, Shete M, Tami TA. Endoscopic anatomy of the sphenopalatine and posterior nasal arteries: implications for the endoscopic management of epistaxis. Am J Rhinol. 2003 Jan-Feb;17(1):63-6.

386. Simmen DB, Raghavan U, Briner HR, Manestar M, Groscurth P, Jones N. The anatomy of the sphenopalatine artery for the endoscopic sinus surgeon. Am J Rhinol. 2006;20:502-5. DOI: 10.2500/ajr.2006.20.2928

387. McCarty Statham M, Tami TA. Endoscopic anatomy of the pterygopalatine fossa. Op Tech Otolaryngol. 2006;17:197-200. DOI: 10.1016/j.otot.2006.01.005

388. Snyderman CH, Carrau RL. Endoscopic ligation of the sphenopalatine artery for epistaxis. Op Tech Otolaryngol Head Neck Surg. 1997;8:85-9. DOI: 10.1016/S1043-1810(97)80007-3

389. Campbell RG. Sphenopalatine artery pseudoaneurysm after endoscopic sinus surgery: a case report and literature review. Ear Nose Throat J. 2012 Feb;91(2):E4-11.

390. Lang J. Klinische Anatomie der Nase, Nasenhöhle und Nebenhöhlen. Stuttgart: Thieme; 1988.

391. Fujii M, Goto N, Shimada K, Moriyama H, Kikuchi K, Kida A. Demonstration of the nasal septal branches of the sphenopalatine artery by use of a new intravascular injection method. Ann Otol Rhinol Laryngol. 1996 Apr;105(4):309-11.

392. Cavallo LM, Briganti F, Cappabianca P, Maiuri F, Valente V, Tortora F, Volpe A, Messina A, Elefante A, De Divitiis E. Hemorrhagic vascular complications of endoscopic transsphenoidal surgery. Minim Invasive Neurosurg. 2004 Jun;47(3):145-50. DOI: 10.1055/s-2004-818489

393. Charalampaki P, Ayyad A, Kockro RA, Perneczky A. Surgical complications after endoscopic transsphenoidal pituitary surgery. J Clin Neurosci. 2009 Jun;16(6):786-9. DOI: 10.1016/j.jocn.2008.09.002

394. Cockroft KM, Carew JF, Trost D, Fraser RA. Delayed epistaxis resulting from external carotid artery injury requiring embolization: a rare complication of transsphenoidal surgery: case report. Neurosurgery. 2000 Jul;47(1):236-9.

395. Strach K, Schröck A, Wilhelm K, Greschus S, Tschampa H, Möhlenbruch M, Naehle CP, Jakob M, Gerstner AO, Bootz F, Schild HH, Urbach H. Endovascular treatment of epistaxis: indications, management, and outcome. Cardiovasc Intervent Radiol. 2011 Dec;34(6):1190-8. DOI: 10.1007/s00270-011-0155-5

396. Pinheiro-Neto CD, Fernandez-Miranda JC, Rivera-Serrano CM, Paluzzi A, Snyderman CH, Gardner PA, Sennes LU. Endoscopic anatomy of the palatovaginal canal (palatosphenoidal canal): a landmark for dissection of the vidian nerve during endonasal transpterygoid approaches. Laryngoscope. 2012 Jan;122(1):6-12. DOI: 10.1002/lary.21808

397. Erdogmus S, Govsa F. The anatomic landmarks of ethmoidal arteries for the surgical approaches. J Craniofac Surg. 2006;17:280-5. DOI: 10.1097/00001665-200603000-00014

398. Moon HJ, Kim HU, Lee JG, Chung IH, Yoon JH. Surgical anatomy of the anterior ethmoidal canal in ethmoid roof. Laryngoscope. 2001 May;111(5):900-4. DOI: 10.1097/00005537-200105000-00027

399. Simmen D, Raghavan U, Briner HR, Manestar M, Schuknecht B, Groscurth P, Jones NS. The surgeon's view of the anterior ethmoid artery. Clin Otolaryngol. 2006 Jun;31(3):187-91. DOI: 10.1111/j.1365-2273.2006.01191.x

400. Yang YX, Lu QK, Liao JC, Dang RS. Morphological characteristics of the anterior ethmoidal artery in ethmoid roof and endoscopic localization. Skull Base. 2009 Sep;19(5):311-7. DOI: 10.1055/s-0028-1115323

401. Başak S, Karaman CZ, Akdilli A, Mutlu C, Odabaşi O, Erpek G. Evaluation of some important anatomical variations and dangerous areas of the paranasal sinuses by CT for safer endonasal surgery. Rhinology. 1998 Dec;36(4):162-7.

402. Floreani SR, Nair SB, Switajewski MC, Wormald PJ. Endoscopic anterior ethmoidal artery ligation: a cadaver study. Laryngoscope. 2006 Jul;116(7):1263-7. DOI: 10.1097/01.mlg.0000221967.67003.1d

403. Cankal F, Apaydin N, Acar HI, Elhan A, Tekdemir I, Yurdakul M, Kaya M, Esmer AF. Evaluation of the anterior and posterior ethmoidal canal by computed tomography. Clin Radiol. 2004 Nov;59(11):1034-40. DOI: 10.1016/j.crad.2004.04.016

404. Han JK, Becker SS, Bomeli SR, Gross CW. Endoscopic localization of the anterior and posterior ethmoid arteries. Ann Otol Rhinol Laryngol. 2008 Dec;117(12):931-5.

405. Gotwald TF, Menzler A, Beauchamp NJ, zur Nedden D, Zinreich SJ. Paranasal and orbital anatomy revisited: identification of the ethmoid arteries on coronal CT scans. Crit Rev Comput Tomogr. 2003;44:263-82. DOI: 10.3109/bctg.44.5.263.278

406. Pletcher SD, Metson R. Endoscopic ligation of the anterior ethmoid artery. Laryngoscope. 2007 Feb;117(2):378-81. DOI: 10.1097/01.mlg.0000250778.29957.a1

407. Oeken J, Bootz F. Schwere Komplikationen nach endonasalen Nasennebenhöhlenoperationen. Ein ungeklärtes Problem [Severe complications after endonasal nasal sinus surgery. An unresolved problem]. HNO. 2004 Jun;52(6):549-53. DOI: 10.1007/s00106-003-0861-7

408. Jeong S, Park YG, Cho J. Bilateral subperiosteal haematoma after endoscopic sinus surgery. Br J Ophthalmol. 1998;82:100. DOI: 10.1136/bjo.82.1.100

409. Bouthillier A, van Loveren HR, Keller JT. Segments of the internal carotid artery: a new classification. Neurosurgery. 1996 Mar;38(3):425-32; discussion 432-3.

410. Herzallah IR, Casiano RR. Endoscopic endonasal study of the internal carotid artery course and variations. Am J Rhinol. 2007;21:262-70. DOI: 10.2500/ajr.2007.21.3030

411. Ziyal IM, Ozgen T, Sekhar LN, Ozcan OE, Cekirge S. Proposed classification of segments of the internal carotid artery: anatomical study with angiographical interpretation. Neurol Med Chir (Tokyo). 2005;45:184-190; discussion 190-1. DOI: 10.2176/nmc.45.184

412. Kainz J, Stammberger H. Gefahrenpunkte der hinteren Rhinobasis: Anatomische, histologische und endoskopische Befunde [Danger areas of the posterior nasal base: anatomical, histological and endoscopic findings]. Laryngorhinootologie. 1991 Sep;70(9):479-86. DOI: 10.1055/s-2007-998081

413. Sandu K, Monnier P, Pasche P. Anatomical landmarks for transnasal endoscopic skull base surgery. Eur Arch Otorhinolaryngol. 2012 Jan;269(1):171-8. DOI: 10.1007/s00405-011-1698-4

414. Kainz J, Klimek L, Anderhuber W. Vermeidung vaskulärer Komplikationen bei der endonasalen Nasennebenhöhlenchirurgie. Teil I. Anatomische Grundlagen und chirurgische Bedeutung [Prevention of vascular complications in endonasal paranasal sinus surgery. I. Anatomic principles and surgical significance]. HNO. 1993 Mar;41(3):146-52.

415. Kennedy DW, Zinreich SJ, Hassab MH. The internal carotid artery as it relates to endonasal sphenoethmoidectomy. Am J Rhinol. 1990;4:7-12. DOI: 10.2500/105065890782020962

416. Zhou WG, Yang ZQ. Complications of transsphenoidal surgery for sellar region: intracranial vessel injury. Chin Med J (Engl). 2009;122:1154-6.

417. Macht S, Turowski B. Neuroradiologische Diagnostik und Interventionen bei Prozessen an der Schädelbasis [Neuroradiologic diagnostic and interventional procedures for diseases of the skull base]. HNO. 2011 Apr;59(4):340-9. DOI: 10.1007/s00106-011-2283-2

418. Park AH, Stankiewicz JA, Chow J, Azar-Kia B. A protocol for management of a catastrophic complication of functional endoscopic sinus surgery: internal carotid artery injury. Am J Rhinol. 1998;12:153-8. DOI: 10.2500/105065898781390154

419. Pepper JP, Wadhwa AK, Tsai F, Shibuya T, Wong BJ. Cavernous carotid injury during functional endoscopic sinus surgery: case presentations and guidelines for optimal management. Am J Rhinol. 2007;21:105-9. DOI: 10.2500/ajr.2007.21.2901

420. Reich O, Ringel K, Stoeter P, Maurer J. Verletzung der ACI bei Nasennebenhöhlenoperation und Management durch endovaskuläre Stentapplikation [Injury of ICA during endonasal sinus surgery and management by endovascular stent application]. Laryngorhinootologie. 2009 May;88(5):322-6. DOI: 10.1055/s-0028-1102934

421. Valentine R, Wormald PJ. Controlling the surgical field during a large endoscopic vascular injury. Laryngoscope. 2011 Mar;121(3):562-6. DOI: 10.1002/lary.21361

422. Koitschev A, Simon C, Löwenheim H, Naegele T, Ernemann U. Management and outcome after internal carotid artery laceration during surgery of the paranasal sinuses. Acta Otolaryngol. 2006 Jul;126(7):730-8. DOI: 10.1080/00016480500469578

423. Wanke I, Lautermann J, Möller-Hartmann C, Forsting M. Endovaskuläre Therapie bei Epistaxis aus der A. carotis interna: Gefässrekonstruktive und gefässverschliessende Verfahren [Endovascular treatment of epistaxis of the internal carotid artery. Vessel occlusion and vessel preservation]. HNO. 2009 Sep;57(9):953-7. DOI: 10.1007/s00106-007-1547-3

424. Biswas D, Daudia A, Jones NS, McConachie NS. Profuse epistaxis following sphenoid surgery: a ruptured carotid artery pseudoaneurysm and its management. J Laryngol Otol. 2009 Jun;123(6):692-4. DOI: 10.1017/S0022215108002752

425. Vajkoczy P. Revival of extra-intracranial bypass surgery. Curr Opin Neurol. 2009 Feb;22(1):90-5. DOI: 10.1097/WCO.0b013e32832187f1

426. Valentine R, Boase S, Jervis-Bardy J, Dones Cabral JD, Robinson S, Wormald PJ. The efficacy of hemostatic techniques in the sheep model of carotid artery injury. Int Forum Allergy Rhinol. 2011 Mar-Apr;1(2):118-22. DOI: 10.1002/alr.20033

427. Bavinzski G, Killer M, Knosp E, Ferraz-Leite H, Gruber A, Richling B. False aneurysms of the intracavernous carotid artery--report of 7 cases. Acta Neurochir (Wien). 1997;139:37-43. DOI: 10.1007/BF01850866

428. Chen D, Concus AP, Halbach VV, Cheung SW. Epistaxis originating from traumatic pseudoaneurysm of the internal carotid artery: diagnosis and endovascular therapy. Laryngoscope. 1998;108:326-31. DOI: 10.1097/00005537-199803000-00004

429. Kadyrov NA, Friedman JA, Nichols DA, Cohen-Gadol AA, Link MJ, Piepgras DG. Endovascular treatment of an internal carotid artery pseudoaneurysm following transsphenoidal surgery. Case report. J Neurosurg. 2002 Mar;96(3):624-7. DOI: 10.3171/jns.2002.96.3.0624

430. Valentine R, Wormald PJ. A vascular catastrophe during endonasal surgery: an endoscopic sheep model. Skull Base. 2011 Mar;21(2):109-14. DOI: 10.1055/s-0031-1275255

431. Karaman E, Isildak H, Haciyev Y, Kaytaz A, Enver O. Carotid-cavernous fistula after functional endoscopic sinus surgery. J Craniofac Surg. 2009 Mar;20(2):556-8. DOI: 10.1097/SCS.0b013e31819ba1e8

432. Doberentz E, Hagemeier L, Zhou H, Madea B, Lignitz E. Komplikation bei der Operation eines invertierten Papilloms – Letale intrakranielle Verletzung der A. carotis interna. Rechtsmedizin. 2011;21:549-53. DOI: 10.1007/s00194-011-0782-9

433. Mathis JM, Barr JD, Jungreis CA, Yonas H, Sekhar LN, Vincent D, Pentheny SL, Horton JA. Temporary balloon test occlusion of the internal carotid artery: experience in 500 cases. AJNR Am J Neuroradiol. 1995 Apr;16(4):749-54.

434. Dessi P, Moulin G, Castro F, Chagnaud C, Cannoni M. Protrusion of the optic nerve into the ethmoid and sphenoid sinus: prospective study of 150 CT studies. Neuroradiology. 1994 Oct;36(7):515-6. DOI: 10.1007/BF00593511

435. Maniscalco JE, Habal MB. Microanatomy of the optic canal. J Neurosurg. 1978 Mar;48(3):402-6. DOI: 10.3171/jns.1978.48.3.0402

436. Fujii K, Chambers SM, Rhoton AL Jr,. Neurovascular relationships of the sphenoid sinus. A microsurgical study. J Neurosurg. 1979 Jan;50(1):31-9. DOI: 10.3171/jns.1979.50.1.0031

437. Sharp HR, Crutchfield L, Rowe-Jones JM, Mitchell DB. Major complications and consent prior to endoscopic sinus surgery. Clin Otolaryngol Allied Sci. 2001;26:33-8. DOI: 10.1046/j.1365-2273.2001.00394.x

438. Pelausa EO, Smith K, Dempsey I. Orbital complications of functional endoscopic sinus surgery. J Otolaryngol. 1995 Jun;24(3):154-9.

439. Buus DR, Tse DT, Farris BK. Ophthalmic complications of sinus surgery. Ophthalmology. 1990 May;97(5):612-9.

440. Vásquez LM, González-Candial M. Permanent blindness after endoscopic sinus surgery. Orbit. 2011 Mar;30(2):108-10. DOI: 10.3109/01676830.2010.546554

441. Kim JY, Kim HJ, Kim CH, Lee JG, Yoon JH. Optic nerve injury secondary to endoscopic sinus surgery: an analysis of three cases. Yonsei Med J. 2005;46:300-4. DOI: 10.3349/ymj.2005.46.2.300 PMCid:PMC2823030

442. Rene C, Rose GE, Lenthall R, Moseley I. Major orbital complications of endoscopic sinus surgery. Br J Ophthalmol. 2001;85:598-603. DOI: 10.1136/bjo.85.5.598 PMCid:PMC1723944

443. Clemens A, Van Slycken S, Zeyen T, Vanden Abeele D, Van de Heyning P, Schmelzer A, Tassignon MJ. Blindness following paranasal sinus surgery: a report of two cases. Bull Soc Belge Ophtalmol. 1992;245:81-4.

444. Castellarin A, Lipskey S, Sternberg P Jr. Iatrogenic open globe eye injury following sinus surgery. Am J Ophthalmol. 2004;137:175-6. DOI: 10.1016/S0002-9394(03)00715-3

445. Haller D, Gosepath J, Mann WJ. The management of acute visual loss after sinus surgery--two cases of rhinogenic optic neuropathy. Rhinology. 2006;44:216-8.

446. Diem R, Hobom M, Maier K, Weissert R, Storch MK, Meyer R, Bähr M. Methylprednisolone increases neuronal apoptosis during autoimmune CNS inflammation by inhibition of an endogenous neuroprotective pathway. J Neurosci. 2003 Aug;23(18):6993-7000.

447. Steinsapir KD, Goldberg RA, Sinha S, Hovda DA. Methylprednisolone exacerbates axonal loss following optic nerve trauma in rats. Restor Neurol Neurosci. 2000;17(4):157-63.

448. Lee JC, Chuo PI, Hsiung MW. Ischemic optic neuropathy after endoscopic sinus surgery: a case report. Eur Arch Otorhinolaryngol. 2003 Sep;260(8):429-31. DOI: 10.1007/s00405-003-0612-0

449. Bhatti MT, Schmalfuss IM, Mancuso AA. Orbital complications of functional endoscopic sinus surgery: MR and CT findings. Clin Radiol. 2005 Aug;60(8):894-904. DOI: 10.1016/j.crad.2005.03.005

450. Lim JC, Hadfield PJ, Ghiacy S, Bleach NR. Medial orbital protrusion--a potentially hazardous anomaly during endoscopic sinus surgery. J Laryngol Otol. 1999 Aug;113(8):754-5. DOI: 10.1017/S0022215100145116

451. Carton A, Hislop S. Orbital floor injury with extraocular muscle entrapment following functional endoscopic sinus surgery. Br J Oral Maxillofac Surg. 2000 Feb;38(1):82-3. DOI: 10.1054/bjom.2000.0401

452. Leibovitch I, Wormald PJ, Crompton J, Selva D. Iatrogenic Brown's syndrome during endoscopic sinus surgery with powered instruments. Otolaryngol Head Neck Surg. 2005 Aug;133(2):300-1. DOI: 10.1016/j.otohns.2004.10.001

453. Thacker NM, Velez FG, Demer JL, Wang MB, Rosenbaum AL. Extraocular muscle damage associated with endoscopic sinus surgery: an ophthalmology perspective. Am J Rhinol. 2005 Jul-Aug;19(4):400-5.

454. Thacker NM, Velez FG, Krieger A, Stainer G, Ling R, Rosenbaum AL. Retinal hemorrhages as a complication of endoscopic sinus surgery. Arch Ophthalmol. 2004 Nov;122(11):1724-5. DOI: 10.1001/archopht.122.11.1724

455. Huang CM, Meyer DR, Patrinely JR, Soparkar CN, Dailey RA, Maus M, Rubin PA, Yeatts RP, Bersani TA, Karesh JW, Harrison AR, Shovlin JP. Medial rectus muscle injuries associated with functional endoscopic sinus surgery: characterization and management. Ophthal Plast Reconstr Surg. 2003;19:25-37. DOI: 10.1097/00002341-200301000-00004

456. Trotter WL, Kaw P, Meyer DR, Simon JW. Treatment of subtotal medial rectus myectomy complicating functional endoscopic sinus surgery. J AAPOS. 2000 Aug;4(4):250-3. DOI: 10.1067/mpa.2000.106202

457. Ela-Dalman N, Velez FG, Rosenbaum AL. Importance of sagittal orbital imaging in evaluating extraocular muscle trauma following endoscopic sinus surgery. Br J Ophthalmol. 2006 Jun;90(6):682-5. DOI: 10.1136/bjo.2005.088120

458. Thacker NM, Velez FG, Demer JL, Rosenbaum AL. Strabismic complications following endoscopic sinus surgery: diagnosis and surgical management. J AAPOS. 2004;8:488-94. DOI: 10.1016/j.jaapos.2003.09.001

459. Hong JE, Goldberg AN, Cockerham KP. Botulinum toxin A therapy for medial rectus injury during endoscopic sinus surgery. Am J Rhinol. 2008 Jan-Feb;22(1):95-7. DOI: 10.2500/ajr.2008.22.3123

460. Schmidt T, Thaller-Antlanger H, Klopfer M. Akzidentielle Verletzung des Musculus rectus internus bei endoskopischer Siebbeinzelloperation: Kasuistik mit Literaturübersicht [Accidental injury of medial rectus muscle in endoscopic surgery of ethmoidal sinus: case report and survey of literature]. Klin Monbl Augenheilkd. 2002 Jan-Feb;219(1-2):59-63. DOI: 10.1055/s-2002-23503

461. Chang YH, Yeom HY, Han SH. Anterior transposition of the inferior oblique muscle for a snapped inferior rectus muscle following functional endoscopic sinus surgery. Ophthalmic Surg Lasers Imaging. 2005 Sep-Oct;36(5):419-21.

462. Kim HJ, Kim CH, Song MS, Yoon JH. Diplopia secondary to endoscopic sinus surgery. Acta Otolaryngol. 2004;124:1237-9. DOI: 10.1080/00016480410017666

463. Jindal M, Sharma N, Parekh N. Intraoperative dilated pupil during nasal polypectomy. Eur Arch Otorhinolaryngol. 2009 Jul;266(7):1035-7. DOI: 10.1007/s00405-008-0781-y

464. Stewart D, Simpson GT, Nader ND. Postoperative anisocoria in a patient undergoing endoscopic sinus surgery. Reg Anesth Pain Med. 1999 Sep-Oct;24(5):467-9.

465. D'Souza MG, Hadzic A, Wider T. Unilateral mydriasis after nasal reconstruction surgery. Can J Anaesth. 2000 Nov;47(11):1119-21. DOI: 10.1007/BF03027966

466. Kosko JR, Pratt MF, Chames M, Letterman I. Anisocoria: a rare consequence of endoscopic sinus surgery. Otolaryngol Head Neck Surg. 1998;118:242-4. DOI: 10.1016/S0194-5998(98)80023-5

467. Prielipp RC. Unilateral mydriasis after induction of anaesthesia. Can J Anaesth. 1994 Feb;41(2):140-3. DOI: 10.1007/BF03009808

468. Karkanevatos A, Lancaster JL, Osman I, Swift AC. Pupil size and reaction during functional endoscopic sinus surgery (FESS). Clin Otolaryngol Allied Sci. 2003;28:103-7. DOI: 10.1046/j.1365-2273.2003.00673.x

469. Zaidi FH, Moseley MJ. Use of pupil size and reaction to detect orbital trauma during and after surgery. Clin Otolaryngol Allied Sci. 2004 Jun;29(3):288-9; author reply 290. DOI: 10.1111/j.1365-2273.2004.00867.x

470. Badia L, Lund VJ. Dilated pupil during endoscopic sinus surgery: what does it mean? Am J Rhinol. 2001 Jan-Feb;15(1):31-3. DOI: 10.2500/105065801781329392

471. Villari CR, Wojno TJ, Delgaudio JM. Case report of orbital violation with placement of ethmoid drug-eluting stent. Int Forum Allergy Rhinol. 2012 Jan-Feb;2(1):89-92. DOI: 10.1002/alr.20091

472. Cunnane ME, Platt M, Caruso PA, Metson R, Curtin HD. Medialization of the lamina papyracea after endoscopic ethmoidectomy: comparison of preprocedure and postprocedure computed tomographic scans. J Comput Assist Tomogr. 2009 Jan-Feb;33(1):79-81. DOI: 10.1097/RCT.0b013e31816c82da

473. Kosko JR, Hall BE, Tunkel DE. Acquired maxillary sinus hypoplasia: a consequence of endoscopic sinus surgery? Laryngoscope. 1996 Oct;106(10):1210-3. DOI: 10.1097/00005537-199610000-00006

474. Senior B, Wirtschafter A, Mai C, Becker C, Belenky W. Quantitative impact of pediatric sinus surgery on facial growth. Laryngoscope. 2000 Nov;110(11):1866-70. DOI: 10.1097/00005537-200011000-00019

475. Levine SB, Mitra S. Maxillary sinus involution after endoscopic sinus surgery in a child: a case report. Am J Rhinol. 2000;14:7-11. DOI: 10.2500/105065800781602966

476. Wu CL, Hsu MC, Liu CM. A rare complication of functional endoscopic sinus surgery: maxillary atelectasis-induced spontaneous enophthalmos. Am J Rhinol. 2004 Nov-Dec;18(6):411-4.

477. Orhan M, Saylam CY, Midilli R. Intranasal localization of the lacrimal sac. Arch Otolaryngol Head Neck Surg. 2009 Aug;135(8):764-70. DOI: 10.1001/archoto.2009.94

478. Wormald PJ, Kew J, Van Hasselt A. Intranasal anatomy of the nasolacrimal sac in endoscopic dacryocystorhinostomy. Otolaryngol Head Neck Surg. 2000 Sep;123(3):307-10. DOI: 10.1067/mhn.2000.105416

479. Soyka MB, Treumann T, Schlegel CT. The Agger Nasi cell and uncinate process, the keys to proper access to the nasolacrimal drainage system. Rhinology. 2010 Sep;48(3):364-7. DOI: 10.4193/Rhin09.136

480. Cohen NA, Antunes MB, Morgenstern KE. Prevention and management of lacrimal duct injury. Otolaryngol Clin North Am. 2010 Aug;43(4):781-8. DOI: 10.1016/j.otc.2010.04.005

481. Unlu HH, Goktan C, Aslan A, Tarhan S. Injury to the lacrimal apparatus after endoscopic sinus surgery: surgical implications from active transport dacryocystography. Otolaryngol Head Neck Surg. 2001 Mar;124(3):308-12. DOI: 10.1067/mhn.2001.112433

482. Bolger WE, Parsons DS, Mair EA, Kuhn FA. Lacrimal drainage system injury in functional endoscopic sinus surgery. Incidence, analysis, and prevention. Arch Otolaryngol Head Neck Surg. 1992 Nov;118(11):1179-84. DOI: 10.1001/archotol.1992.01880110047011

483. Eichhorn K, Harrison AR. External vs. endonasal dacryocystorhinostomy: six of one, a half dozen of the other? Curr Opin Ophthalmol. 2010 Sep;21(5):396-403. DOI: 10.1097/ICU.0b013e32833ce6ee

484. Onerci M, Orhan M, Ogretmenoğlu O, Irkeç M. Long-term results and reasons for failure of intranasal endoscopic dacryocystorhinostomy. Acta Otolaryngol. 2000;120:319-22. DOI: 10.1080/000164800750001170

485. Fayet B, Racy E, Assouline M. Complications of standardized endonasal dacryocystorhinostomy with unciformectomy. Ophthalmology. 2004 Apr;111(4):837-45. DOI: 10.1016/j.ophtha.2003.08.023

486. Leong SC, Macewen CJ, White PS. A systematic review of outcomes after dacryocystorhinostomy in adults. Am J Rhinol Allergy. 2010 Jan-Feb;24(1):81-90. DOI: 10.2500/ajra.2010.24.3393

487. Mann BS, Wormald PJ. Endoscopic assessment of the dacryocystorhinostomy ostium after endoscopic surgery. Laryngoscope. 2006 Jul;116(7):1172-4. DOI: 10.1097/01.mlg.0000218099.33523.19

488. Migliori ME. Endoscopic evaluation and management of the lacrimal sump syndrome. Ophthal Plast Reconstr Surg. 1997;13:281-4. DOI: 10.1097/00002341-199712000-00009

489. Fayet B, Racy E, Assouline M. Cerebrospinal fluid leakage after endonasal dacryocystorhinostomy. J Fr Ophtalmol. 2007;30:129-34. DOI: 10.1016/S0181-5512(07)89561-1

490. Davis DH, Laws ER Jr, McDonald TJ, Salassa JR, Phillips LH 2nd. Intraventricular tension pneumocephalus as a complication of paranasal sinus surgery: case report. Neurosurgery. 1981;8:574-6. DOI: 10.1227/00006123-198105000-00011

491. Prüss H, Klingebiel R, Endres M. Tension pneumocephalus with diplegia and deterioration of consciousness. Case Rep Neurol. 2011;3(1):48-9. DOI: 10.1159/000324824

492. Thiagarajah S, Frost EA, Singh T, Shulman K. Cardiac arrest associated with tension pneumocephalus. Anesthesiology. 1982;56:73-5. DOI: 10.1097/00000542-198201000-00021

493. Whitmore RG, Bonhomme G, Balcer LJ, Palmer JN. Tension pneumocephalus after endoscopic sinus surgery: case report of repair and management in absence of obvious skull base defect. Ear Nose Throat J. 2008 Feb;87(2):96-9.

494. Michel SJ. The Mount Fuji sign. Radiology. 2004 Aug;232(2):449-50. DOI: 10.1148/radiol.2322021556

495. Yamashita S, Tsuchimochi W, Yonekawa T, Kyoraku I, Shiomi K, Nakazato M. The Mount Fuji Sign on MRI. Inter Med. 2009;48:1567-8. DOI: 10.2169/internalmedicine.48.2511

496. Aferzon M, Aferzon J, Spektor Z. Endoscopic repair of tension pneumocephalus. Otolaryngol Head Neck Surg. 2001;124:688-9. DOI: 10.1067/mhn.2001.115764

497. Chou S, Ning M, Buonanno F. Focal intraparenchymal tension pneumocephalus. Neurology. 2006 Oct;67(8):1485. DOI: 10.1212/01.wnl.0000229141.21182.6c

498. Emmez H, Durdag E, Uslu S, Pasaoglu A, Ceviker N. Intracerebral tension pneumocephalus complicating endoscopic sinus surgery: case report. Acta Neurochir (Wien). 2009 Aug;151(8):1001-2. DOI: 10.1007/s00701-009-0347-9

499. Campanelli J, Odland R. Management of tension pneumocephalus caused by endoscopic sinus surgery. Otolaryngol Head Neck Surg. 1997 Feb;116(2):247-50. DOI: 10.1016/S0194-5998(97)70335-8

500. Nunez DA. Complications in nasal and sinus surgery. Laryngoscope. 1989 Aug;99(8 Pt 1):871. DOI: 10.1288/00005537-198908000-00018

501. Kono Y, Prevedello DM, Snyderman CH, Gardner PA, Kassam AB, Carrau RL, Byers KE. One thousand endoscopic skull base surgical procedures demystifying the infection potential: incidence and description of postoperative meningitis and brain abscesses. Infect Control Hosp Epidemiol. 2011 Jan;32(1):77-83. DOI: 10.1086/657635

502. Kraus DH, Gonen M, Mener D, Brown AE, Bilsky MH, Shah JP. A standardized regimen of antibiotics prevents infectious complications in skull base surgery. Laryngoscope. 2005 Aug;115(8):1347-57. DOI: 10.1097/01.mlg.0000172201.61487.69

503. Horowitz G, Fliss DM, Margalit N, Wasserzug O, Gil Z. Association between cerebrospinal fluid leak and meningitis after skull base surgery. Otolaryngol Head Neck Surg. 2011 Oct;145(4):689-93. DOI: 10.1177/0194599811411534

504. Orlando R, Cappabianca P, Tosone G, Esposito F, Piazza M, de Divitiis E. Retrospective analysis of a new antibiotic chemoprophylaxis regimen in 170 patients undergoing endoscopic endonasal transsphenoidal surgery. Surg Neurol. 2007 Aug;68(2):145-8; discussion 148. DOI: 10.1016/j.surneu.2006.10.063

505. Snyderman CH, Carrau RL, Kassam AB, Zanation A, Prevedello D, Gardner P, Mintz A. Endoscopic skull base surgery: principles of endonasal oncological surgery. J Surg Oncol. 2008 Jun;97(8):658-64. DOI: 10.1002/jso.21020

506. Brown SM, Anand VK, Tabaee A, Schwartz TH. Role of perioperative antibiotics in endoscopic skull base surgery. Laryngoscope. 2007 Sep;117(9):1528-32. DOI: 10.1097/MLG.0b013e3180caa177

507. Dehdashti AR, Ganna A, Karabatsou K, Gentili F. Pure endoscopic endonasal approach for pituitary adenomas: early surgical results in 200 patients and comparison with previous microsurgical series. Neurosurgery. 2008 May;62(5):1006-15; discussion 1015-7. DOI: 10.1227/01.neu.0000325862.83961.12

508. Weed HG. Antimicrobial prophylaxis in the surgical patient. Med Clin N Am. 2003;87:59-75. DOI: 10.1016/S0025-7125(02)00145-1

509. Harvey RJ, Nogueira JF, Schlosser RJ, Patel SJ, Vellutini E, Stamm AC. Closure of large skull base defects after endoscopic transnasal craniotomy. Clinical article. J Neurosurg. 2009 Aug;111(2):371-9. DOI: 10.3171/2008.8.JNS08236

510. Nicolai P, Castelnuovo P, Lombardi D, Battaglia P, Bignami M, Pianta L, Tomenzoli D. Role of endoscopic surgery in the management of selected malignant epithelial neoplasms of the naso-ethmoidal complex. Head Neck. 2007 Dec;29(12):1075-82. DOI: 10.1002/hed.20636

511. Nicolai P, Battaglia P, Bignami M, Bolzoni Villaret A, Delù G, Khrais T, Lombardi D, Castelnuovo P. Endoscopic surgery for malignant tumors of the sinonasal tract and adjacent skull base: a 10-year experience. Am J Rhinol. 2008 May-Jun;22(3):308-16. DOI: 10.2500/ajr.2008.22.3170

512. Stamm AC, Vellutini E, Harvey RJ, Nogeira JF Jr,Herman DR. Endoscopic transnasal craniotomy and the resection of craniopharyngioma. Laryngoscope. 2008 Jul;118(7):1142-8. DOI: 10.1097/MLG.0b013e318170b5dc

513. Bhattacharyya N, Gopal HV, Lee KH. Bacterial infection after endoscopic sinus surgery: a controlled prospective study. Laryngoscope. 2004 Apr;114(4):765-7. DOI: 10.1097/00005537-200404000-00032

514. van Aken MO, de Marie S, van der Lely AJ, Singh R, van den Berge JH, Poublon RM, Fokkens WJ, Lamberts SW, de Herder WW. Risk factors for meningitis after transsphenoidal surgery. Clin Infect Dis. 1997;25:852-6. DOI: 10.1086/515533

515. Casiano RR, Numa WA, Falquez AM. Endoscopic resection of esthesioneuroblastoma. Am J Rhinol. 2001 Jul-Aug;15(4):271-9.

516. Har-El G, Casiano RR. Endoscopic management of anterior skull base tumors. Otolaryngol Clin North Am. 2005 Feb;38(1):133-44, ix. DOI: 10.1016/j.otc.2004.09.007

517. Berenholz L, Kessler A, Sarfaty S, Segal S. Subarachnoid hemorrhage: a complication of endoscopic sinus surgery using powered instrumentation. Otolaryngol Head Neck Surg. 1999;121:665-7. DOI: 10.1016/S0194-5998(99)70081-1

518. Wolansky LJ, Chiang PK, Zurlo J, Baredes S, Baker SR. Encephalocoele as a complication of intranasal sinus surgery: optimal evaluation with magnetic resonance imaging. J Laryngol Otol. 1998 Aug;112(8):790-2. DOI: 10.1017/S0022215100141726

519. Reinhart DJ, Anderson JS. Fatal outcome during endoscopic sinus surgery: anesthetic manifestations. Anesth Analg. 1993 Jul;77(1):188-90. DOI: 10.1213/00000539-199307000-00037

520. Hosemann W, Wigand ME, Wessels B, Schellmann B. Medico-legale Probleme in der Nasennebenhöhlenchirurgie. Eur Arch Otorhinolaryngol Suppl. 1992;2:284-96.

521. Maniglia AJ. Fatal and major complications secondary to nasal and sinus surgery. Laryngoscope. 1989 Mar;99(3):276-83. DOI: 10.1288/00005537-198903000-00008

522. Church CA, Chiu AG, Vaughan WC. Endoscopic repair of large skull base defects after powered sinus surgery. Otolaryngol Head Neck Surg. 2003;129:204-9. DOI: 10.1016/S0194-5998(03)00521-7

523. Grunsfeld AA, Login IS. Abulia following penetrating brain injury during endoscopic sinus surgery with disruption of the anterior cingulate circuit: case report. BMC Neurol. 2006;6:4. DOI: 10.1186/1471-2377-6-4

524. Patel AM, Still TE, Vaughan W. Medicolegal issues in endoscopic sinus surgery. Otolaryngol Clin North Am. 2010 Aug;43(4):905-14. DOI: 10.1016/j.otc.2010.04.014

525. Toselli RM, dePapp A, Harbaugh RE, Saunders RL. Neurosurgical complications after intranasal ethmoidectomy. J Neurol Neurosurg Psychiatr. 1991 May;54(5):463-5.

526. Scharpf J, Dean R, Stultz T, Citardi MJ. The magnetic resonance imaging profile of occult intracranial violations as a result of sinus surgery. Am J Otolaryngol. 2005 Nov-Dec;26(6):411-4. DOI: 10.1016/j.amjoto.2005.02.021

527. Janke K, Wienke A. Verletzung der Rhinobasis als typisches Operationsrisiko. Urteil des OLG Koblenz vom 22.11.2007-5 U 465/05 [Injury of the rhinobasis as typical surgical risk. Expert decision of Koblenz OLG 22 November 2007 -5 U]. Laryngorhinootologie. 2010 Dec;89(12):756-7. DOI: 10.1055/s-0030-1247533

528. Silversides JA, Lappin E, Ferguson AJ. Staphylococcal toxic shock syndrome: mechanisms and management. Curr Infect Dis Rep. 2010 Sep;12(5):392-400. DOI: 10.1007/s11908-010-0119-y

529. Chan KH, Kraai TL, Richter GT, Wetherall S, Todd JK. Toxic shock syndrome and rhinosinusitis in children. Arch Otolaryngol Head Neck Surg. 2009 Jun;135(6):538-42. DOI: 10.1001/archoto.2009.55

530. Miller W, Stankiewicz JA. Delayed toxic shock syndrome in sinus surgery. Otolaryngol Head Neck Surg. 1994 Jul;111(1):121-3.

531. Younis RT, Lazar RH. Delayed toxic shock syndrome after functional endonasal sinus surgery. Arch Otolaryngol Head Neck Surg. 1996;122:83-5. DOI: 10.1001/archotol.1996.01890130075012

532. Paik DC, Larson JD, Johnson SA, Sahm K, Shweiki E, Fulda GJ. Phlegmonous gastritis and group A streptococcal toxic shock syndrome in a patient following functional endoscopic sinus surgery. Surg Infect (Larchmt). 2010 Dec;11(6):545-9. DOI: 10.1089/sur.2009.064

533. de Vries N, van der Baan S. Toxic shock syndrome after nasal surgery: is prevention possible? A case report and review of the literature. Rhinology. 1989 Jun;27(2):125-8.

534. Kimmelman CP. The risk to olfaction from nasal surgery. Laryngoscope. 1994 Aug;104(8 Pt 1):981-8. DOI: 10.1288/00005537-199408000-00012

535. Biedlingmaier JF. Anosmia after nasal surgery: a malpractice emergency. Otolaryngol Head Neck Surg. 1999;121:510. DOI: 10.1016/S0194-5998(99)70252-4

536. Katzenmeier C. Grundlagen und Entwicklungen des Organisationsverschuldens. Z Ärztl Fortbild Qual Gesundhwes. 2007;101:531-5.

537. Tasman AJ, Stammberger H. Video-endoscope versus endoscope for paranasal sinus surgery: influence on stereoacuity. Am J Rhinol. 1998;12:389-92. DOI: 10.2500/105065898780707946

538. Tasman AJ, Wallner F, Kolling GH. Wie gut ist die räumliche Orientierung durch die starre Optik [How good is spatial orientation with rigid endoscopic optics? Study of micromanipulation in the nasal cavity]. HNO. 1996 Feb;44(2):73-7.

539. Little RM, Deal AM, Zanation AM, McKinney K, Senior BA, Ebert CS Jr,. Occupational hazards of endoscopic surgery. Int Forum Allergy Rhinol. 2012 May-Jun;2(3):212-6. DOI: 10.1002/alr.20108

540. Sauer M, Lemmens W, Vauterin T, Jorissen M. Comparing the microdebrider and standard instruments in endoscopic sinus surgery: a double-blind randomised study. B-ENT. 2007;3(1):1-7.

541. Selivanova O, Kuehnemund M, Mann WJ, Amedee RG. Comparison of conventional instruments and mechanical debriders for surgery of patients with chronic sinusitis. Am J Rhinol. 2003 Jul-Aug;17(4):197-202.

542. Duncavage JA. Complications in endoscopic sinus surgery. Curr Opin Otolaryngol Head Neck Surg. 2004;12:1-2. DOI: 10.1097/00020840-200402000-00002

543. Hackman TG, Ferguson BJ. Powered instrumentation and tissue effects in the nose and paranasal sinuses. Curr Opin Otolaryngol Head Neck Surg. 2005;13:22-6. DOI: 10.1097/00020840-200502000-00007

544. Vauterin T, Vander Poorten V, Jorissen M. Long term effects of cutting forceps in endoscopic sinus surgery. Rhinology. 2006 Jun;44(2):123-7.

545. Vauterin T, Poorten VV, Jorissen M. Cutting forceps in functional endoscopic sinus surgery. Acta Otorhinolaryngol Belg. 2000;54(1):29-37.

546. Mus L, Hermans R, Jorissen M. Long-term effects of cutting versus non-cutting instruments in FESS. Rhinology. 2012 Mar;50(1):56-66.

547. Nelson JJ, Goyal P. Temperature variations of nasal endoscopes. Laryngoscope. 2011 Feb;121(2):273-8. DOI: 10.1002/lary.21367

548. Wurm J, Bumm K, Steinhart H, Vogele M, Schaaf HG, Nimsky C, Bale R, Zenk J, Iro H. Entwicklung eines aktiven Robotersystems für die multimodale Chirurgie der Nasennebenhöhlen [Development of an active robot system for multi-modal paranasal sinus surgery]. HNO. 2005 May;53(5):446-54. DOI: 10.1007/s00106-004-1155-4

549. Batra PS, Ryan MW, Sindwani R, Marple BF. Balloon catheter technology in rhinology: Reviewing the evidence. Laryngoscope. 2011 Jan;121(1):226-32. DOI: 10.1002/lary.21114

550. Brown CL, Bolger WE. Safety and feasibility of balloon catheter dilation of paranasal sinus ostia: a preliminary investigation. Ann Otol Rhinol Laryngol. 2006 Apr;115(4):293-9; discussion 300-1. DOI: 10.1002/lary.21114

551. Levine HL, Sertich AP 2nd,Hoisington DR, Weiss RL, Pritikin J; PatiENT Registry Study Group. Multicenter registry of balloon catheter sinusotomy outcomes for 1,036 patients. Ann Otol Rhinol Laryngol. 2008 Apr;117(4):263-70.

552. Brenner PS, Abadie WM, Weitzel EK, Thomas RF, McMains KC. Unexpected consequences of transnasal balloon dilation of the maxillary ostium. Int Forum Allergy Rhinol. 2011 Nov-Dec;1(6):466-70. DOI: 10.1002/alr.20085

553. Bolger WE, Brown CL, Church CA, Goldberg AN, Karanfilov B, Kuhn FA, Levine HL, Sillers MJ, Vaughan WC, Weiss RL. Safety and outcomes of balloon catheter sinusotomy: a multicenter 24-week analysis in 115 patients. Otolaryngol Head Neck Surg. 2007 Jul;137(1):10-20. DOI: 10.1016/j.otohns.2007.02.006

554. Andrews JN, Weitzel EK, Eller R, McMains CK. Unsuccessful frontal balloon sinuplasty for recurrent sinus barotrauma. Aviat Space Environ Med. 2010;81:514-6. DOI: 10.3357/ASEM.2716.2010

555. Heimgartner S, Eckardt J, Simmen D, Briner HR, Leunig A, Caversaccio MD. Limitations of balloon sinuplasty in frontal sinus surgery. Eur Arch Otorhinolaryngol. 2011 Oct;268(10):1463-7. DOI: 10.1007/s00405-011-1626-7

556. Alexander AA, Shonka DC Jr,Payne SC. Septal hematoma after balloon dilation of the sphenoid. Otolaryngol Head Neck Surg. 2009 Sep;141(3):424-5. DOI: 10.1016/j.otohns.2009.03.027

557. Tomazic PV, Stammberger H, Koele W, Gerstenberger C. Ethmoid roof CSF-leak following frontal sinus balloon sinuplasty. Rhinology. 2010 Jun;48(2):247-50. DOI: 10.4193/Rhin09.129

558. Justice JM, Orlandi RR. An update on attitudes and use of image-guided surgery. Int Forum Allergy Rhinol. 2012 Mar-Apr;2(2):155-9. DOI: 10.1002/alr.20107

559. Casiano RR, Numa WA Jr,. Efficacy of computed tomographic image--guided endoscopic sinus surgery in residency training programs. Laryngoscope. 2000 Aug;110(8):1277-82. DOI: 10.1097/00005537-200008000-00010

560. Kingdom TT, Orlandi RR. Image-guided surgery of the sinuses: current technology and applications. Otolaryngol Clin North Am. 2004;37:381-400. DOI: 10.1016/S0030-6665(03)00158-0

561. Prulière-Escabasse V, Coste A. Image-guided sinus surgery. Eur Ann Otorhinolaryngol Head Neck Dis. 2010 Mar;127(1):33-9. DOI: 10.1016/j.anorl.2010.02.009

562. Doshi J, Youngs R. Navigational systems in rhinology: should we all be using them? J Laryngol Otol. 2007 Sep;121(9):818-21. DOI: 10.1017/S0022215107009231

563. Thomaser EG, Tschopp K. Verbessert die CT-Navigation bei Nasennebenhöhleneingriffen das Operationsergebnis [Does CT-navigation improve the outcome of functional endonasal sinus surgery?]. Laryngorhinootologie. 2007 Aug;86(8):584-7. DOI: 10.1055/s-2007-966090

564. Tschopp KP, Thomaser EG. Outcome of functional endonasal sinus surgery with and without CT-navigation. Rhinology. 2008 Jun;46(2):116-20.

565. Fried MP, Moharir VM, Shin J, Taylor-Becker M, Morrison P. Comparison of endoscopic sinus surgery with and without image guidance. Am J Rhinol. 2002 Jul-Aug;16(4):193-7.

566. Gibbons MD, Gunn CG, Niwas S, Sillers MJ. Cost analysis of computer-aided endoscopic sinus surgery. Am J Rhinol. 2001;15: 71-5. DOI: 10.2500/105065801781543709

567. Mueller SA, Caversaccio M. Outcome of computer-assisted surgery in patients with chronic rhinosinusitis. J Laryngol Otol. 2010 May;124(5):500-4. DOI: 10.1017/S0022215109992325

568. Reardon EJ. Navigational risks associated with sinus surgery and the clinical effects of implementing a navigational system for sinus surgery. Laryngoscope. 2002 Jul;112(7 Pt 2 Suppl 99):1-19. DOI: 10.1002/lary.5541121301

569. Stelter K, Ertl-Wagner B, Luz M, Muller S, Ledderose G, Siedek V, Berghaus A, Arpe S, Leunig A. Evaluation of an image-guided navigation system in the training of functional endoscopic sinus surgeons. A prospective, randomised clinical study. Rhinology. 2011 Oct;49(4):429-37.

570. Eliashar R, Sichel JY, Gross M, Hocwald E, Dano I, Biron A, Ben-Yaacov A, Goldfarb A, Elidan J. Image guided navigation system-a new technology for complex endoscopic endonasal surgery. Postgrad Med J. 2003 Dec;79(938):686-90.

571. Schipper J, Ridder GJ, Aschendorff A, Klenzner T, Arapakis I, Maier W. Verbessert die computergestützte Navigation in der endonasalen Nasennebenhöhlenchirurgie die Prozess- und die Ergebnisqualität [Does computer-aided navigation of endonasal sinus surgery improve process quality and outcome quality?]. Laryngorhinootologie. 2004 May;83(5):298-307. DOI: 10.1055/s-2004-814362

572. Uddin FJ, Sama A, Jones NS. Three-dimensional computer-aided endoscopic sinus surgery. J Laryngol Otol. 2003 May;117(5):333-9. DOI: 10.1258/002221503321626348

573. Metson RB, Cosenza MJ, Cunningham MJ, Randolph GW. Physician experience with an optical image guidance system for sinus surgery. Laryngoscope. 2000 Jun;110(6):972-6. DOI: 10.1097/00005537-200006000-00017

574. Rassekh CH, Nauta HJ. Passive marker computer-aided sinonasal and cranial base surgery: observations from a learning curve. Ann Otol Rhinol Laryngol. 2003 Jan;112(1):45-51.

575. Dubin MG, Kuhn FA. Stereotactic computer assisted navigation: state of the art for sinus surgery, not standard of care. Otolaryngol Clin North Am. 2005 Jun;38(3):535-49. DOI: 10.1016/j.otc.2004.10.025

576. Strauss G, Koulechov K, Röttger S, Bahner J, Trantakis C, Hofer M, Korb W, Burgert O, Meixensberger J, Manzey D, Dietz A, Lüth T. Evaluation of a navigation system for ENT with surgical efficiency criteria. Laryngoscope. 2006 Apr;116(4):564-72. DOI: 10.1097/01.MLG.0000202091.34295.05

577. Citardi MJ, Batra PS. Intraoperative surgical navigation for endoscopic sinus surgery: rationale and indications. Curr Opin Otolaryngol Head Neck Surg. 2007 Feb;15(1):23-7. DOI: 10.1097/MOO.0b013e3280123130

578. Mann W, Klimek L. Indications for computer-assisted surgery in otorhinolaryngology. Comput Aided Surg. 1998;3:202-4. DOI: 10.3109/10929089809148146

579. Oeken J, Törpel J. Der Einfluss der Navigation auf die endoskopische NNH-Chirurgie [The influence of navigation on endoscopic sinus surgery]. HNO. 2008 Feb;56(2):151-7. DOI: 10.1007/s00106-007-1580-2

580. Ott I, Baier G. Komplikationen der Nasennebenhöhlen-Chirurgie. Topographische Einteilung und therapeutisches Management [Surgical complications of paranasal sinus surgery. Topographical classification and therapeutic management]. HNO. 2009 Jan;57(1):73-88; quiz 89-90. DOI: 10.1007/s00106-008-1858-z

581. Patel SN, Youssef AS, Vale FL, Padhya TA. Re-evaluation of the role of image guidance in minimally invasive pituitary surgery: benefits and outcomes. Comput Aided Surg. 2011;16(2):47-53. DOI: 10.3109/10929088.2011.552954

582. Zuckerman JD, Wise SK, Rogers GA, Senior BA, Schlosser RJ, DelGaudio JM. The utility of cadaver dissection in endoscopic sinus surgery training courses. Am J Rhinol Allergy. 2009 Mar-Apr;23(2):218-24. DOI: 10.2500/ajra.2009.23.3297

583. Manzey D, Röttger S, Bahner-Heyne JE, Schulze-Kissing D, Dietz A, Meixensberger J, Strauss G. Image-guided navigation: the surgeon's perspective on performance consequences and human factors issues. Int J Med Robot. 2009 Sep;5(3):297-308. DOI: 10.1002/rcs.261

584. Alobid I, de Pablo J, Mullol J, Centellas S, Parramon G, Carrasco J, Armario A, Bernal-Sprekelsen M. Increased cardiovascular and anxiety outcomes but not endocrine biomarkers of stress during performance of endoscopic sinus surgery: a pilot study among novice surgeons. Arch Otolaryngol Head Neck Surg. 2011 May;137(5):487-92. DOI: 10.1001/archoto.2011.60

585. Haynes AB, Weiser TG, Berry WR, Lipsitz SR, Breizat AH, Dellinger EP, Dziekan G, Herbosa T, Kibatala PL, Lapitan MC, Merry AF, Reznick RK, Taylor B, Vats A, Gawande AA; Safe Surgery Saves Lives Study Group. Changes in safety attitude and relationship to decreased postoperative morbidity and mortality following implementation of a checklist-based surgical safety intervention. BMJ Qual Saf. 2011 Jan;20(1):102-7. DOI: 10.1136/bmjqs.2009.040022

586. Haynes AB, Weiser TG, Berry WR, Lipsitz SR, Breizat AH, Dellinger EP, Herbosa T, Joseph S, Kibatala PL, Lapitan MC, Merry AF, Moorthy K, Reznick RK, Taylor B, Gawande AA; Safe Surgery Saves Lives Study Group. A surgical safety checklist to reduce morbidity and mortality in a global population. N Engl J Med. 2009 Jan;360(5):491-9. DOI: 10.1056/NEJMsa0810119

587. Lee SL. The extended surgical time-out: does it improve quality and prevent wrong-site surgery? Perm J. 2010;14(1):19-23.

588. Soler ZM, Smith TL. Endoscopic sinus surgery checklist. Laryngoscope. 2012 Jan;122(1):137-9. DOI: 10.1002/lary.22430

589. Soler ZM, Poetker DA, Rudmik L, Psaltis AJ, Clinger JD, Mace JC, Smith TL. Multi-institutional evaluation of a sinus surgery checklist. Laryngoscope. 2012 Oct;122(10):2132-6. DOI: 10.1002/lary.23437

590. Becker SS, Duncavage JA. Malpractice claims in nasal and sinus surgery: a review of 15 cases. Otolaryngol Clin North Am. 2010 Aug;43(4):929-32. DOI: 10.1016/j.otc.2010.04.019

591. Shah RK, Nussenbaum B, Kienstra M, Glenn M, Brereton J, Patel MM, Nielsen D, Roberson DW. Wrong-site sinus surgery in otolaryngology. Otolaryngol Head Neck Surg. 2010 Jul;143(1):37-41. DOI: 10.1016/j.otohns.2010.04.003

592. Simmen D, Schuknecht B. Computertomographie der Nasennebenhöhlen--eine präoperative Checkliste [Computerized tomography of paranasal sinuses--a preoperative check list]. Laryngorhinootologie. 1997 Jan;76(1):8-13. DOI: 10.1055/s-2007-997378

593. Harkness P, Brown P, Fowler S, Topham J. A national audit of sinus surgery. Results of the Royal College of Surgeons of England comparative audit of ENT surgery. Clin Otolaryngol Allied Sci. 1997 Apr;22(2):147-51. DOI: 10.1046/j.1365-2273.1997.00888.x

594. Vaid S, Vaid N, Rawat S, Ahuja AT. An imaging checklist for pre-FESS CT: framing a surgically relevant report. Clin Radiol. 2011 May;66(5):459-70. DOI: 10.1016/j.crad.2010.11.010

595. Koitschev A, Baumann I, Remy CT, Dammann F. Rationelle CT-Diagnostik vor Operationen an den Nasennebenhöhlen. HNO. 2002;50:217-22. DOI: 10.1007/s001060100540

596. Strauss G, Limpert E, Fischer M, Hofer M, Kubisch C, Krüger A, Dietz A, Meixensberger J, Trantakis C, Strauss M, Preim B. Virtuelle Echtzeit-Endoskopie der Nase und Nasennebenhöhlen. Surgical-Planning-System "Sinus Endoscopy" (SPS-SE) [Virtual endoscopy of the nose and paranasal sinuses in real-time. Surgical planning system "Sinus endoscopy" (SPS-SE)]. HNO. 2009 Aug;57(8):789-96. DOI: 10.1007/s00106-009-1977-1

597. Lopatin AS, Piskunov GZ. FESS with and without the availability of CT imaging. Am J Rhinol. 1996;10:51-4. DOI: 10.2500/105065896781795148

598. Eliashar R, Gross M, Wohlgelernter J, Sichel JY. Packing in endoscopic sinus surgery: is it really required? Otolaryngol Head Neck Surg. 2006 Feb;134(2):276-9. DOI: 10.1016/j.otohns.2005.10.012

599. Kastl KG, Betz CS, Siedek V, Leunig A. Control of bleeding following functional endoscopic sinus surgery using carboxy-methylated cellulose packing. Eur Arch Otorhinolaryngol. 2009 Aug;266(8):1239-43. DOI: 10.1007/s00405-008-0881-8

600. Tan VE, Sethi DS. Gossypiboma: an unusual intracranial complication of endoscopic sinus surgery. Laryngoscope. 2011 Apr;121(4):879-81. DOI: 10.1002/lary.21257

601. Wienke A, Mündnich A. Schmerzensgeld bei vergessener Tamponade [Compensation in forgotten tamponade]. Laryngorhinootologie. 2011 Aug;90(8):489-90. DOI: 10.1055/s-0031-1277221

602. Bajaj Y, Sethi N, Carr S, Knight LC. Endoscopic sinus surgery as day-case procedure. J Laryngol Otol. 2009 Jun;123(6):619-22. DOI: 10.1017/S0022215108003332

603. Duncavage JA. What's new in FESS: maybe office-based ESS. Curr Opin Otolaryngol Head Neck Surg. 2009;17:1. DOI: 10.1097/MOO.0b013e32831f9163

604. Fedok FG, Ferraro RE, Kingsley CP, Fornadley JA. Operative times, postanesthesia recovery times, and complications during sinonasal surgery using general anesthesia and local anesthesia with sedation. Otolaryngol Head Neck Surg. 2000 Apr;122(4):560-6.

605. Brown PM, Fowler S, Ryan R, Rivron R. ENT day surgery in England and Wales--an audit by the Royal College of Surgeons (Eng.) Comparative Audit Service. J Laryngol Otol. 1998 Feb;112(2):161-5. DOI: 10.1017/S0022215100140198

606. Lin D, Dalgorf D, Witterick IJ. Predictors of unexpected hospital admissions after outpatient endoscopic sinus surgery: retrospective review. J Otolaryngol Head Neck Surg. 2008 Jun;37(3):309-11.

607. Snissarenko EP, Church CA. Informed consent process and patient communication after complications in sinus surgery. Otolaryngol Clin North Am. 2010 Aug;43(4):915-27. DOI: 10.1016/j.otc.2010.04.015

608. Diamantopoulos II, Jones NS, Lowe J. All nasal polyps need histological examination: an audit-based appraisal of clinical practice. J Laryngol Otol. 2000 Oct;114(10):755-9. DOI: 10.1258/0022215001904086

609. Garavello W, Gaini RM. Histopathology of routine nasal polypectomy specimens: a review of 2,147 cases. Laryngoscope. 2005 Oct;115(10):1866-8. DOI: 10.1097/01.mlg.0000177075.09594.90

610. Romashko AA, Stankiewicz JA. Routine histopathology in uncomplicated sinus surgery: is it necessary? Otolaryngol Head Neck Surg. 2005 Mar;132(3):407-12; discussion 413. DOI: 10.1016/j.otohns.2004.10.002

611. van den Boer C, Brutel G, de Vries N. Is routine histopathological examination of FESS material useful? Eur Arch Otorhinolaryngol. 2010 Mar;267(3):381-4. DOI: 10.1007/s00405-009-1097-2

612. Yaman H, Alkan N, Yilmaz S, Koc S, Belada A. Is routine histopathological analysis of nasal polyposis specimens necessary? Eur Arch Otorhinolaryngol. 2011 Jul;268(7):1013-5. DOI: 10.1007/s00405-011-1534-x

613. Arslan HH, Hidir Y, Durmaz A, Karslioglu Y, Tosun F, Gerek M. Unexpected tumor incidence in surgically removed unilateral and bilateral nasal polyps. J Craniofac Surg. 2011 Mar;22(2):751-4. DOI: 10.1097/SCS.0b013e3182085598

614. Salour H, Hatami MM, Parvin M, Ferdowsi AA, Abrishami M, Bagheri A, Aletaha M, Yazdani S. Clinicopathological study of lacrimal sac specimens obtained during DCR. Orbit. 2010 Oct;29(5):250-3. DOI: 10.3109/01676830.2010.485720

615. McGarry GW, Gana P, Adamson B. The effect of microdebriders on tissue for histological diagnosis. Clin Otolaryngol Allied Sci. 1997;22:375-6. DOI: 10.1046/j.1365-2273.1997.00007.x

616. Zweig JL, Schaitkin BM, Fan CY, Barnes EL. Histopathology of tissue samples removed using the microdebrider technique: implications for endoscopic sinus surgery. Am J Rhinol. 2000;14:27-32. DOI: 10.2500/105065800781602902

617. Thaler ER, Gottschalk A, Samaranayake R, Lanza DC, Kennedy DW. Anesthesia in endoscopic sinus surgery. Am J Rhinol. 1997;11:409-13. DOI: 10.2500/105065897780914929

618. Holden JP, Vaughan WC, Brock-Utne JG. Airway complication following functional endoscopic sinus surgery. J Clin Anesth. 2002;14:154-7. DOI: 10.1016/S0952-8180(01)00376-2

619. Bachmann G, Streppel M. Hypoglossusparese nach endonasaler Nasennebenhöhlenoperation in Intubationsnarkose [Hypoglossal nerve paralysis after endonasal paranasal sinus operation in intubation narcosis]. Laryngorhinootologie. 1996 Oct;75(10):623-4. DOI: 10.1055/s-2007-997646

620. Lawes EG, Haacke NP. Complications of endoscopic sinus surgery. J R Soc Med. 1997 Oct;90(10):586.

621. Basha SI, McCoy E, Ullah R, Kinsella JB. The efficacy of pharyngeal packing during routine nasal surgery--a prospective randomised controlled study. Anaesthesia. 2006 Dec;61(12):1161-5. DOI: 10.1111/j.1365-2044.2006.04868.x

622. Burden RJ, Bliss A. Residual throat pack--a further method of prevention. Anaesthesia. 1997 Aug;52(8):806.

623. Jaiswal V, Bedford GC. Review of the use of throat packs in nasal surgery. J Laryngol Otol. 2009 Jul;123(7):701-4. DOI: 10.1017/S0022215109004356

624. Piltcher O, Lavinsky M, Lavinsky J, de Oliveira Basso PR. Effectiveness of hypopharyngeal packing during nasal and sinus surgery in the prevention of PONV. Otolaryngol Head Neck Surg. 2007 Oct;137(4):552-4. DOI: 10.1016/j.otohns.2007.04.004

625. To EW, Tsang WM, Yiu F, Chan M. A missing throat pack. Anaesthesia. 2001;56:383-4. DOI: 10.1046/j.1365-2044.2001.01976-19.x

626. Sinclair DR, Chung F, Mezei G. Can postoperative nausea and vomiting be predicted? Anesthesiology. 1999 Jul;91(1):109-18. DOI: 10.1097/00000542-199907000-00018

627. Keerl R, Weber R, Drees G, Draf W. Individuelle Lernkurven der endonasalen mikro-endoskopischen Pansinusoperation [Individual learning curves with reference to endonasal micro-endoscopic pan-sinus operation]. Laryngorhinootologie. 1996 Jun;75(6):338-43. DOI: 10.1055/s-2007-997591

628. McFerran DJ, Grant HR, Ingrams DR, Fife DG. Endoscopic sinus surgery: are junior doctors being properly trained? Ann R Coll Surg Engl. 1998 Sep;80(5):359-63.

629. Montague ML, Kishore A, McGarry GW. Audit-derived guidelines for training in endoscopic sinonasal surgery (ESS) -protecting patients during the learning curve. Clin Otolaryngol Allied Sci. 2003;28:411-6. DOI: 10.1046/j.1365-2273.2003.00734.x

630. Phillips JS, Vowler SL, Salam MA. Is training in endoscopic sinus surgery detrimental to patient outcome? J Surg Educ. 2007 Sep-Oct;64(5):278-81. DOI: 10.1016/j.jsurg.2007.07.003

631. Marks SC. Learning curve in endoscopic sinus surgery. Otolaryngol Head Neck Surg. 1999;120:215-8. DOI: 10.1016/S0194-5998(99)70409-2

632. Dawson DE, Kraus EM. Medical malpractice and rhinology. Am J Rhinol. 2007 Sep-Oct;21(5):584-90. DOI: 10.2500/ajr.2007.21.3076

633. Wolf JS, Malekzadeh S, Berry JA, O'Malley BW Jr,. Informed consent in functional endoscopic sinus surgery. Laryngoscope. 2002 May;112(5):774-8. DOI: 10.1097/00005537-200205000-00002

634. Erlenkämper A, Hollo DF. Rechtliche Rahmenbedingungen für die ärztliche Beratung und Begutachtung. Stuttgart: Thieme; 2010.

635. Taylor RJ, Chiu AG, Palmer JN, Schofield K, O'Malley BW Jr,Wolf JS. Informed consent in sinus surgery: link between demographics and patient desires. Laryngoscope. 2005 May;115(5):826-31. DOI: 10.1097/01.MLG.0000157333.40429.72

636. Wolf JS, Chiu AG, Palmer JN, O'Malley BW Jr,Schofield K, Taylor RJ. Informed consent in endoscopic sinus surgery: the patient perspective. Laryngoscope. 2005 Mar;115(3):492-4. DOI: 10.1097/01.mlg.0000157835.69121.f8

637. Lynn-Macrae AG, Lynn-Macrae RA, Emani J, Kern RC, Conley DB. Medicolegal analysis of injury during endoscopic sinus surgery. Laryngoscope. 2004 Aug;114(8):1492-5. DOI: 10.1097/00005537-200408000-00032

638. Lydiatt DD, Sewell RK. Medical malpractice and sinonasal disease. Otolaryngol Head Neck Surg. 2008 Nov;139(5):677-81. DOI: 10.1016/j.otohns.2008.06.027

639. Chan DK, Gallagher TH, Reznick R, Levinson W. How surgeons disclose medical errors to patients: a study using standardized patients. Surgery. 2005 Nov;138(5):851-8. DOI: 10.1016/j.surg.2005.04.015

640. Doms. Behandlungsfehler – Was der Arzt sagen darf. Dtsch Arztebl. 2010;107(50):2529-30.

641. Goldberg RM, Kuhn G, Andrew LB, Thomas HA Jr. Coping with medical mistakes and errors in judgment. Ann Emerg Med. 2002;39:287-92. DOI: 10.1067/mem.2002.121995

642. Lander LI, Connor JA, Shah RK, Kentala E, Healy GB, Roberson DW. Otolaryngologists' responses to errors and adverse events. Laryngoscope. 2006 Jul;116(7):1114-20. DOI: 10.1097/01.mlg.0000224493.81115.57

643. Davidson TM. Anatomy of a medical accident. West J Med. 2000;172:267-70. DOI: 10.1136/ewjm.172.4.267

644. Shah RK, Roberson DW, Healy GB. Errors and adverse events in otolaryngology. Curr Opin Otolaryngol Head Neck Surg. 2006 Jun;14(3):164-9. DOI: 10.1097/01.moo.0000193185.38310.43

645. Kiesel PR. An honest mistake, within the standard of care, will not result in a finding of liability. West J Med. 2000;172:270-1. DOI: 10.1136/ewjm.172.4.270

646. Rosenberger R. Veränderungen der medizinischen Standards und Anpassungsnotwendigkeit der rechtlichen Sorgfaltsmaßstäbe aus zivilrechtlicher Sicht. Z Ärztl Fortbild Qual Gesundhwes. 2007;101(8):537-40.

647. Caplan RA, Posner KL, Cheney FW. Effect of outcome on physician judgments of appropriateness of care. JAMA. 1991;265:1957-60. DOI: 10.1001/jama.1991.03460150061024

648. Posner KL, Caplan RA, Cheney FW. Variation in expert opinion in medical malpractice review. Anesthesiology. 1996;85:1049-54. DOI: 10.1097/00000542-199611000-00013

649. Reznick RK, MacRae H. Teaching surgical skills--changes in the wind. N Engl J Med. 2006 Dec;355(25):2664-9. DOI: 10.1056/NEJMra054785

650. Tan SS, Sarker SK. Simulation in surgery: a review. Scott Med J. 2011 May;56(2):104-9. DOI: 10.1258/smj.2011.011098

651. Keerl R. Die Bedeutung multimedialer Lernsoftware in der Ausbildung zum Nasennebenhöhlenoperateur [Value of multimedia educational software in training of the paranasal sinus surgeon]. Laryngorhinootologie. 2000 Jan;79(1):34-8. DOI: 10.1055/s-2000-8781

652. Gilbody J, Prasthofer AW, Ho K, Costa ML. The use and effectiveness of cadaveric workshops in higher surgical training: a systematic review. Ann R Coll Surg Engl. 2011 Jul;93(5):347-52. DOI: 10.1308/147870811X582954

653. Stankiewicz JA. Complications of endoscopic sinus surgery. Otolaryngol Clin North Am. 1989 Aug;22(4):749-58.

654. Hosemann W, Fanghänel J. Präparierkurs zur endoskopischen endonasalen Nasennebenhöhlenchirurgie. Tuttlingen: Verlag Endo-Press; 2004.

655. Casiano RR. Endoscopic sinonasal dissection guide. New York: Thieme; 2012.

656. Castelnuovo P. Die anatomisch-endoskopische Präparation von Nase und Nasennebenhöhlen. Tuttlingen: Endo-Press; 2006.

657. Castelnuovo P. Die endoskopisch-anatomische Präparation der Rhinobasis. Tuttlingen: Endo-Press; 2004.

658. Fortes FS, Sennes LU, Carrau RL, Brito R, Ribas GC, Yasuda A, Rodrigues AJ Jr,Snyderman CH, Kassam AB. Endoscopic anatomy of the pterygopalatine fossa and the transpterygoid approach: development of a surgical instruction model. Laryngoscope. 2008 Jan;118(1):44-9. DOI: 10.1097/MLG.0b013e318155a492

659. Jones NS. Endoskopische Chirurgie der Nasennebenhöhlen – Sezieranleitung mit praktischen klinischen Beispielen. Tuttlingen: Endo-Press; 1999.

660. Kuehnel T. Endoscopic Atlas of Paranasal Sinus Anatomy and Surgery – cadaveric demonstration. 2012. Available from: http://www.rhinologyarchive.com/Atlas.html

661. Sethi DS. Basic and advanced endoscopic sinus surgery techniques – A laboratory dissection manual. Tuttlingen: Endo-Press; 2006.

662. White PS, McGarry GW, Bingham BJG. Endoscopic dissection of the nose and paranasal sinuses. Tuttlingen: Endo-Press; 2001.

663. Bent JP, Porubsky ES. The rhinology laboratory. Laryngoscope. 1999;109:1059-63. DOI: 10.1097/00005537-199907000-00009

664. Riederer BM, Bolt, S, Brenner E, Bueno-López JL, Circulescu ARM, Davies DC, De Caro R, Gerrits PO, McHanwell S, Pais D, Paulsen F, Plaisant O, Sendemir E, Stabile I, Moxham BJ. The legal and ethical framework governing body donation in Europe – 1st update on current practice. Eur J Anat. 2012;16(1):1-21.

665. Gardiner Q, Oluwole M, Tan L, White PS. An animal model for training in endoscopic nasal and sinus surgery. J Laryngol Otol. 1996 May;110(5):425-8.

666. Acar B, Gunbey E, Babademez MA, Karabulut H, Gunbey HP, Karasen RM. Utilization and dissection for endoscopic sinus surgery training in the residency program. J Craniofac Surg. 2010 Nov;21(6):1715-8. DOI: 10.1097/SCS.0b013e3181f3c73b

667. Mladina R. Endonasal endoscopic anatomy of the lamb's head. Tuttlingen: Endo Press; 2011.

668. Mladina R, Vuković K, Štern Padovan R, Skitarelić N. An animal model for endoscopic endonasal surgery and dacryocystorhinostomy training: uses and limitations of the lamb's head. J Laryngol Otol. 2011 Jul;125(7):696-700. DOI: 10.1017/S0022215111000776

669. Arora H, Uribe J, Ralph W, Zeltsan M, Cuellar H, Gallagher A, Fried MP. Assessment of construct validity of the endoscopic sinus surgery simulator. Arch Otolaryngol Head Neck Surg. 2005 Mar;131(3):217-21. DOI: 10.1001/archotol.131.3.217

670. Ecke U, Klimek L, Müller W, Ziegler R, Mann W. Virtual reality: preparation and execution of sinus surgery. Comput Aided Surg. 1998;3:45-50. DOI: 10.3109/10929089809148128

671. Fried MP, Uribe JI, Sadoughi B. The role of virtual reality in surgical training in otorhinolaryngology. Curr Opin Otolaryngol Head Neck Surg. 2007 Jun;15(3):163-9. DOI: 10.1097/MOO.0b013e32814b0802

672. Keerl R, Schauss F, Weber R. Role de la technologie multimédia dans l'évolution de l'apprentissage de la chirurgie endonasale des sinus. Rev Laryngol Otol Rhinol (Bord). 1997;118:129-32.

673. Pößneck A, Nowatius E, Trantakis C, Cakmak H, Maass H, Kühnapfel U, Dietz A, Strauß G. A virtual training system in endoscopic sinus surgery. International Congress Series. 2005;1281:527-30. DOI: 10.1016/j.ics.2005.03.184

674. Tolsdorff B, Pommert A, Höhne KH, Petersik A, Pflesser B, Tiede U, Leuwer R. Virtual reality: a new paranasal sinus surgery simulator. Laryngoscope. 2010 Feb;120(2):420-6. DOI: 10.1002/lary.20676

675. Caversaccio M, Eichenberger A, Häusler R. Virtual simulator as a training tool for endonasal surgery. Am J Rhinol. 2003 Sep-Oct;17(5):283-90.

676. Solyar A, Cuellar H, Sadoughi B, Olson TR, Fried MP. Endoscopic Sinus Surgery Simulator as a teaching tool for anatomy education. Am J Surg. 2008 Jul;196(1):120-4. DOI: 10.1016/j.amjsurg.2007.06.026

677. Edmond CV Jr,Heskamp D, Sluis D, Stredney D, Sessanna D, Wiet G, Yagel R, Weghorst S, Oppenheimer P, Miller J, Levin M, Rosenberg L. ENT endoscopic surgical training simulator. Stud Health Technol Inform. 1997;39:518-28.

678. Radley GJ, Sama A, Watson J, Harris RA. Characterization, quantification, and replication of human sinus bone for surgery simulation phantoms. Proc Inst Mech Eng H. 2009 Oct;223(7):875-87. DOI: 10.1243/09544119JEIM577

679. Rudman DT, Stredney D, Sessanna D, Yagel R, Crawfis R, Heskamp D, Edmond CV Jr, Wiet GJ. Functional endoscopic sinus surgery training simulator. Laryngoscope. 1998;108:1643-7. DOI: 10.1097/00005537-199811000-00010

680. Bakker NH, Fokkens WJ, Grimbergen CA. Investigation of training needs for functional endoscopic sinus surgery (FESS). Rhinology. 2005 Jun;43(2):104-8.

681. Leung RM, Leung J, Vescan A, Dubrowski A, Witterick I. Construct validation of a low-fidelity endoscopic sinus surgery simulator. Am J Rhinol. 2008 Nov-Dec;22(6):642-8. DOI: 10.2500/ajr.2008.22.3245

682. Ahmidi N, Ishii M, Fichtinger G, Gallia GL, Hager GD. An objective and automated method for assessing surgical skill in endoscopic sinus surgery using eye-tracking and tool-motion data. Int Forum Allergy Rhinol. 2012 Nov;2(6):507-15. DOI: 10.1002/alr.21053

683. Fried MP, Sadoughi B, Weghorst SJ, Zeltsan M, Cuellar H, Uribe JI, Sasaki CT, Ross DA, Jacobs JB, Lebowitz RA, Satava RM. Construct validity of the endoscopic sinus surgery simulator: II. Assessment of discriminant validity and expert benchmarking. Arch Otolaryngol Head Neck Surg. 2007 Apr;133(4):350-7. DOI: 10.1001/archotol.133.4.350

684. Weghorst S, Airola C, Oppenheimer P, Edmond CV, Patience T, Heskamp D, Miller J. Validation of the Madigan ESS simulator. Stud Health Technol Inform. 1998;50:399-405.

685. Fried MP, Satava R, Weghorst S, Gallagher AG, Sasaki C, Ross D, Sinanan M, Uribe JI, Zeltsan M, Arora H, Cuellar H. Identifying and reducing errors with surgical simulation. Qual Saf Health Care. 2004 Oct;13 Suppl 1:i19-26. DOI: 10.1136/qshc.2004.009969

686. Uribe JI, Ralph WM Jr,Glaser AY, Fried MP. Learning curves, acquisition, and retention of skills trained with the endoscopic sinus surgery simulator. Am J Rhinol. 2004 Mar-Apr;18(2):87-92.

687. Edmond CV Jr,. Impact of the endoscopic sinus surgical simulator on operating room performance. Laryngoscope. 2002 Jul;112(7 Pt 1):1148-58. DOI: 10.1097/00005537-200207000-00002

688. Glaser AY, Hall CB, Uribe SJ, Fried MP. The effects of previously acquired skills on sinus surgery simulator performance. Otolaryngol Head Neck Surg. 2005 Oct;133(4):525-30. DOI: 10.1016/j.otohns.2005.06.022

689. Clifton N, Klingmann C, Khalil H. Teaching Otolaryngology skills through simulation. Eur Arch Otorhinolaryngol. 2011 Jul;268(7):949-53. DOI: 10.1007/s00405-011-1554-6

690. Briner HR, Simmen D, Jones N, Manestar D, Manestar M, Lang A, Groscurth P. Evaluation of an anatomic model of the paranasal sinuses for endonasal surgical training. Rhinology. 2007 Mar;45(1):20-3.

691. Nogueira JF, Stamm AC, Lyra M, Balieiro FO, Leão FS. Building a real endoscopic sinus and skull-base surgery simulator. Otolaryngol Head Neck Surg. 2008 Nov;139(5):727-8. DOI: 10.1016/j.otohns.2008.07.017

692. Chen G, Ling F. A new plastic model of endoscopic technique training for endonasal transsphenoidal pituitary surgery. Chin Med J (Engl). 2010;123:2576-9.

693. Malekzadeh S, Pfisterer MJ, Wilson B, Na H, Steehler MK. A novel low-cost sinus surgery task trainer. Otolaryngol Head Neck Surg. 2011 Oct;145(4):530-3. DOI: 10.1177/0194599811413373

694. Ogino-Nishimura E, Nakagawa T, Sakamoto T, Ito J. An endoscopic endonasal surgery training model using quail eggs. Laryngoscope. 2012 Oct;122(10):2154-7. DOI: 10.1002/lary.23399

695. Wais M, Ooi E, Leung RM, Vescan AD, Lee J, Witterick IJ. The effect of low-fidelity endoscopic sinus surgery simulators on surgical skill. Int Forum Allergy Rhinol. 2012 Jan-Feb;2(1):20-6. DOI: 10.1002/alr.20093

696. Stamm A, Nogueira JF, Lyra M. Feasibility of balloon dilatation in endoscopic sinus surgery simulator. Otolaryngol Head Neck Surg. 2009 Mar;140(3):320-3. DOI: 10.1016/j.otohns.2008.11.034

697. Laeeq K, Waseem R, Weatherly RA, Reh DD, Lin SY, Lane AP, Ishii M, Cummings CW, Bhatti NI. In-training assessment and predictors of competency in endoscopic sinus surgery. Laryngoscope. 2010 Dec;120(12):2540-5. DOI: 10.1002/lary.21134

698. Syme-Grant J, White PS, McAleer JP. Measuring competence in endoscopic sinus surgery. Surgeon. 2008;6: 37-44. DOI: 10.1016/S1479-666X(08)80093-5

699. Russell PT, Weaver KD. Anterior endoscopic skull-base surgery getting started: an otolaryngologist's perspective. Curr Opin Otolaryngol Head Neck Surg. 2007 Feb;15(1):1-5. DOI: 10.1097/MOO.0b013e328013f46a

700. Snyderman C, Kassam A, Carrau R, Mintz A, Gardner P, Prevedello DM. Acquisition of surgical skills for endonasal skull base surgery: a training program. Laryngoscope. 2007 Apr;117(4):699-705. DOI: 10.1097/MLG.0b013e318031c817

701. Fernandez-Miranda JC, Barges-Coll J, Prevedello DM, Engh J, Snyderman C, Carrau R, Gardner PA, Kassam AB. Animal model for endoscopic neurosurgical training: technical note. Minim Invasive Neurosurg. 2010 Oct;53(5-6):286-9. DOI: 10.1055/s-0030-1269927

702. Leach P, Abou-Zeid AH, Kearney T, Davis J, Trainer PJ, Gnanalingham KK. Endoscopic transsphenoidal pituitary surgery: evidence of an operative learning curve. Neurosurgery. 2010 Nov;67(5):1205-12. DOI: 10.1227/NEU.0b013e3181ef25c5

703. Koc K, Kenan K, Anik I, Ihsan A, Ozdamar D, Dilek O, Cabuk B, Burak C, Keskin G, Gurkan K, Ceylan S, Savas C. The learning curve in endoscopic pituitary surgery and our experience. Neurosurg Rev. 2006 Oct;29(4):298-305; discussion 305. DOI: 10.1007/s10143-006-0033-9

704. Unal B, Bademci G, Bilgili YK, Batay F, Avci E. Risky anatomic variations of sphenoid sinus for surgery. Surg Radiol Anat. 2006 May;28(2):195-201. DOI: 10.1007/s00276-005-0073-9

705. Rudmik L, Smith TL. Evaluation of the ethmoid skull-base height prior to endoscopic sinus surgery: a preoperative computed tomography evaluation technique. Int Forum Allergy Rhinol. 2012 Mar-Apr;2(2):151-4. DOI: 10.1002/alr.21006

Corresponding author:
Prof. Dr. med. W. Hosemann
Department of Otorhinolaryngology, Head and Neck Surgery, University Greifswald, Walther-Rathenau-Str. 43-45, 17475 Greifswald, Germany, Phone: +49-(0)3834-866202, Fax: +49-(0)3834-866201
hosemann@uni-greifswald.de

Please cite as
Hosemann W, Draf C. Danger points, complications and medico-legal aspects in endoscopic sinus surgery. GMS Curr Top Otorhinolaryngol Head Neck Surg. 2013;12:Doc06.
DOI: 10.3205/cto000098, URN: urn:nbn:de:0183-cto0000981

This article is freely available from
http://www.egms.de/en/journals/cto/2013-12/cto000098.shtml

Published: *2013-12-12*